

Prostatic Urethral: Embryonal Rhabdomyosarcoma

Tanveer Azam^{1,*}, Andee Dzulkarnaen Zakaria², Syed Hassan², Muhammad Shaiful Sharif¹,
Siti Nur Salmah Alias¹, Noorilyani¹, Amer Hayat Khan¹

¹Department of Clinical Pharmacy, School of Pharmaceutical Sciences Universiti Sains Malaysia, Penang, 11800, Malaysia

²Department of Surgery, School of Medical Sciences, Universiti Sains Malaysia, Health Campus, Kelantan, Malaysia

Abstract Rhabdomyosarcoma in adult is rarely develops, diagnosis is difficult and need intensive treatment with surgery, chemotherapy and radiotherapy. Feature like acute urinary retention, suprapubic pain, and hematuria might indicate any cancer development in urogenital region. A 22 years old male patient presented with hematuria and acute urinary retention was referred to the hospital with symptoms of suprapubic pain, hematuria, CBD dependent, decreased hemoglobin and hematocrit levels. Several ultrasound and biopsy was done and result showed tumor growth arising from the prostatic urethra towards the bladder. Patient was diagnosis with Embryonal Rhabdomyosarcoma at prostatic urethral region. Patient's symptoms were treated with analgesic to relieve pain, hematinic and blood transfusion for anemia.

Keywords Rhabdomyosarcoma, Embryonal Rhabdomyosarcoma, Transurethral Resection

1. Introduction

Rhabdomyosarcoma (RMS) is a cancer of connected tissues, commonly develop at structure of neck, urogenital, arms or legs, having unknown cause[1]. Embryonal Rhabdomyosarcoma is common in children and teens, 3% of childhood cancers while it rarely develops in adults, 1% of adult cancers[2]. The cells of Embryonal Rhabdomyosarcoma look like the developing muscle cells of a 6- to 8-week-old embryo.[2] Acute onset of urinary retention, pain at the tumor region and hematuria with clear urine analysis are usual symptoms of Embryonal Rhabdomyosarcoma[3].

2. Case Presentation

Twenty two years old young man was admitted in local hospital Malaysia on 12 March, 2012 with complains of acute urinary retention after having intermittent gross hematuria and dysuria for 2 days. Patient had no known history of medical illness and was an active smoker. He did not have any kind trauma or urethral discharge, urine analysis was normal. He was managed by inserting urine collecting bag (CBD) and was dependent on it; removal of urine collecting bag resulted in recurrent urinary retention.

Patient was referred to the Hospital Universiti Sains Malaysia (HUSM) on 3 April 2012, clinical investigation indicated normal blood pressure, 120/80 mmHg and pulse rate of 64/minute. Cystoscopy (CE) was performed on 5

April 2012 with a view of possible obstructing mass. Cystoscopy indicated abnormal mass at lateral wall of urethra prior to prostatic urethra on left side. Transurethral resection was performed with Cystoscopy on 7 April, 2012 that provided information that tumor mass was arising prostatic urethra encroaching towards the bladder neck with involvement of bladder lateral wall. Histopathology examination report evidenced that it is a mesenchymal Embryonal Rhabdomyosarcoma of prostate urethra.

Kidney, urethra, and bladder (KUB) X-ray with ultrasound was performed to examine any intraperitoneal / extraperitoneal perforation, fluid accumulation was observed in pelvic region and Morisson's pouch. Test was repeated again, result showed 6.8 x 5.0 x 8.1 cm heterogeneous hypoechoic lesion at distal to urinary bladder.

Transurethral Resection of Bladder tumour (TURBT) was adopted on 3 May, 2012 to remove the mass, shown in figure 1. Patient was stable after procedure. However, he complained a suprapubic pain and hematuria. Bladder irrigation was performed to prevent the clot formation and bladder washing. Hemoglobin and hematocrit value was lower than normal that was covered by blood transfusion.

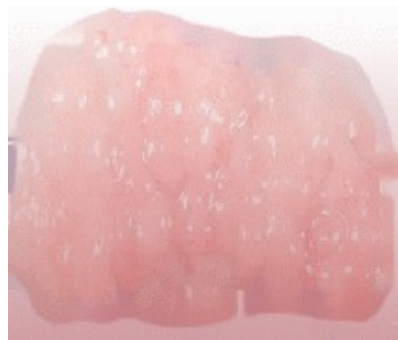

Figure 1. Removed mass

* Corresponding author:

amerhayat@ymail.com (Tanveer Azam)

Published online at <http://journal.sapub.org/cp>

Copyright © 2013 Scientific & Academic Publishing. All Rights Reserved

Tramadol 50mg was prescribed for suprapubic pain but it did not meet the goal. Therapy was replaced to combination of Paracetamol, Celecoxib and Oxycodone. Combination therapy was successful and patient was discharged.

3. Discussion

Embryonal Rhabdomyosarcoma of prostate urethra is not responsive to chemotherapy. Surgical removal is the only remedy for its cure sometime accompanied by radiotherapy and chemotherapy. In this case initially transurethral resection was performed to get biopsy sample and on confirmation the complete removal of tumor mass was done by Transurethral Resection of Bladder Tumor. Suprapubic pain might be associated with prolong urinary retention or surgical procedure. Approach of combination analgesic therapy, Paracetamol, Celecoxib and Oxycodone, is important and need follow up to avoid any complication.[4] Leonard H. Wexler et al reported that surgical removal of Embryonal Rhabdomyosarcoma of urogenital origin is curative and might do not need any medicine regimen.[5]

Prognosis of Embryonal Rhabdomyosarcoma is difficult in adults, might done by taking biopsy section and complete Histopathological examination.[6] Tumor mass of Embryonal Rhabdomyosarcoma usually consist small oval shape cells. Embryonal Rhabdomyosarcoma is more related to the age.[2] Children have a higher incidence than adult and show much higher response to its treatment protocol in contrast Rhabdomyosarcoma rarely develops in adult and requires intensive treatment with surgery, chemotherapy and radiotherapy.[7] Histopathological report confirms the type of cancer cell, its origin and stage, as shown in fig 2.

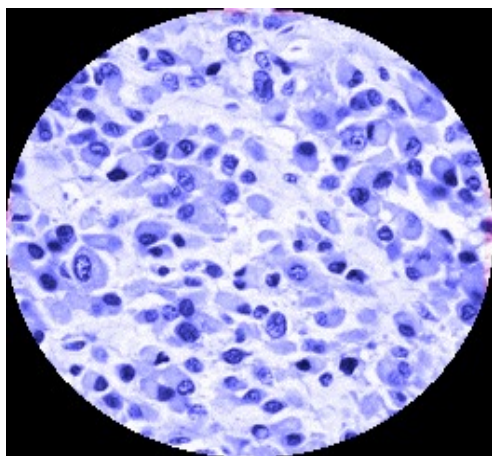


Figure 2. Rhabdomyosarcoma cells from urogenital mucosa

4. Conclusions

In children rhabdomyosarcoma might be detected in early stage with high recovery chances in contrast poor prognosis in adult might result in pre and post surgical complication like Pelvic pain and urinary disorders. This case represented the same complication in diagnosis. So far surgical removal of mass related to the site of tumor growth is the best treatment option in such patients. Supportive medicines might helps in improving the condition yet recovery is slow in adult.

REFERENCES

- [1] Keenan D. J. M. And Graham W. H. et al *Embryonal Rhabdomyosarcoma of the Prostatic-urethral Region in an Adult* British Journal of Urology. 1985; Volume 57, Issue 2, page 241-6.
- [2] Brian Kelly, Dara Lundon, Babatunde Rowaiye, Padraig Daly and Kilian Walsh et al *Embrvonal rhabdomvosarcoma of the testis* Canadian Urological Association Journal, 2011 February; 5(1): E7–E10.
- [3] Breitfeld PP, Meyer WH et al *Rhabdomyosarcoma: new windows of opportunity*, oncologist 2005 Aug; 10 (7): 518-27
- [4] Tijani Issioui, Kevin W. Klein, Paul F. White, Mehernoor F. Watcha, Margarita Coloma, Gary D. Skrivanek, Stephanie B. Jones, Kevin C. Thornton and Bradley F. Maple *The Efficacy of Premedication with Celecoxib and Acetaminophen in Preventing Pain After Otolaryngologic Surgery* Society For Ambulatory Anesthesia, Anesth Analg 2002;94:1188–93
- [5] Leonard H. Wexler et al *Rhabdomyosarcoma* The Liddy Shriver Sarcoma Initiative <http://sarcomahelp.org/rhabdomyosarcoma.html>
- [6] Niimi K, Hashimoto Y, Kurokawa S, Okada A, Tozawa K, Kohri K et al *Embryonal rhabdomyosarcoma of the prostate* International Journal of Oncology, 2010 Feb, 15(1):93-6
- [7] Joshi D. Anderson JR, Paidas C, Breneman J, Parham DM, Crist W; *Age is an independent prognostic factor in rhabdomyosarcoma: a report from the Soft Tissue Sarcoma Committee of the Children's Oncology Group*. Pediatr Blood Cancer. 2004 Jan;42(1):64-73