

Is Variant Anatomy of Atlas Clinically Important? A Review

Singh Rajani

Department of Anatomy, All India Institute of Medical Sciences, Rishikesh, 249201, India

Abstract Atlas occupies the most important and vital position interfacing skull cranially and axis caudally constituting atlanto-occipital and atlanto-axial joints. So it helps in complex biomechanical movements of skull and neck along with weight transmission of skull to spine. Besides this it paves the way for spinomedullary junction through vertebral foramen, vertebral artery and first cervical nerve over superior surface of posterior arch making it more vulnerable. Above mentioned reasons may make atlas most favorable for anatomical variations of all the vertebrae. Thus any of these anatomical variations of atlas causing pathology thereby clinical complication will be of paramount importance for health scientist and medical professionals. It is therefore necessary to make the health caring scientists and doctors to update the knowledge of the morphological variants consisting of occipitalization, cleft, hypoplasia and aplasia of anterior and posterior arches, bridging of vertebral groove and foramen transversarium of atlas. These morphological variations in atlas vertebra are related to bundle of clinical complications. This systematic review analyses available information on the clinical anatomy of the atlas vertebra. A literature search using electronic databases and standard anatomy references text books was conducted. The search was restricted to English language only. The study will be of paramount importance to Anatomists, clinicians and radiologists for updating their knowledge of current developments in this field.

Keywords Atlas, First cervical vertebra, Atlanto-occipital joint, Axis, Atlanto-axial joint

1. Introduction

Atlas vertebra was named after Atlas, the great titan of Greek mythology, who was supposed to hold the globe of universe on his head as first cervical vertebra supports the globe of the head. Atlas is the most superior cervical vertebra of the spine. Atlas vertebra (Fig.1) is ring like structure, consisting of anterior and posterior arches including two lateral masses along with transverse processes. Two lateral masses bear a kidney shaped superior articular facets which articulate with occipital condyles to form atlanto-occipital joint. Inferior articular facets of these lateral masses are almost circular and flat. It is oriented more obliquely to the transverse plane than the superior articular facet and faces more medially. Inferior articular facets of atlas form lateral atlanto-axial plane joint. On medial surface of each lateral mass is a rough area which bears vascular foramina and a tubercle for the attachment of transverse ligaments[1]. In adults the distance between these tubercles is shorter than length of the transverse ligament with a mean of 16 mm.

The anterior arch which forms anterior 2/5 of ring is slightly convex anteriorly and bears anterior tubercle. The

anterior longitudinal ligament and longus colli muscles are attached to anterior tubercle. Its upper border provides attachment to the anterior atlanto-occipital membrane which often gets ossified. The posterior surface of the anterior arch bears concave circular facet for dens[1].

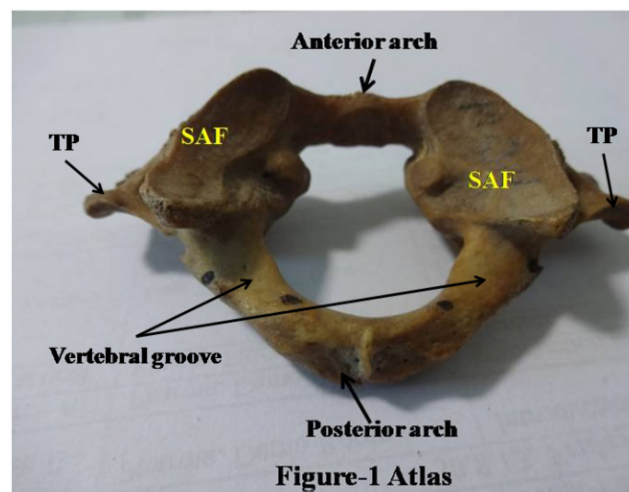


Figure 1. Atlas, SAF stands for superior articular facet TP for Transverse process

The posterior arch forms 3/5 of the circumference of the atlantal ring. The superior surface of posterior arch bears a wide groove (Fig.1) for the vertebral artery. This groove varies in size and depth ranging from mere an impression to a

clear groove or sulcus. Posterior arch allows first cervical nerve to pass over it and vertebral artery in vertebral groove. It has posterior tubercle which is the rudiment of a spinous process and gives origin to the Recti capitis posteriores minores and the ligamentum nuchae[1].

Transverse processes act as strong levers for the muscles which make fine adjustments to keep the head balanced. The maximum atlantal width varies in the range 74-95 mm in males and 65-76 mm in females and this affords a useful criterion for assessing sex in human remains. The apex of transverse process is usually broad and palpable between the mastoid process and the ramus of mandible. It bears foramen transversarium typical of cervical vertebra. It transmits vertebral artery, vein and sympathetic plexus. Foramen transversarium is bounded by pedicles posteriorly and laterally it is bounded by two roots of transverse process[1].

The atlas vertebra of cervical spine forms the atlanto-occipital joint cranially connecting the skull with spine and caudally it articulates with axis forming atlanto-axial joint. As it is sandwiched between the two joints so it facilitates the biomechanical movements of neck through these joints. These bony joints provide wide range of flexion, extension, lateral movements and rotation of the neck. The chief peculiarity of atlas is that it has no body. Body of atlas vertebra is thought to be separated from atlas and incorporated in the axis, the second cervical vertebra as dens or odontoid process. The dens acts as a pivot that allows the atlas to rotate on the axis side to side. The atlas and axis vertebrae are specialized to allow a greater range of biomechanical movements than normal vertebra.

Atlas transmits weight of head to vertebral column. If the head is obliquely held consistently due to any reason, the anatomy of atlas is likely to be altered. This may influence functionality of atlanto-occipital joints in rotational kinematics of biomechanical skull movements. This alters anatomy of atlas also generates pathologies which may create further clinical implications. Above mentioned multitude of functions pertaining to atlas vertebra creates bundles of pathologies, is the background of the study.

Thus the knowledge of both normal and variant anatomy of atlas is most useful in diagnosis and treatment of pathologies associated with atlas. The anatomical variations of atlas such as assimilation of atlas causing neurological symptoms/sometimes no symptoms causing atlanto-axial instability including torticollis, congenital cleft of anterior arch, partial aplasia or hypoplasia of posterior arch, unilateral and bilateral cleft of posterior arch, presence of arcuate foramen and double foramen transversarium are multitude of pathologies creating complex clinical problems to human beings.

Therefore the aim of study is to update most current developments and researches conducted not only to anatomists for new variants of atlas and its genesis to enrich anatomy of this vertebra but also to clinicians, surgeons and radiologists for various associated pathologies and their clinical implications.

2. Material and Methods

Literature search was conducted using the following databases as appended below:

Scielo, Scopus, medline, PubMed and Wiley online library. Papers containing original data were selected and secondary references retrieved from bibliographies. The search was restricted to English language articles and selected anatomy reference text books.

Search terms used for surfing the literature were-

1. Atlas- the first cervical vertebra
2. Morphometry of atlas
3. Occipitalisation or assimilation of atlas vertebra
4. Bridging of vertebral groove
5. Morphometry of vertebral groove
6. Anatomy of atlas vertebra
7. Atlanto-occipital joint
8. Variant anatomy of atlas vertebra
9. Variant anatomy of anterior arch of atlas vertebra
10. Variant anatomy of posterior arch of atlas vertebra

3. Results

The following account of atlas vertebra is based on the analysis of the retrieved literature under headings- description of anomalies of atlas vertebra, etiology and clinical significance related to these anomalies.

3.1. Anomalies Associated with Atlas Vertebra

Occipitalization of atlas is congenital bony fusion of the atlas vertebra with the base of the occipital bone of the skull. This involves superior articular facets, anterior and posterior arches or complete atlas vertebra[2]. The incidence of atlanto-occipital fusion (**assimilation** or **occipitalization**) ranges from 0.14% to 0.75% of the population, both sexes being equally affected[3,4,5].

Partial fusion is more common. Occipitalization was first described by Rokitsky in 1844. This was later demonstrated roentgenographically by Schüller in 1911. The authors[6, 7, 3, 8, 9, 10, 11, 5] also reported this bony abnormality involving neurovascular complications due to occipitalization. The assimilation of atlas vertebra creates difficulty in mobility of skull with respect to spine. But absolute immobility of an occipitalized atlanto-occipital joint results in compensatory hypermobility between the atlas and axis. This hypermobility in atlanto-axial junction may create abnormalities in atlas and axis vertebrae at their interface due to over use of this junction. Approximately 50% of patients with atlanto-occipital fusion develop atlanto-axial instability[12] and concurrent subluxation[13]. Vertebral artery anomalies with atlanto-occipital fusion were observed by Bernini et al. (1969)[14].

3.2. Anomalies of Anterior and Posterior Arches of Atlas Vertebra

Congenital anomalies in arches of the atlas are rare and usually discovered incidentally. Anomalies of anterior and posterior arches include cleft (Fig-2A, 2B), partial aplasia (Fig.3A) and complete agenesis (Fig.3B).

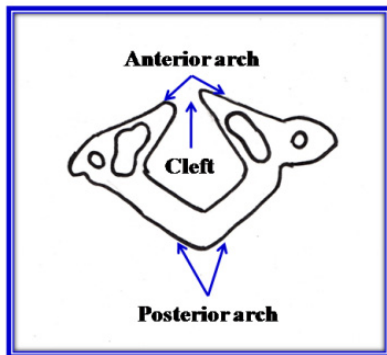


Figure 2A. Cleft in anterior arch of atlas

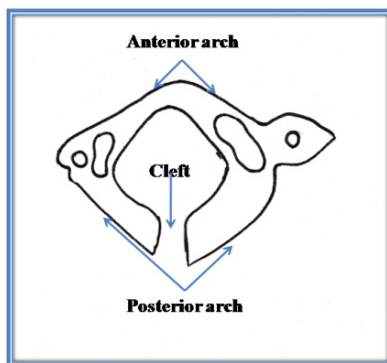


Figure 2B. Cleft in Posterior arch

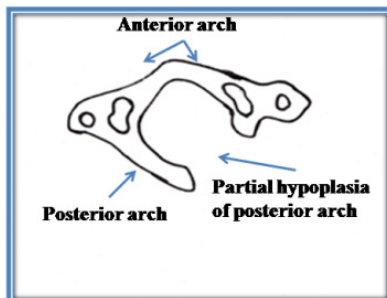


Figure 3A. Partial hypoplasia of Posterior arch

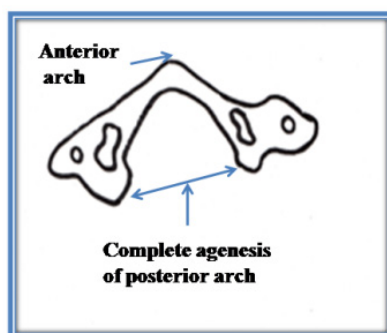


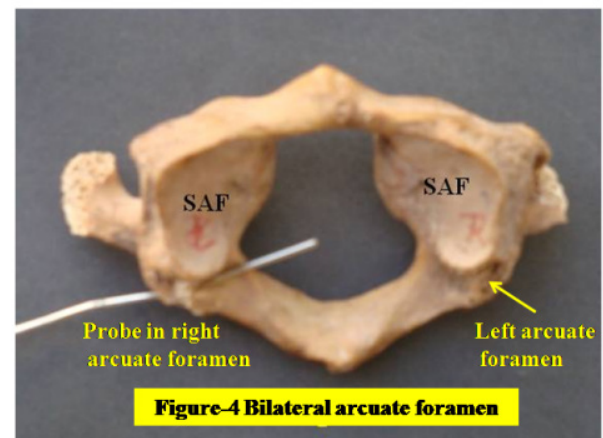
Figure 3B. Complete agenesis of Posterior arch

Choi et al.,[15] described a case of bilateral partial aplasia

of the lateral aspect of the posterior arch and a midline congenital cleft within the anterior arch of the atlas vertebra through radiographs. Klimo et al[16] described a case of congenital partial aplasia of the posterior arch of the atlas. Seven cases of congenital defects of the posterior arch of the atlas were described by Currarino et al.[17] like absence of the posterior arch of the atlas (four patients), bilateral clefts (two patients), and unilateral cleft (one patient). The incidence of posterior arch anomalies of the atlas is between 0.69% and 2.95%. Sabuncuoglu et al[18] described a case of congenital hypoplasia of the posterior arch of the atlas.

3.3. Anomalies of Vertebral Groove

The Vertebral groove has been seen bridged by ossification named as ponticulus posticus which extends from the lateral mass to posterior arch of atlas. The existence of the ponticulus posticus has been demonstrated in a study in which lateral cephalometric x-ray films have been examined in 1963. This foramen thus formed has been classified as complete or incomplete foramen depending upon the complete or partial ossification. The complete foramen (Fig.4) is called “Kimmerle anomaly”.



SAF stands for Superior articular facet

Figure 4. Bilateral Arcuate Foramen

Kimmerle 1930[19], has named the foramen after his name. This foramen has also been named as retroarticular canal, arcuate foramen, foramen atlantoideum posterius, canalis arterial vertebralis etc by various authors.

Superoinferior diameter (SI) of Kimmerle's anomaly on right side was 5 mm and anterosuperior (AP) diameter on same side was 9 mm. Superoinferior measurement on left side was 6.5 mm while anteroposterior distance was 8 mm. Thickness of ponticulus posticus on right side was 4 mm and on left side it was 4.5 mm. The distance of foramen from midline was 20.0 mm[20]. Mitchell (1998)[21] in her study of atlas vertebra of African whites and black adults reported that SI diameter of complete arcuate foramen ranged between 5.9-6.7 mm. Pyo and Lowman (1959)[22] reported that mean diameter of complete arcuate foramen was 8.3 mm in American white males. Mean SI and AP diameter are 5.7 mm (range- 3.7-8.5 mm) and 8.1 mm (range 5.7-10.0 mm)

respectively[23]. The mean ponticle thickness was 2.2 mm (range 1.0-3.5mm). Incidence of this trait was 10-14%. Incidence of ossification was found in 12% of both American whites and American blacks[24]. Taitz and Nathan[25] found 25.9% with partial bridging and 7.9% with complete ring. Asvat[24] in a study of black and white south Africans showed the incidence of 13.5% of which 44.4% was bilateral and 55.5% was unilateral.

According to Saunders and Poppvich[26], its incidence was 29.2%. Mitchell[21] in her study demonstrated 6% incidence in South Africans. The posterior bridging demonstrated radiologically and incidence was 8.1%[27]. Its incidence in south Indians was 11.7%[28]. This showed that the incidence varied with ethnic group.

3.4. Foramen Transversarium

The costal elements sometimes remain deficient leaving the foramen transversarium open anteriorly. Double foramen transversarium has also been reported[29, 30]. According to them one foramen transmitted vertebral artery and second vein. Foramen transversarium was also described to be divided by a fibrous or bony bridge separating the artery and vein. An accessory foramen transversarium on the posterior arch of atlas vertebra was reported altering the course of vertebral artery and even led to its compression[31].

4. Etiology of Variant Anomalies of Atlas

4.1. Occipitalization

Barge demonstrated that the atlanto-occipital joint was intersegmental and not segmental[8]. Tachdjian (1990)[32] mentioned that the dense caudal part of the fourth occipital somite apparently united with the cephalic part of the subjacent somite resulting in atlanto-occipital fusion. According to Chandraraj and Briggs (1992)[33], occipitalization was due to an interruption in the differentiation of the occipito-cervical somites early in the embryonic period. The caudal portion of the first cervical sclerotome mainly gave rise to the neural arch (posterior arch) of the atlas and the hypochordal bow becomes the anterior arch.

4.2. Anterior and Posterior Arches

Congenital hypoplasia of the posterior arch of the atlas vertebra, a developmental failure of chondrogenesis was a rare anomaly and may range from partial clefts to total agenesis of the posterior arch. Ossification of the posterior arch usually occurred between the 3rd and 5th years of life. Pax9 was expressed in cells fated to form posterior arch (neural arch) which was responsible for proliferation of cells in this region. Further, an increased apoptosis was observed in Pax1/ Pax9 deficient mice[34]. Partial hypoplasia/ complete agenesis might be either due to decreased cell proliferation or increased cell death as Pax1/Pax9 genes are

required to maintain high rate of cell proliferation during sclerotome development. Thus there might be under expression/complete deletion of Pax9 gene in this region.

Similarly various defects of anterior arch might be caused by deletion/mutation of Pax1 in varying degree.

4.3. Causes of Formation of Arcuate Foramen

Mechanism of formation of this bony ring is not clearly understood but a number of theories have been proposed like ossification of connective tissue surrounding the vertebral artery, late ossification of lower edge of atlanto-occipital membrane. According to some authors, the trait is familial rather than age related[35, 27].

5. Clinical Significance

(1) Occipitalization of the atlas is commonly associated with concomitant neurovascular and skeletal anomalies at the craniovertebral junction. Occipitalization of the atlas is an important congenital malformation of the craniovertebral region because of its proximity to the spinomedullary region with the possibility of a neurological compression syndrome.

Occipitalization of the atlas can produce a wide range of neurological signs and symptoms which vary from transitory headache to a full blown neurological syndrome.

Cervical cord compression is due to the soft tissue and bony abnormalities associated with occipitalization of the atlas. This leads to weakness, ataxia of the lower extremities and nystagmus. Numbness and pain in the upper extremities is a prominent complaint[2]. Objective findings chiefly comprise hyperreflexia, positive Babinski and Hoffmann reflexes, weakness and other long-tract signs in both the upper and lower extremities. Sensory findings are less frequent. Occipitalization may result in vertebral artery compression or even total occlusion leading to dizziness, seizure etc. The assimilation of the atlas with the occipital bone is generally associated with bony torticollis[7, 36, 32] due to constraints of mobility.

For diagnosis of assimilation/occipitalization of atlas, some degree of bony union between the skull and the atlas is necessary to be demonstrated[8]. Probable criteria for differentiating occipitalization of the atlas from manifestations of an occipital vertebra (third occipital condyles, a paracondylar process, a transverse basioccipital fissure, basilar process and bipartite atlantal facets) is based on the position of the hypoglossal, suboccipital nerves and the vertebral artery (2).

(2) Cleft, hypoplasia and aplasia of anterior and posterior arches may be mistaken for fractures. Therefore when upper cervical anomalies are found in a young patient, the patient should be evaluated in detail with advanced radiological studies to avoid misinterpretation of cleft, hypoplasia and aplasia for fractures, subluxation, osteolysis or instability. Klimo et al[16] described a case of congenital partial aplasia of the posterior arch of the atlas causing myelopathy. Patient came with complaint of Lhermitte sign, only with extension

of his neck and an episode of temporary quadriplegia with a minor fall. Currarino et al.[17] described seven cases having defects of posterior arch. In three patients the anomaly was discovered as an incidental asymptomatic finding; three other patients presented with transient neck pain or transient neurologic symptoms after head and neck trauma and one patient (an adult woman) described neck symptoms of 1-year duration. Garg et al[37] described a case of bipartite atlas with os odontoideum in patient with weakness and numbness of all four limbs after sustaining a minor head trauma. Radiographs of cervical spine revealed aplasia of anterior arch of atlas, ventral displacement of C1 over C2 on flexion which reduced on extension. CT scan showed anterior arch aplasia, posterior arch midline defect, and os odontoideum which had a small projection on the anterior surface at the level of anterior arch. The clinical symptoms due to variant defects of posterior arch of atlas are caused due to involvement of first cervical nerve and part of cervical spinal cord passing through vertebral foramen of atlas vertebra. The complaints of tremor, hyperesthesia of lower limbs followed by quadriplegia after experiencing minor head trauma were observed by Choi et al.,[15] in patients with congenital cleft of anterior arch and partial aplasia of the posterior arch of the atlas vertebra.

5.1. Arcuate Foramen

The vertebral artery is vulnerable to compression during external rotation of head and neck as in the manipulation of cervical spine. This situation may be aggravated by presence of posterior or lateral bridge of the atlas and result in compromised blood flow.

Some spine surgeons reported that during lateral mass screw fixation/ insertion severe complications like vertebral artery injury occurred. The possible cause may be presence of posticus ponticle or arcuate foramen. Therefore proper identification of this anomaly on preoperative lateral radiographs should alert surgeons to avoid using ponticulus posticus as a starting point for lateral mass screw fixation. As it vary in size and shape, 3D CT scanning should be considered before planning lateral mass screw placement into the posterior arch[38]. Some patients with this anomaly have complained neck pain, headache, dizziness etc. If patient comes with above symptoms, presence of ponticulus posticus should also be kept in mind.

Vertebral artery may be injured during posterior approaches to the cranio-vertebral junction especially during lateral dissection and decompressive C-1 laminectomy. The arches of C-1 and C-2 are widely exposed during some procedures and injury to the vertebral artery as it passes above the C-1 arch through the suboccipital triangle should be avoided. Various suggestions have been made as to how far exposure should be made laterally during dissection to avoid vertebral artery injury. Exposure of the posterior arch of the atlas is an important step in surgical procedures for treatment of diverse conditions of the upper spinal cord and foramen region. According to Tulika[39] a minimum of 1.5

cm of the posterior arch could be safely exposed at both outer and inner cortices. In addition with mobilization of the vertebral artery from its groove on both the sides, an additional 1 cm of posterior arch could be exposed on either side.

Stauffer[40] has recommended that the soft tissue attachment on the posterior ring of the atlas be separated approximately 1 cm from the midline bilaterally to prevent vertebral artery injury during a deeper dissection. Various authors have quoted the safe zone for surgical manipulations on the posterior arch of the atlas to avoid iatrogenic injury to the vertebral artery. According to Simpson et al[41], the surgical exposure of the posterior arch should not exceed 15 mm from the midline in adults and 10 mm in children. Max franco de carvalho[42] suggested that the posterior dissection of the posterior arch should be limited to a distance of 11.2 mm from the midline. Stauffer[40] recommends a safe zone of 10 mm from the posterior midline. Ebraheim et al[43] noted the safe zone as 10 mm for males and 9 mm for females from the posterior midline. All these data belong to the Western literature. However, the standard textbooks on posterior exposure suggest a safe distance of 15 mm from the midline[44].

Lateral mass screw for the fixation of the atlas has become common for the treatment of atlantoaxial instability. Some surgeons have recommended that in the presence of a broad posterior arch of the atlas, the insertion of the screw be started in the dorsal aspect of the posterior arch instead of at the base of the lateral mass or at the junction of the posterior arch and the lateral mass[45]. A broad dorsal arch of the atlas is the best indication for this modified screw trajectory. The ponticulus posticus/arcuate foramen carrying vertebral artery can be mistaken for a broad dorsal arch and the surgeon may insert the screw into the ponticulus posticus[45]. This may result in injury to the vertebral artery and lead to stroke or even death by thrombosis, embolism or arterial dissection [45]. Therefore the presence of this anomaly should be carefully checked before screw placement in the lateral mass of the atlas to avoid vertebral artery injury.

Bridges and ponticulus normally occur in monkeys and lower animals. In quadrupeds, the superior margin of posterior bridge provides greater surface area for the attachment of posterior atlanto- occipital membrane helping to support the weight of head. In human beings the weight is received by the superior articular facets of the atlas, thus the bridge has disappeared.

5.2. Foramen Transversarium

(4) The presence of double foramen transversarium may be correlated with duplicate vertebral artery. This may create confusion to surgeons during surgery around this region and misinterpretation of radiographs. An accessory foramen transversarium on the posterior arch of atlas vertebra can lead to symptoms like headache, migraine and fainting attacks[31]. Open foramen transversarium anteriorly may expose the vertebral vessels which are at risk of being

damaged.

Thus normal and variant anatomy of atlas is of paramount importance to clinicians for various types of pathologies associated with atlas, for surgeons for carrying out surgical procedures around this region, radiologists for avoiding misinterpretation of radiographs and anatomists for the source of database.

REFERENCES

- [1] Susan Standring Gray's Anatomy, The anatomical basis of clinical practice. The back 40th ed. Churchill Livingstone Elsevier 719-720 (2008).
- [2] Sharma M, B. Singh, A. Abhayal and H. Kumar Occipitalization of atlas with other associated anomalies of skull Eur J Anat, 12 (3): 159-167 (2008).
- [3] Lanier RR An Anomalous cervico-occipital skeleton in man. *Anat Rec*, 73: 189-207 (1939a).
- [4] Lanier RR The presacral vertebrae of American white and Negro males. *Am J Phys Anthropol*, 25: 341-420 (1939b).
- [5] AL-Motabagani ma and Surendra M Total occipitalization of the atlas. *Anat Sci Int*, 81: 173-180 (2006).
- [6] Gladstone RJ and Erichsen-Powell W Manifestations of occipital vertebrae and fusion of the atlas with the occipital bone. *J Anat Physiol*, 59: 190-209 (1915).
- [7] Green hlHH An unusual case of atlanto-occipital fusion. *J Anat*, 65: 140-144 (1930).
- [8] McRae DL and Barnum AS Occipitalization of the atlas. *Am J Roentgenol*, 70: 23-46 (1953).
- [9] Misra BD A case of atlanto occipital fusion. *J Anat Soc India*, 3: 45-46 (1954).
- [10] Shehata R Occipitalization of the atlas. *J Anat Soc India*, 13: 97-99 (1964).
- [11] Kalka AK, Khanna S, Singh IP, Sharma S, Schnobel R and Vogel F A genetic and anthropological study of atlanto-occipital fusion. *Hum Genet*, 81: 105- 112 (1989).
- [12] Warner WC Pediatric cervical spine. In: Canale ST (ed). *Campbell's Operative Orthopaedics*, 10th ed. Vol. 2. Mosby, St. Louis, pp 1736-1737 (2003).
- [13] Turek SL Craniovertebral region. In: Turek SL (ed). *Orthopaedics: Principles and Their Application*, 4th ed. Vol. 2. JB Lippincott, Philadelphia, pp 874-884 (1984).
- [14] Bernini F, Elefante R and Smaltino F Angiographic study on the vertebral artery in cases of deformities of the occipitocervical joint. *Am J Roentgenol*, 107: 526-529 (1969).
- [15] Choi JW, Jeong JH, Moon SM and Hwang HS. Congenital cleft of anterior arch and partial aplasia of the posterior arch of C1. *AJNR Am J Neuroradiol* 15 (2): 249-54 (1994).
- [16] Klimo P Jr, Blumenthal DT, Couldwell WT. Congenital partial aplasia of the posterior arch of atlas causing myelopathy: case report and review of literature. *J Korean Neurosurg Soc* 49(3): 178-81 (2011).
- [17] Currarino G, Rollins N & Diehl JT - Congenital defects of the posterior arch of the atlas: a report of seven cases including an affected mother and son. *AJNR Am J Neuroradiol* 15(2): 249-54 (1994).
- [18] Sabuncuoglu H, Ozdogan S, Karadag D, Kaynak ET. Congenital hypoplasia of the posterior arch of the atlas: case report and extensive review of the literature. *Turk Neurosurg* 21(1): 97-103 (2011).
- [19] Kimmerle A. Ponticulus Posticus. *Rontgenprax.* 2: 479-483 (1930).
- [20] Singh R Bilateral arcuate foramen in human Atlas vertebra. *Journal of Anatomical Sciences.* 21(1): 38-40 (2013).
- [21] Mitchell J. The incidence and dimensions of the retroarticular canal of the atlas vertebra. *Acta Anat* 163: 113-120 (1998b).
- [22] Pyo J. Lowman R. The Ponticulus Posticus of the first cervical vertebra. *Radiology.* 72:850-854 (1959).
- [23] Erdogann Unur, Nuri Erdogan, Harun Ulger, Nihat Ekinci, Omer Ozturk. Radiographic incidence of complete arcuate foramen in Turkish Population. *Erciyes Medical Journal* 26 (2) 50-54 (2004).
- [24] Asvat R. The incidence of posterior atlas bridging in a black and white south African samples. *J Anat* 184:437 (1994).
- [25] Taitz C and Nathan H. Some observations on the posterior and lateral bridging of the atlas *acta Anat* 127: 212-217 (1986).
- [26] Saunders SR, Popovich FA Family study of two skeletal variants: atlas bridging and clinoid bridging *Amer J Phys Anthropol* 49:193-204 (1978).
- [27] Farman AG, Nortje CJ, De V, Joubert JJ. Radiographic profiles of the first cervical vertebra *J anat* 129: 595-600 (1979).
- [28] Manjunath KY. Posterior bridging of the atlas vertebra in South Indians. *Indian J Med Sci* 55: 488-90 (2001).
- [29] Das Srijit, Suri R, Kapur V. Double foramen transversarium : An osteological study with clinical implications *Int Med J* 12(4): 311-313 (2005).
- [30] Taitz C, Nathan H, Arensburg B: Anatomical observations of the foramina transversaria. *J Neurol Neurosurg Psychiatr* 41: 170-176 (1978).
- [31] Satheesha Nayak B. Abnormal foramina on the posterior arch of atlas vertebra *IJAV* 1: 21-22 (2008).
- [32] Tachdjian MO Congenital anomalies of the occiput and cervical spine. In: Tachdjian MO (ed). *Pediatric Orthopedics*, 2nd ed. Vol. 3. WB Saunders, Philadelphia, pp 874-875 (1990).
- [33] Chandraraj S and Briggs CA Failure of somite differentiation at the cranio-vertebral region as a cause of occipitalization of the atlas. *Spine*, 17: 1249-1251 (1992).
- [34] Peters H, Wilm B, Sakai N, Imai K, Maas Rand Balling R Pax1 and Pax9 synergistically regulate vertebral column. *Dev*, 126: 5399-5409 (1999).
- [35] Setby S, Garn SM, Kanareff V. The incidence and familial

- nature of a bony bridge on the first cervical vertebrae. *Amer J Phys Anthropol* 13:129-141 (1995).
- [36] Bharucha EF and Dastur HM Craniovertebral abnormalities: A report of 40 cases. *Brain*, 87: 469-480 (1964).
 - [37] Garg A, Gaikwad SB, Gupta V, Mishra NK, Kale SS, Singh J. Bipartite atlas with os odontoideum: case report *J Spinal Disord Tech* 22(4): 233-9 (2009).
 - [38] Yong Jae Cho Radiological Analysis of Ponticulus Posticus in Koreans. *Yonsei Med J* 50(1): 45-49 (2009).
 - [39] Gupta T Quantitative anatomy of vertebral artery groove on the posterior arch of atlas relation to spinal surgical procedures. *Surg Radiol Anat* 30 (3): 239-42 (2008).
 - [40] Stauffer ES. Posterior atlanto-axial arthrodesis: the Gallie and Brooks techniques and their modifications. *Tech Orthop*. 9: 43-8 (1994).
 - [41] Simpson JM, Ebraheim NA, Jackson WT et al. Internal fixation of the thoracic and lumbar spine by using Roy-Camille plates. *Orthopedics* 16: 663-72 (1993).
 - [42] Max Franco de Carvalho, Roberta Teixeira Rocha et al. Vertebral artery groove anatomy. *Acta Ortop Bras* 17(1): 50-54 (2009).
 - [43] Ebraheim NA, XU R, Ahmad M. The quantitative anatomy of the vertebral artery groove of the atlas and its relationship to the posterior atlantoaxial approach. *Spine*.; 23: 320-3 (1998).
 - [44] Maxim R. Leventhal. *Campbell's Operative Orthopaedics In: Spinal Anatomy and surgical Approach*. 9th edn; Vol. 3. Mosby, St. Louis; (1998): 2681-270. *Spine (Phila Pa 1976)*. 2003 Jun 15;28(12):E224-8.
 - [45] Young JP, Young PH, Ackermann MJ, Anderson PA, Riew KD. The ponticulus posticus: implications for screw insertion into the first cervical lateral mass. *J Bone Joint Surg Am*. 87:2495–2498 (2005).