

# Surgical Features of Bone Resection During Lower Limb Amputations in Patients with Diabetic Gangrene

I. S. Sattarov\*, Q. J. Matmurotov, Yakubov I. Y.

Department of General and Pediatric Surgery №1, Tashkent State Medical University, Tashkent, Uzbekistan

**Abstract** The results of the examination and treatment of 54 patients for 2021 - 2025 were analyzed with diabetic gangrene of the lower extremities, who received inpatient treatment with limb amputation at the level of the upper third of the leg. Analysis of the results of treatment of patients with diabetic gangrene of the limb showed that with the correct determination of the level of amputation of the lower extremities in 85.2% of cases it is possible to ensure a smooth postoperative course, with primary wound healing. The resection of the tibia without damaging the feeding artery made it possible to preserve the functional state of the knee joint even with the development of purulent complications in the wound area in 7 cases out of 8.

**Keywords** Diabetes mellitus, Critical ischemia, Gangrene, Purulent-necrotic process

## 1. Introduction

One of the most severe complications of diabetes mellitus (DM) as a result of surgical manipulation is diabetic foot syndrome (DFS). DFS manifests itself in the form of the development of common purulent-necrotic lesions in the lower extremities, which develop in 35-60% of patients with diabetes [1,3]. In foreign and domestic epidemiological studies, the number of DFS ranges from 30% to 80% of the total number of patients with type 2 diabetes [2]. Such fluctuation of occurrence is associated with late negotiability, which is caused by asymptomatic diabetes mellitus. During treatment, patients often already have widespread purulent-necrotic lesions, even gangrene [4,5].

The prevalence of critical ischemia on the background of diabetes mellitus increases with age: among patients at the age of 40, it is about 3%, among patients at the age of 60 years - 9%. Of interest is the fact that from 10 to 50% of patients with diabetic foot syndrome never go to the doctor about the symptoms. Late treatment of purulent-necrotic lesions leads to loss of the limb [2,7].

During the first year after verification of the diagnosis of critical lower limb ischemia (CLLI), 15–20% of patients with diabetes mellitus have a high limb amputation [8,10]. The immediate and long-term results of amputation largely depend on the level of truncation of the limb. Transtibial amputation is accompanied by half the mortality and has significantly higher prospects for subsequent rehabilitation

[13]. The implied goal of amputation is to achieve primary wound healing of the lower limb at the most distal level possible. Energy consumption during movement increases with increasing amputation from the shin to the thigh. Preserving the knee joint and a significant segment of the tibia allows the use of lightweight prostheses, minimizes energy consumption during movement and allows older or weaker patients to walk independently [6,12].

Historically, the level of the intended amputation was determined by a clinical examination of the lower limb by the surgeon immediately before the operation. The chosen site is usually evaluated further in the operating surgeon, who notes the appearance of the subcutaneous tissue and muscle and the presence or absence of bleeding from dissected tissues. The appearance of ischemic or necrotic tissue or the absence of bleeding at the edges of the incision often serve as a basis for attempting to perform amputation at a higher level [2,11,12].

Convincing evidence that describe the role of subjective opinion in assessing the likelihood of wound healing after trans-femoral amputation was presented in a large study by J. Dormandy et al. [9]. Data were obtained for 713 patients who required amputation below the knee in 51 hospitals in 6 European countries. The results of the study showed that after 3 months, 59% of the stumps healed, 19% required an amputation at a higher level, and 11% remained unhealed. The surgeon's assessment of the likelihood of healing was incorrect in 21% of cases, when the operating surgeon believed that the postoperative wound would heal. It was also incorrect in 52% of cases when it was thought that wound healing would not take place.

It is widely believed that an increase in the ratio of amputation below the knee and amputation above the knee

\* Corresponding author:  
inoyat31@gmail.com (I. S. Sattarov)

Received: May 6, 2026; Accepted: May 25, 2026; Published: Jun. 2, 2026  
Published online at <http://journal.sapub.org/ajmms>

should inevitably lead to a higher failure rate. However, this opinion is not confirmed by a comparative analysis of the results [13]. According to published studies on the frequency of late healing and revision after amputation below the knee, the frequency of primary healing ranged from 30 to 92% (70–75% on average), and the reamputation frequency ranged from 4 to 30% (average 15%). In approximately 15% more cases, later or secondary healing took place, which in some cases required rehabilitation and further operations, such as a wedge-shaped excision in order to preserve the length of the lower limb. Of the 30% of patients with amputation below the knee, in whom the wounds do not heal initially, approximately half require reamputation at a higher level. To heal a postoperative wound, more blood flow is needed than maintaining skin vitality without surgery. After wound healing with a high amputation below the knee, only 4% of patients later require a higher amputation [10].

At the present time cannot be considered as an ideal criterion for the choice of the level of amputation. In general, the more often an attempt is made to save the knee, the more often it succeeds. Thus, the use of an aggressive brigade approach to amputations led to an increase in the ratio of amputation below the knee and amputation above the knee from an unusually low figure of 0.14 to 2.1.

In connection with this problem, the purpose of this study was to improve the results of leg amputations taking into account the state of the angioarchitecture of the leg in patients with diabetic lower limb gangrene (DLLG).

## 2. Material and Methods

The results of the examination and treatment of 54 patients for 2021 - 2025 were analyzed with diabetic gangrene of the lower extremities, who received inpatient treatment with limb amputation at the level of the upper third of the leg in the Republican center of purulent surgery and surgical complications of diabetes at the 2nd clinic of the Tashkent Medical Academy.

The average duration of diabetes in patients was  $13.7 \pm 4.5$  years. The age of patients ranged from 26 to 81 years (on average,  $53.1 \pm 5.2$  years). Among the patients, there were 43 (79.6%) men and 11 (20.4%) women. The neuroischemic form of diabetic foot syndrome was diagnosed in 39 (72.2%) patients, ischemic - in 15 (27.8%). The duration of inpatient treatment of patients averaged 4-7 days.

19 (35.2%) patients had signs of coronary heart disease (CHD), 8 (14.8%) patients had a history of myocardial infarction. In 11 (20.3%) patients, transient cerebral circulatory disorders occurred, 7 (13%) patients in the past suffered an acute cerebrovascular accident. In 21 (38.9%) patients, there was arterial hypertension.

The instrumental method of assessing the state of the peripheral arterial bed was multispiral computed tomography (MSCT) of the lower limb arteries. After receiving

information about the state of the peripheral arterial bed and the impossibility of restoring peripheral arterial blood flow, all patients underwent amputation of the tibia at the level of the upper third.

Statistical data processing was carried out by using computer programs for statistical processing of the DBASE database and STAT4. For calculations, statistical methods for estimating differences in averages using Student's t-test were utilized.

All patients underwent amputation of the lower leg according to the method developed by us (patent RUz №IAP 2018 0251 of 06.06.2018) [1]. The technique of this method begins with the formation of the anterior and posterior skin and fascial flaps, which include the skin, subcutaneous tissue and its own fascia. After muscle incision and resection of the bones of the tibia, characterized in that the resection of the bones of the tibia is performed 12-15 cm below the knee gap with preservation of the **nutritive artery (a. nutricium)** of the tibia, leaving a short anterior (4-5 cm) and posterior, long flap (15-17 cm).

The anterior and posterior skin-fascial flaps are formed, while the posterior flap is almost three times larger than the anterior flap and includes the gastrocnemius muscle to prevent stump tension. The determination of the level of amputation was made according to the clinical picture of ischemia and the state of the peripheral arterial bed of the limb.

When analyzing the results of treatment of patients with favorable immediate outcome of amputation, primary healing of a postoperative wound was considered. Suppuration of the postoperative wound with secondary healing and gangrene of the stump of the lower leg, which later leads to re-amputation at the level of the thigh, and we also attributed death to adverse results of amputation.

## 3. Results

As a result of the analysis, it was revealed that 38 (70.3%) patients out of 54 before entering our department underwent various surgical interventions.

On admission to a history of 27 patients (50%), minor surgical interventions were performed on the foot and in 11 (20.3%) patients various vascular operations were performed on the limb arteries due to occlusive stenotic lesions. The revascularization of the lower limb arteries was performed in 5 (9.2%) cases (including one patient performed in our clinic).

**Clinical example.** Patient S., 61 years old, entered the department of the Republican center of purulent surgery and surgical complications of diabetes (RCPS and HOSD) on 10.22.2021. (History number 13261/1815) with diagnosis of Diabetes Mellitus type 2, severe form, in the stage of decompensation. "Diabetic foot syndrome", neuroischemic form. Critical ischemia of the lower extremities, IV degree, according to Fontein-Pokrovsky. Gangrene of the left foot.

**Table 1.** Characteristics of surgical interventions in patients upon admission to the clinic

№	Surgery	Number of patients (n=38)	%
1	Minor surgeries done on foot:	27	71.0
	-toe amputation	11	29.0
	-opening of phlegmon of the foot	9	23,6
	-metatarsal amputation of the foot	7	18,4
2	Open and closed vascular operations:	11	29.0
	-thrombectomy from superficial femoral artery (SFA) and PA	4	10,5
	-femoral-popliteal bypass	2	5,2
	-Ballon angioplasty of arteries in lower extremities	5	13,1
Total		38	100

Accompanied with: CHD. Angina pectoris FC II. PICS (2018). Diabetic nephropathy. Anemia 2 stage.

On admission, the patient complained of persistent severe pain in the left foot at rest, blackening of the entire foot with the transition to the lower leg, an increase in body temperature to 38.2 °C, insomnia and general weakness. From the anamnesis, she suffers from diabetes for 15 years and regularly receives insulin. On examination, the general condition is stable and severe. Skin and visible mucous pale color. Pulse 96 per minute. BP - 130/90 mm Hg. Locally: the lower limbs are asymmetrical due to swelling of the left tibia, the skin of the entire left foot to the ankle joint is covered with a black scab, and palpation marks swelling and tenderness of the foot. The pulsation on the left femoral artery is preserved, on the popliteal artery (PA) weakened, on the foot arteries is not detected. There is a partial contracture of the muscles of the left leg.

The patient received standard laboratory research methods:

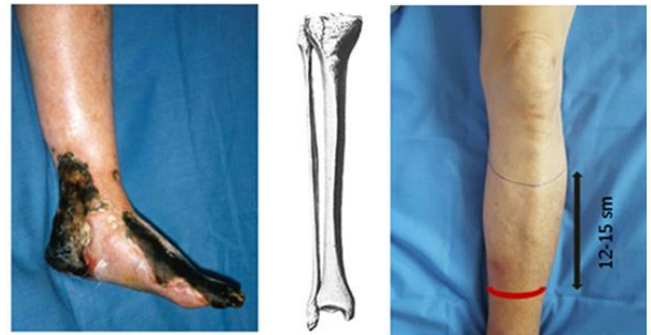- 1) Complete blood analyses: Hb - 108 g/l; red blood cells - 3.0; CI - 0.9; leukocytes - 26.4; eosinophil - 1%; stab - 6%; segmented - 65%; monocytes - 2%; lymphocytes - 25%;
- 2) Urine analysis: color - yellow; specific weight - 1044; the reaction is acidic; protein - 0,066; epithelium - 2-3 in per field of vision; leukocytes - 1-3 per field of vision;
- 3) Biochemical blood test: total bilirubin - 11.2 µmol/l; urea - 9.1 mmol/l; creatinine - 123 µmol/l; blood sugar - 7.7 mmol/l.

From instrumental methods of research, duplex of lower limb arteries was performed, echo-indications of occlusive lesions of the lower limb arteries are visualized: secondary vascular lesion on the background of DM in combination with atherosclerotic, characterized by change in the spectral characteristics of blood flow in PA, lack of blood flow in anterior and posterior tibial arteries (ATA and PTA), and arteries of the foot.

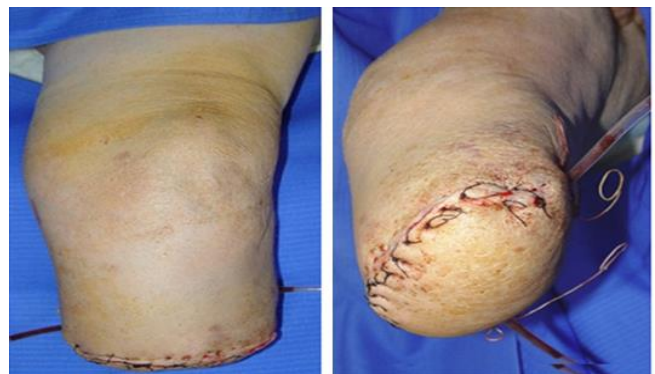
Considering the clinical and instrumental data, the patient 10/24/2020 the operation was performed - amputation of the

left lower extremity at the level of the upper middle third of the leg according to the method proposed by us.

The operative field is processed in the standard way: 3-fold treatment with betadine and alcohol (70 °C). A semilunar incision of the upper middle part of the anterior surface of the tibia was performed, creating an anterior (4 cm) and posterior flap (16 cm), including the skin, subcutaneous tissue and the fascia of the tibia itself, so that their length will allow covering the stump with a free skin flap (Fig. 1). Next, a resection of the tibia bone was performed using a Gigue saw at 13 cm below the knee cleft with preservation of the **nutritive artery (a. nutriticum)** and resection of the fibula was performed 2.5 cm proximal to the tibia, followed by ligation of the lower leg vessels and nerves.



**Figure 1.** The local status of the patient and the level of amputation of the leg



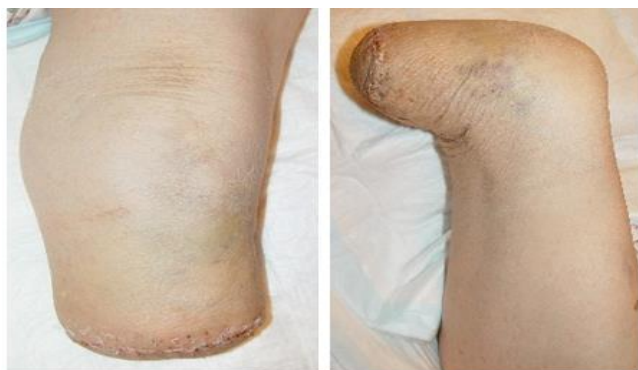**Figure 2.** Postoperative lower leg stump

**Table 2.** The results of treatment of patients after amputation of the leg

№	Therapy results	Ischemic	Neuroischemic	Number of patients (n=54)
1	Primary healing	11(24,0)	35(76,0)	46(85,2)
2	Suppuration stump	1(25,0)	3(75,0)	4(7,4)
3	Ishemic stump phenomena	2(66,7)	1(33,3)	3(5,6)
4	Reamputation at hip level	1(100)	-	1(1,8)
Total		15(27,8)	39(72,2)	54(100)

After careful hemostasis, the soleus muscle of the calf was isolated by blunt method and removed proximally from the site of attachment. The wound was sanitized with antiseptics and a control revision of the wound, with hemostasis. Before closing the flaps of the stump, the postoperative wound is drained through a counter-perception using a drainage tube with a conduit under the tibia (Fig. 2).

Next, suturing the calf muscle to the anterior flap with the closure of the tibia and suturing the skin-fascial flap. Aseptic pressure bandage. Smooth postoperative course. The drain tube was removed on the 2<sup>nd</sup> day after surgery. The patient was discharged from the clinic on 27/10/2021. Removal of sutures on the 14th day (Fig. 3).

**Figure 3.** The appearance of the stump (after 18 days)

Patient was discharged from clinic in a satisfied condition and was examined after three months: he was using prostheses and was active.

When analyzing the obtained results, it was revealed that 46 (85.2%) patients had amputation stumps healed by primary intention. Postoperative suppuration of the lower leg stump was observed in 4 cases (7.4%) and in all patients it was possible to heal the wound by secondary intention.

In 3 (5.6%) patients in the postoperative period, signs of stump ischemia were noted, which were stopped by conservative treatment without any repeated surgical interventions. Lethal outcomes in patients after amputation of the leg were not observed.

In our study, re-amputation at the level above the knee joint was performed to one (1.8%) patient, due to postoperative gangrene of the lower leg stump, which showed signs of systemic inflammatory response syndrome (SIRS) and chronic renal failure upon admission to the clinic.

## 4. Discussion

Analysis of the results of treatment of patients with diabetic gangrene of the limb showed that with the correct determination of the level of amputation of the lower extremities in 85.2% of cases it is possible to ensure a smooth postoperative course, with primary wound healing. These results were achieved due to the correct selection of the level of amputation of the lower leg according to the original method developed by us. The resection of the tibia without damaging the feeding artery made it possible to preserve the functional state of the knee joint even with the development of purulent complications in the wound area in 7 cases out of 8. Amputation of the lower leg according to this technique, we were able to save the knee joint in 98.2% of cases.

Adequately select the level of amputation, in our opinion, is possible only by conducting a comprehensive examination of the patient, taking into account a number of objective data. In determining the level of amputation, one should take into account the general condition of the patient, the degree of endogenous intoxication, and the data of the examination of the limb.

The question of the need for limb amputation in patients with diabetic gangrene should be resolved only after assessing the possibility of a reconstructive vascular operation, the successful implementation of which reduces the level of amputation. In preparation for the amputation of the lower leg, it is important to pay special attention to the correction of the rheological and coagulation properties of the blood, the normalization of the functional state of the heart, as well as specialized psychotherapeutic training for timely and adequate psychological adaptation of the patient.

## REFERENCES

- [1] Babadjanov B.D., Matmurotov K.J., Atajanov T.Sh. Efficacy of Minimally Invasive Procedures in the Treatment of Lower Extremities Diabetic Gangrene // American Journal of Medicine and Medical Sciences 2019, 9(5): -P. 163-166.
- [2] Matmurotov Q.J., Sattarov I.S., Atajanov T.Sh., Safarov F.A. Tactics of Reconstructive and Plastic Surgical Operations in Diabetic Foot Syndrome. American Journal of Medicine and Medical Sciences 2025, 15 (4), 1273-1277.

- [3] Matmurotov Q.J., Sattarov I.S., Atajonov T.Sh. Selective intraarterial catheter therapy in the complex treatment of gangrene in patients with diabetes mellitus. *Zamonaviy tibbiyot jurnali* 2025, 8 (1), 320-327.
- [4] Matmurotov Q.J., Sattarov I.S. Critical ischemic attack of arterial basin in type 2 diabetes mellitus. *Journal of educational and scientific medicine*. Vol. 2022, №1(05). 138-142.
- [5] Vachev A.N., Chernovalov D.A., Mikhailov M.S. Small amputations in critical ischemia of the lower extremities // *Angiology and Vascular Surgery*. - 2010.-T. 16, No. 4. -P. 59-60.
- [6] Russian conciliation document “National guidelines for the management of patients with vascular arterial pathology.” - M., 2015. Part I. - 76 p.
- [7] Pokrovsky A.V. *Clinical angiology: a manual for doctors: in 2 tons*. - M.: Medicine, 2024. - 808 p.
- [8] Soroka V.V., Nokhrin S.P., Ryazanov A.N. Amputation of the lower limb in the treatment of patients with critical ischemia // *Angiology and Vascular Surgery*. - 2020. - V. 16, № 4. - P. 329-330.
- [9] Graziani L. et al. // *Eur J Vasc Endovasc Surg*. -2005. -№ 29. -P. 620-627.
- [10] Standards of Care in Diabetes. American Diabetes Association // *Diabetes Care*. -2010. -№ 1. -P. 12-65.
- [11] Dormandy J., Rutherford R. Management of peripheral arterial disease (PAD) TASC Working group // *J. Vasc. Surg*. -2017. -№ 31. -S1- S296.
- [12] Hiatt W. Medical treatment of peripheral arterial disease and claudication // *N. Engl. J. Med*. -2021. -№ 344. -P. 1608-1621.
- [13] Regenshtien J., Ware J. McCarthy W., Zhang P, Forbes W. Heckman J, Hiatt W. Effect of cilostazol on treatment of patients with PAD // *J. Am. Geriatr. Soc*. -2022. -№ 50. -P. 1939-1946.