

Results of Studying the Periodontal and Hygiene Indices in Patients with Leukemia

Akhmedov S. P.¹, Yunuskhodjaeva M. K.², Xasanova L. E.²

¹Samarkand State Medical University, Samarkand, Uzbekistan

²Tashkent State Medical University, Tashkent, Uzbekistan

Abstract The article presents the results of a study on the periodontal condition and oral hygiene level in patients with various forms of leukemia. Assessment of common indices, including the hygiene index (OHI-S), revealed the features of inflammatory-destructive changes in periodontal tissues and hygiene status disorders in this category of patients. It was established that in patients with leukemia, the index values were significantly higher than in the control group, indicating a pronounced predisposition to the development of inflammatory processes and complications in the oral cavity. The obtained data emphasize the need for comprehensive dental care for leukemia patients, including regular monitoring of indices and implementation of preventive measures aimed at improving the hygiene condition and reducing the risk of complications.

Keywords Leukemia, Periodontal index, Hygiene index, Periodontium, Oral cavity, Dental prevention, Inflammation

1. Introduction

Diseases of the blood system, particularly leukemias, are accompanied by pronounced changes in various organs and tissues, including those of the oral cavity. Leukemias are characterized by impaired hematopoiesis, immune response, and a susceptibility to infectious and inflammatory complications [5]. The oral mucosa and periodontal tissues are among the most vulnerable structures, which is attributed to their high vascularization and constant exposure to microbes [6]. A significant clinical manifestation in this category of patients is inflammatory changes in the periodontal tissues, accompanied by bleeding, swelling, hyperplasia of the gingival margin, and deterioration of oral hygiene. The reduction in local protective factors and alterations in the microbiota composition contribute to the development of gingivitis and periodontitis even with relatively low dental plaque accumulation [3]. For an objective assessment of periodontal tissue condition and oral hygiene, indices such as the Simplified Oral Hygiene Index (OHI-S) are widely used. These indicators not only allow evaluation of the severity of inflammatory changes but also enable comparison of data between different patient groups [1,4].

Several studies indicate that leukemia patients have significantly higher periodontal and oral hygiene indices compared to healthy individuals [1,7]. This is attributed to both systemic changes (leukopenia, thrombocytopenia, immunodeficiency) and reduced motivation and ability to

maintain proper oral hygiene due to severe somatic conditions. Therefore, examining the periodontal condition and oral hygiene status of leukemia patients is a crucial task aimed at timely detection of dental complications and development of preventive measures.

2. Materials and Methods of Research

The study is based on the examination of 151 patients with acute and chronic forms of leukemia, comprising 62 women and 89 men aged 20 to 70 years.

The patients were hospitalized at the Research Institute of Hematology and Blood Transfusion of the Ministry of Health of the Republic of Uzbekistan. The diagnosis was made by a hematologist based on a comprehensive clinical and hematological examination of the patient, including mandatory cytological and cytochemical analysis of the bone marrow.

Between September 2020 and October 2024, 151 individuals were examined. Three clinical groups were formed for observation. The clinical facilities of the Research Institute of Hematology and Blood Transfusion provided the opportunity to conduct laboratory and clinical examinations. To assess the severity, the classification by L.S. Lyubimova et al. was employed.

The comprehensive examination included: eliciting patients' complaints, collecting medical history, visual inspection of the oral cavity, and index assessment.

Patient questioning involved: eliciting the patient's complaints about: discomfort, itching, gum tenderness, bleeding when mechanically irritated (when eating hard food, brushing teeth,

or spontaneously), bad breath, presence of lesions in the oral cavity; disease history; family history: presence of systemic diseases. The oral cavity examination was conducted under natural lighting using examination instruments. The condition of the vermillion border of the lips and corners of the mouth, and the oral mucosa was assessed.

3. Research Results

Mild generalized periodontitis is characterized by the presence of a periodontal pocket up to 4 mm deep, occasionally slightly mobile teeth, and observed gum bleeding. The periodontal index is elevated to 1.42 ± 0.2 , with an increase in the hygiene index to 2.67 ± 0.4 , and the hematoma formation time is shortened to 18.2 ± 2.1 sec.

Moderate generalized periodontitis is quite common. In this form, the depth of the pathological pocket reaches up to 5.5 mm. Tooth mobility is up to grade II. The periodontal index increases 2-fold compared to the mild degree (2.84 ± 0.14), the hygiene index rises to 3.9 ± 0.1 . A hematoma forms within 13 seconds.

Rapidly progressive periodontitis is the most common form in chronic leukemias. The course of this ailment is severe and prolonged. Tooth mobility reaches grades III and IV. The depth of the pathological pocket reaches up to 6 ± 0.9 mm. Pronounced traumatic occlusion is observed. The periodontal index increases 6-fold compared to mild periodontitis, the oral hygiene index increases 1.7-fold (4.6 ± 0.9), and the time of hematoma formation decreases to 9.8 ± 1.4 sec.

Thus, analysis of examination results in patients with

acute and chronic leukemias revealed a high prevalence of periodontal disease, among which severe forms of generalized gingivitis, moderate generalized periodontitis, and rapidly progressive periodontitis predominate.

As part of the study, indicators of oral hygiene status (OHI-S according to Greene-Vermillion), caries intensity (DMF - decayed, missing, and filled teeth), and the periodontal index (CPITN) were analyzed in patients with acute and chronic leukemias, as well as in control group individuals without hematological diseases. The results are presented in Table 1.

Table 1. OHI-S, CPITN, and DMF indicators in the examined patient groups

Indicator	Leukemia (n=60)	Control (n=30)	p
OHI-S, points	2.8 ± 0.6	1.5 ± 0.4	<0.001
DMF, units	14.2 ± 3.1	8.6 ± 2.5	<0.001
CPITN, points	3.2 ± 0.4	2.1 ± 0.5	<0.001

The average OHI-S score in leukemia patients was 2.8 ± 0.6 points, which corresponds to an unsatisfactory level of oral hygiene. In the control group, this indicator was significantly lower - 1.5 ± 0.4 points (satisfactory hygiene). A statistically significant difference ($p < 0.001$) indicates that patients with leukemia have a more pronounced accumulation of dental plaque and calculus. This is due to several factors, such as decreased motivation for oral hygiene as a result of severe general condition, pronounced gingival hyperplasia (especially in acute monoblastic leukemias) which makes mechanical cleaning difficult, and changes in saliva composition and viscosity during chemotherapy, which contribute to accelerated dental plaque formation.

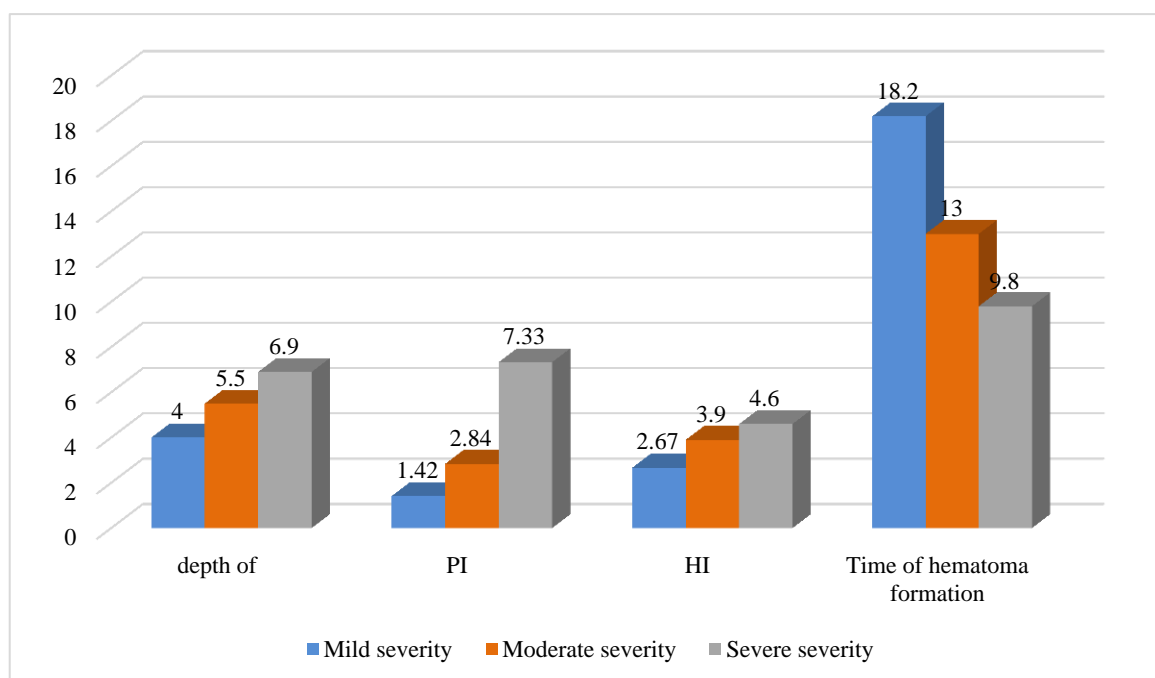


Figure 1. Indicators of periodontal status in patients with leukemia

The DMF index in patients with leukemia was significantly higher (14.2 ± 3.1) compared to the control group (8.6 ± 2.5 , $p < 0.001$). High values are attributed to both the active development of caries against a background of immunodeficiency and altered oral fluid composition, as well as the lack of timely dental intervention during intensive treatment of the underlying disease. In patients with chronic forms of leukemia, the prevalence of the index is due to filled and extracted teeth, while in acute forms, it is due to active carious cavities.

The average CPITN score in patients with leukemia was 3.2 ± 0.4 , indicating the need for comprehensive periodontal treatment, including dental calculus removal, curettage, and, in some cases, surgical correction of periodontal tissues. In the control group, this indicator was significantly lower (2.1 ± 0.5 , $p < 0.001$), corresponding to a moderate need for professional hygiene and gingivitis treatment. The high CPITN levels in leukemia patients are associated with neutropenia and susceptibility to periodontal infections, thrombocytopenia leading to bleeding and the inability to perform adequate hygiene procedures, and gingival tissue hyperplasia creating retention areas for microbial plaque.

4. Conclusions

The obtained data demonstrate that patients with leukemia experience a significant deterioration in oral hygiene, an increase in caries intensity, and more severe periodontal damage compared to individuals without hematological diseases. This confirms the need for early and regular dental

monitoring of such patients, starting from the moment of diagnosis, as well as the implementation of individualized prevention and oral cavity sanitation programs.

REFERENCES

- [1] Ainamo, J., & Bay, I. (1975). Problems and proposals for recording gingivitis and plaque. *International Dental Journal*, 25 (4), 229-235.
- [2] Brennan, M. T., Woo, S. B., & Lockhart, P. B. (2008). Dental management of patients with hematologic malignancies. *Oral Surgery, Oral Medicine, Oral Pathology, Oral Radiology, and Endodontology*, 106 (5), 770-776. <https://doi.org/10.1016/j.tripleo.2008.06.006>.
- [3] Carranza, F. A., Newman, M. G., Takei, H., & Klokkevold, P. R. (2021). *Carranza's Clinical Periodontology* (13th ed.). Elsevier.
- [4] Greene, J. C., & Vermillion, J. R. (1964). The Simplified Oral Hygiene Index. *Journal of the American Dental Association*, 68 (1), 7-13. <https://doi.org/10.14219/jada.archive.1964.0034>.
- [5] Gulyaev, S. A., Sedov, V. M., & Kolesnikova, L. I. (2017). Dental manifestations of blood system diseases. *Russian Dental Journal*, 21 (3), 45-49.
- [6] Ryakhovsky, A. N. (2019). The condition of the oral mucosa in blood system diseases. *Stomatology*, 98 (4), 59-64.
- [7] Sadovskaya, O. N., Plakhotnaya, I. M., & Melnikova, N. V. (2020). The condition of periodontal tissues in patients with hematological diseases. *Ural Medical Journal*, 10 (189), 112-116.