

Strategy for Performance of High Amputation in Case of Gangrene of the Lower Limb

K. J. Matmurotov*, P. Yu. Ruzmatov, B. M. Doniyorov

Tashkent State Medical University, Uzbekistan

Abstract The aim of the study is to improve the results of amputation at the level of the foot, taking into account the state of the angioarchitecture of the foot in patients with diabetic gangrene of the lower extremities. This article presents an analysis of the results of examination and treatment of 61 patients with gangrene of the lower extremities due to diabetes mellitus. Patients were hospitalized in 2023-2024. In the purulent surgery department of the multidisciplinary clinic of the Tashkent Medical Academy. The main instrumental method of the study was multidimensional computed tomography (MSCT) of the arteries of the lower extremities and duplex scanning of the arteries of the lower extremities. All patients were amputated at the level of the upper third of the lower leg using a new method developed by us. The analysis of the results of treatment of patients with diabetic gangrene of the limbs showed that with the correct determination of the level of amputation of the lower extremities, it is possible to ensure a smooth course of the postoperative period in 85.1% of cases. wound healing. These results were achieved by correctly selecting the level of leg amputation using the original method we developed. Resection of the tibia without damaging the feeding artery made it possible to maintain the functional state of the knee joint even with the development of purulent complications in the wound area in 8 out of 9 cases.

Keywords Diabetes, Critical ischemia, Purulent-necrotic ulcer, Gangrene

1. Introduction

Diabetic foot syndrome (DFS) is considered one of the most serious complications of diabetes mellitus (DM) leading to surgical procedures. In 35-60% of patients with diabetes, diabetic foot syndrome is manifested in the form of the development of widespread purulent-necrotic lesions in the lower extremities [1]. In foreign and domestic epidemiological studies, the number of DDS occurs in 30% to 80% of the total number of patients with type 2 diabetes [2]. Such a change in the disease is associated with the late manifestation of diabetes mellitus caused by the asymptomatic course. During treatment, patients often have already widespread purulent-necrotic lesions, even gangrene [3,4].

Age factor also plays an important role. The prevalence of critical ischemia due to diabetes mellitus increases according to the age: among patients aged 40 years it is about 3%, among patients aged 60 years – 9%. It is of interest that 10 to 50% of patients with diabetic foot syndrome never see a doctor about their symptoms. Untimely treatment of purulent-necrotic lesions leads to limb loss [5].

If we want to select the optimal level of amputation, it is necessary to determine the degree of ischemia of the limb at

the intended level of surgical intervention, since the poorly supplied stump becomes necrotic, which is the cause of severe purulent-septic complications [8]. Determining the level at which the blood supply to the stump can provide wound healing and nutrition to the remaining part of the limb is the main difficulty when deciding on amputation [6,7].

During the first year after verification of the diagnosis of critical lower ischemia (CLI) in patients with diabetes mellitus, high limb amputation is performed in 15–20% of patients [10]. The immediate and long-term results of amputation largely depend on the level of limb truncation. Transtibial amputation is accompanied by half the mortality rate and has significantly higher prospects for subsequent rehabilitation [13]. The implied goal of amputation is to achieve primary healing of the lower extremity wound as distally as possible. Energy expenditure during ambulation increases as the level of amputation increases from the lower leg to the thigh. Preservation of the knee joint and a significant portion of the tibia allows the use of lightweight prostheses, minimizes energy expenditure during ambulation, and allows older or weaker patients to walk independently [12].

Historically, the level of intended amputation was determined by clinical examination of the lower extremity by a surgeon immediately before surgery. The selected site is usually assessed further in the operating room by the surgeon, who notes the appearance of the subcutaneous tissue and muscle and the presence or absence of bleeding from the

* Corresponding author:

mjq_80@mail.ru (K. J. Matmurotov)

Received: Nov. 4, 2025; Accepted: Dec. 2, 2025; Published: Dec. 8, 2025

Published online at <http://journal.sapub.org/ajmms>

incised tissue. The appearance of ischemic or necrotic tissue or the absence of bleeding at the edges of the incision often leads to an attempt to perform amputation at a higher level [11,14].

Convincing evidence characterizing the role of subjective opinion in assessing the likelihood of wound healing after transfemoral amputation was presented in a large study by J. Dormandy et al. [9]. Data were obtained from 713 patients requiring below-knee amputation in 51 hospitals in 6 European countries. The study results showed that after 3 months, 59% of the stumps were healed, 19% required amputation at a higher level, and 11% remained unhealed. Surgeons' assessment of the likelihood of healing was incorrect in 21% of cases where the operating surgeon believed that the surgical wound would heal. It was also incorrect in 52% of cases when it was thought that the wound would not heal.

It is widely believed that increasing the ratio of below-knee to above-knee amputations must inevitably lead to a higher failure rate. However, this opinion is not confirmed by a comparative analysis of the results [13]. In published studies of late healing and revision rates after below-knee amputation, primary healing rates ranged from 30 to 92% (average 70–75%) and reamputation rates ranged from 4 to 30% (average 15%). In approximately another 15% of cases there was delayed or secondary healing, which in some cases required debridement and further surgery such as wedge excision to preserve lower limb length. Of the 30% of below-knee amputees whose wounds do not heal initially, approximately half require reamputation at a higher level. To heal a postoperative wound, more blood flow is required than to maintain skin viability without surgery. After wound healing with a high amputation below the knee, only 4% of patients subsequently require a higher amputation [10].

Currently cannot be considered as an ideal criterion for choosing the level of amputation. In general, the more often knee preservation is attempted, the more often it is successful. Thus, an aggressive team approach to amputations increased the ratio of below-knee to above-knee amputations from an unusually low 0.14 to 2.1.

In connection with this problem, the purpose of this study was to improve the results of amputations at the level of the lower leg, taking into account the state of the angioarchitecture of the lower leg in patients with diabetic gangrene of the lower extremities (DLG).

2. Material and Methods of Treatment

The results of examination and treatment of 61 patients from 2023 to 2024 were analyzed. with diabetic gangrene of the lower extremities, who received inpatient treatment with amputation of a limb at the level of the upper third of the leg in the department of purulent surgery and surgical complications of diabetes at the multidisciplinary clinic of the Tashkent Medical Academy.

In the analysis, the average duration of diabetes mellitus in

patients was 11.5 ± 3.8 years. The age of the patients ranged from 27 to 79 years (average 51.4 ± 4.5 years). Among the patients, there were 44 (72.1%) men and 17 (27.9%) women. The neuroischemic form of diabetic foot syndrome was diagnosed in 37 (60.6%) patients, the ischemic form - in 24 (39.4%). The average duration of inpatient treatment for patients was 4-6 days.

21 (34.4%) patients had signs of coronary heart disease (CHD), 9 (14.7%) patients had suffered a myocardial infarction in the past. 13 (21.3%) patients had transient cerebrovascular accidents, 9 (14.7%) patients had suffered an acute cerebrovascular accident in the past. 19 (31.1%) patients had arterial hypertension.

The diagnostic method was multislice computed tomography (MSCT) of the arteries of the lower extremities. After receiving information about the condition of the peripheral arterial bed and the impossibility of restoring blood flow, all patients underwent amputation of the lower leg at the level of the upper third. Statistical processing of the data was carried out using applied computer programs for statistical database processing DBASE and STAT4. For calculations, statistical methods were used to assess differences in average values using Student's t-test.

All patients underwent amputation of the lower leg according to the method we developed (patent of the Republic of Uzbekistan No. IAP 2018 0251 dated 06/06/2018) [1]. The technique of this method begins with the formation of anterior and posterior fasciocutaneous flaps including skin, subcutaneous tissue and its own fascia. After incision of the muscles and resection of the bones of the tibia, characterized in that the resection of the bones of the tibia is performed 12-15 cm below the knee gap, preserving **the nutrient artery (a. nutricium)** of the tibia, leaving a short anterior (4-5 cm) and posterior, long flap (15-17 cm).

Anterior and posterior fasciocutaneous flaps are formed, with the posterior flap being almost three times larger than the anterior flap and including the gastrocnemius muscle to prevent tension on the stump. The level of amputation was determined based on the clinical picture of ischemia and the condition of the peripheral arterial bed of the limb. Research methods were used to characterize the main and collateral blood circulation in the extremities, microcirculation and tissue trophism.

When analyzing the results of treatment of patients, primary healing of the postoperative wound of the stump was considered a favorable immediate outcome of amputation. We classified suppuration, secondary healing, reamputation, and death as unfavorable results of amputation.

Upon admission, 15 patients (24.6%) had a history of minor surgical interventions on the foot and 11 (18%) patients underwent various open vascular operations on the arteries of the limb due to occlusive-stenotic lesions (6) and endovascular treatment methods (5). Balloon angioplasty of the arteries of the lower extremities was performed in 5 (8.2%) cases (including one patient who underwent balloon angioplasty in our clinic).

3. Results and Its Discussion

As a result of the analysis, it was revealed that 26 (42.6%) patients out of 61 had undergone various surgical interventions at the place of residence or in other medical institutions before admission to our department.

Data from studying the state of arterial blood flow in the lower extremities of patients made it possible to identify frequently affected arterial segments and angiosomes of the foot.

At the same time, it was revealed that of the angiosomes II and III (24.6%) are most often affected, which feed on the STBA (Table 2). Combined damage to the anterior tibial arteries (ATA) and posterior tibial arteries (PTA) was observed in 23 cases (37.7%) and differed from other damage to the arterial basins by the appearance of purulent-necrotic processes in all angiosomes. A block at the level of the superficial femoral artery (SFA) in 5 (71.4%) out of 7 patients led to the appearance of purulent-necrotic foci in 2 or more angiosomes of the foot.

Clinical example. Patient S., 58 years old, was admitted to the department of the Republican Center for Gastrointestinal Surgery and Chostomy on October 22, 2023. (source No. 14443/1822) with a diagnosis of diabetes mellitus type 2, severe form, in the stage of decompensation. "Diabetic foot syndrome", neuroischemic form. Critical ischemia of the lower extremities IV degree according to Fontaine-Pokrovsky. Gangrene of the left foot.

Associated: IHD. Tension angina FC2. PEAKS (2017). CRF. Diabetic nephropathy. Anemia 2 tbsp.

Upon admission, the patient complained of constant severe pain in the left foot at rest, blackening of the entire foot extending to the lower leg, increased body temperature

to 38.2 °C, and general weakness. He has suffered from diabetes mellitus for 15 years and regularly receives insulin. On examination, the general condition is stable and serious. The skin and visible mucous membranes are pale in color. Pulse 96 per minute. Blood pressure – 130/90 mm Hg. Locally: the skin of the entire foot on the left up to the level of the ankle joint is covered with a black scab, swelling and pain on palpation are noted. The pulsation on the left femoral artery is preserved, on the popliteal (PcA) it is weakened, on the foot arteries it is not detected.

The patient underwent standard laboratory research methods: 1) general blood test: Hb - 108 g/l; red blood cells - 3.0; CPU - 0.9; leukocytes - 26.4; eosinophils - 1%; stab - 6%; segmented - 65%; monocytes - 2%; lymphocytes - 25%; 2) general urine analysis: color - light yellow; insight - frequent; beat weight - 1044; reaction - acidic; protein – 0.066; epithelium - 2-3 per view; leukocytes - 1-3 per view; 3) biochemical blood test: total bilirubin - 11.2 μmol/l; urea - 7.1 mmol/l; creatinine - 83 μmol/l; blood sugar - 7.7 mmol/l.

Instrumental research methods included: duplex examination of the arteries of the lower extremity, in which echo signs of occlusive lesions of the arteries of the lower extremity of a combined nature are visualized: secondary vascular damage against the background of diabetes mellitus in combination with atherosclerosis, characterized by a change in the spectral characteristics of blood flow in the RCA, lack of blood flow in the PBBA, SBBA and arteries of the foot.

Taking into account the clinical and instrumental data, the patient received an appointment on October 24, 2020. An operation was performed - amputation of the left lower limb at the level of the upper-middle third of the leg using the method we propose.

Table 1. Characteristics of surgical interventions in patients upon admission to the clinic

№	Operations	Number of patients (n=26)	%
1.	Minor surgical operations on the foot:	15	57,7
	- <i>finger amputation</i>	5	19,2
	- <i>opening of foot phlegmon</i>	3	11,5
	- <i>metatarsal foot amputation</i>	7	27,0
2.	Open and closed vascular surgeries:	11	42,3
	- <i>thrombectomy from SFA and RCA</i>	3	11,5
	- <i>femoropopliteal bypass</i>	3	11,5
	- <i>BAP</i>	5	19,2
Total		15	100

Table 2. The state of blood circulation of the lower extremities depending on the affected angiosomes

№	Angiosoma Lesion segment	Number of patients (n=61)	I	II-III	IV	V	VII	Damage to 2 or more angiosomes
1.	Occlusion SFA	7 (11,4)	-	1	-	-	-	4
2.	Defeat of PTTA	19 (31,1)	-	6	4	3	2	4
3.	Defeat of PBBA	12 (19,6)	4	5	-	-	3	-
4.	Defeat of ATTA and PTTA	23 (37,7)	2	4	5	4	4	4
Total		61 (100)	6 (9,8)	15 (24,6)	9 (14,7)	7 (11,4)	9 (14,7)	12 (19,6)

The surgical field was treated in a standard way: 3 times treatment with betadine and alcohol (70 °C). A semilunar incision was made in the upper-medial part of the anterior surface of the leg, creating an anterior (4 cm) and posterior flap (16 cm), including skin, subcutaneous tissue and the fascia of the leg, taking into account that their length will allow covering the stump with a free skin flap (Fig. 1).

Next, resection of the tibia was performed using a Zhigle saw at a level of 13 cm below the knee fissure, preserving the **nutrient artery (a. nutricium)** and resection of the fibula was performed 2.5 cm proximally compared to the tibia, with subsequent ligation of the vessels of the leg and alcoholization of the nerves.

After careful hemostasis, the soleus muscle of the leg was bluntly isolated and removed proximally from its insertion site. The wound was sanitized with antiseptics and a control revision of the wound was performed, with hemostasis. Before closing the flaps of the stump, the postoperative wound is drained through the counter-aperture using a drainage tube

passing under the tibia (Fig. 2).

Next, suturing the gastrocnemius muscle to the anterior flap with closure of the tibia and suturing the fasciocutaneous flap. Aseptic pressure dressing. Smooth postoperative course. The drainage tube was removed on the 2nd day after surgery. The patient was discharged from the clinic on October 27, 2023. Removal of sutures on the 14th day (Fig. 3).

The patient was discharged in satisfactory condition and examined three months later: he uses prostheses and is active.

When analyzing the results obtained, it was revealed that in 52 (85.1%) patients, the amputation stumps healed by primary intention. Postoperative suppuration of the leg stump was observed in 5 cases (8.3%) and in all patients the wound was able to heal by secondary intention. In 3 (5.0%) patients in the postoperative period there were signs of stump ischemia that could be relieved after removal of part of the stump sutures without necrectomy. In 1 (1.6%) case, reamputation was required. No lethal outcomes were observed in patients after leg amputation.

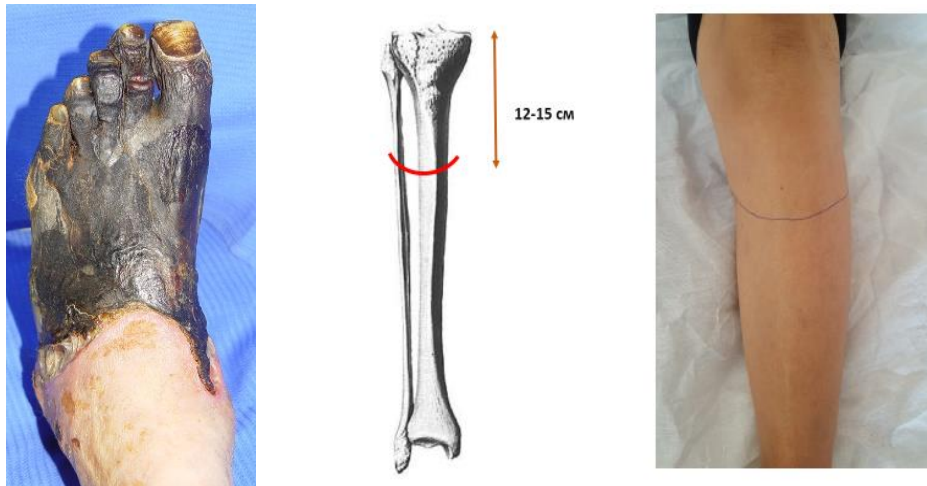


Figure 1. Local status of the patient and level of leg amputation

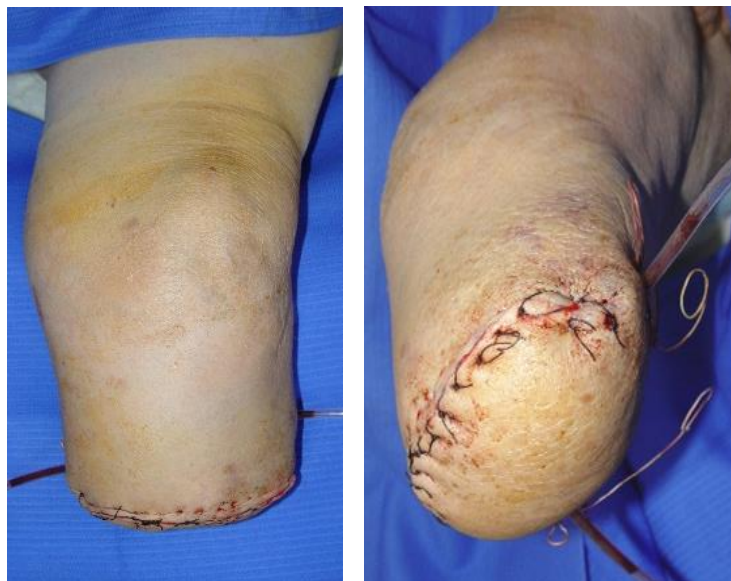

Figure 2. Postoperative view of the leg stump

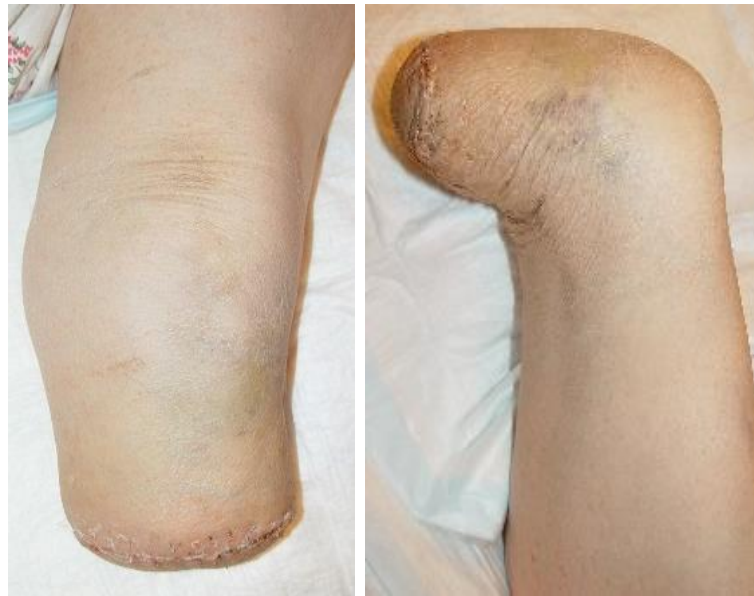

Figure 3. Appearance of the stump (after 18 days)

Table 3. Results of treatment of patients after leg amputation

№	Treatment result	Number of patients (n=61)	%
1.	Primary healing	52	85,1
2.	Suppuration of the stump	5	8,3
3.	Ischemic phenomena of the stump	3	5,0
4.	Reamputation of the lower limb at the hip level	1	1,6
	Total	61	100

Of the 5 (8.2%) patients with suppuration of the postoperative wound of the stump, 2 did without necrectomy (Table 3). The cause of suppuration in these patients was an infected hematoma.

In our study, reamputation at the level of the knee joint was performed in one (1.6%) patient due to gangrene of the stump. This patient initially had signs of systemic inflammatory response syndrome (SIRS) and chronic renal failure.

Results and Discussion

An analysis of the results of treatment of patients with diabetic gangrene of the limb showed that with the correct determination of the level of amputation of the lower extremities, in 85.1% of cases it is possible to ensure a smooth course of the postoperative period, with primary wound healing. These results were achieved through the correct selection of the level of leg amputation using the original method we developed. Resection of the tibia without damaging the feeding artery made it possible to ensure the preservation of the functional state of the knee joint even with the development of purulent complications in the wound area in 8 out of 9 cases.

Individually, adequately choosing the level of amputation, in our opinion, is possible only by conducting a comprehensive examination of the patient, taking into account a number of objective data. When determining the level of amputation, it is necessary to take into account the general condition of the

patient, the degree of endogenous intoxication, and examination data of the limb.

The issue of the need for limb amputation in patients with diabetic gangrene should be decided only after assessing the possibility of reconstructive vascular surgery, the successful implementation of which can reduce the level of amputation. The question of the possibility of direct revascularization of the limb should be decided before surgery based on the data of detailed duplex scanning and MSCT of the arteries of the lower extremities. When determining the level of amputation of a limb, it is necessary to objectively assess the degree of regional circulatory impairment based on the data from the above research methods.

When preparing for leg amputation, it is important to pay special attention to correcting the rheological and coagulation properties of blood, normalizing glycemia and the functional state of the heart and kidneys, i.e. multidisciplinary approach with the involvement of specialists for timely and adequate adaptation of the patient.

4. Conclusions

1. Amputation of the lower limb at the level of the lower leg in patients with diabetic gangrene according to the original method we proposed (patent of the Republic of Uzbekistan No. IAP 20180251 dated June 6, 2018)

allows preserving the knee joint in 98.4% of cases. In 85.1% of patients, a smooth postoperative course was observed.

2. Anatomically justified resection of the tibia will allow the rapid appearance of primary callus in the stump area and reduce the time of hospital treatment for patients with gangrene of the lower extremities due to diabetes mellitus.

REFERENCES

- [1] Babadjanov B.D., Matmurotov K.J., Atajanov T.Sh. "Method of amputation of the lower limb in case of critical ischemia of the lower limbs" (application for invention of the Republic of Uzbekistan No. IAP 2018 0251 dated 06/06/2018).
- [2] Barbarash L. S., Zoloev G. K., Chechenin G. I. Dynamics of the number of major amputations and mortality in diseases of the arteries of the extremities in the period 1993–2008: results of a population study // *Angiology and Vascular Surgery*. -2006. -T. 16, No. 3. - P. 20–25.
- [3] Baumgartner R., Botha P. Amputation and prosthetics of the lower extremities. -M.: Medicine, 2012. -504 p.
- [4] Vachev A. N., Chernovalov D. A., Mikhailov M. S. Minor amputations in critical ischemia of the lower extremities // *Angiology and vascular surgery*. - 2010. -T. 16, No. 4. -S. 59–60.
- [5] Russian recommendations "Diagnostics and treatment of patients with diseases of peripheral arteries" - M., 2015. - 65 p.
- [6] Pokrovsky A.V. *Clinical angiology: a guide for doctors: in 2 vols.* - M.: Medicine, 2004. - 808 p.
- [7] Soroka V.V., Nokhrin S.P., Ryazanov A.N. Amputation of the lower limb in the treatment of patients with critical ischemia // *Angiology and Vascular Surgery*. - 2010. - T. 16, No. 4. - P. 329–330.
- [8] Tsarev O. A., Prokin F. G. Amputation of a limb in patients with atherosclerosis. - Saratov: Publishing house of SSMU, 2016. - 239 p.
- [9] Graziani L. et al. // *Eur J Vasc Endovasc Surg*. -2005. -№ 29. -P. 620-7.
- [10] *Standarts of Care in Diabetes*. American Diabetes Association // *Diabetes Care*. -2010. -№ 1. -P. 12-65.
- [11] Dormandy J., Rutherford R. Management of peripheral arterial disease (PAD) TASC Working group // *J. Vasc. Surg*. -2007. -№ 31. -S1- S296.
- [12] Hiatt W. Medical treatment of peripheral arterial disease and claudication // *N. Engl. J. Med*. -2001. -№ 344. -P. 1608-1621.
- [13] Regenshtien J., Ware J. McCarthy W., Zhang P, Forbes W. Heckman J, Hiatt W. Effect of cilostazol on treatment of patients with PAD // *J. Am. Geriatr. Soc*. -2002. -№ 50. -P. 1939-1946.