American Journal of Medicine and Medical Sciences 2025, 15(12): 4197-4202
DOI: 10.5923/j.ajmms.20251512.01

Comparison of Morphological and Morphometric Changes in the Thymus Following Neuroprotective Correction of Traumatic Brain Injury

Axmedova Shakhlo Malikovna

Department of Endocrinology, Bukhara State Medical Institute, 23 Gijduvan street, Bukhara, Uzbekistan

Abstract Traumatic brain injury is a leading cause of death and disability worldwide. Although many experiments have been successfully conducted in rodent models of experimental TBI, all pharmacological agents used to date have failed to improve outcomes in clinical trials. Clinical TBI is characterized by a diverse nature, biomechanics of injury, site of injury, severity, and clinical features, with individual differences. Marie Hanscom and co-authors (2021) observed strong activation of the sympathetic nervous system (SNS) after traumatic brain injury (TBI) in their study. The resulting hyperadrenergic state was systematically associated with immunomodulation in the brain. Post-TBI dysregulation enhanced inflammation, that is, secondary brain injury, which aggravated the patients' condition and, in some cases, resulted in death. The aim of this study was to assess circulating inflammatory cytokines (the early dynamic state of chemokines) in patients with moderate and severe TBI, as well as to evaluate the severity of injury and clinical indicators of neurological symptoms. The obtained experimental and clinical results indicated that inflammation is an integral component of the pathogenesis of secondary injury following traumatic brain injury.

Keywords Brain injury, Neuroprotectors, Correction, Hassal corpuscles, Thymocytes

1. Introduction

Traumatic brain injuries (TBI) are one of the leading causes of death and disability worldwide. Although numerous experiments using experimental TBI models in rodents have been successfully completed, to date, all pharmacological agents applied have failed to improve outcomes in clinical trials. The heterogeneous nature of clinical TBI — including differences in injury biomechanics, location, severity, and clinical features — is characterized by significant individual variability. Therefore, therapies capable of influencing not only a single pathophysiological mechanism but multiple mechanisms simultaneously may be the most effective in improving clinical outcomes of TBI [1,2].

According to the scientific literature, over the past decade, the understanding of the pathophysiological processes of traumatic brain injury (hypoxia, hypotension, increased intracranial pressure, and other factors that cause secondary damage to brain tissue) has significantly improved, which in turn has allowed us to base new directions on treatment. The results of modern research on the physiology and pharmacology of the nervous system have proven the need for neuroprotectors as the main treatment [4]. Magnesium-containing drugs are widely used to improve organic and functional changes in brain cells caused by various internal and external factors. One of the most common of these is magnesium sulfate. This drug is one of the most effective pharmacological agents for protecting the brain. Magnesium plays an important role in the vital activity of brain cells. Its neuroprotective effect has been demonstrated in experimental models of stroke and traumatic brain injury. Another advantage of magnesium sulfate is its pleiotropic effect. Most other neuroprotective agents affect only one pathophysiological process. The neuroprotective effect of magnesium is achieved through a number of mechanisms, including: non-selective blockade of N-methyl D-aspartate (NmDa) receptors, reduction of presynaptic excitatory neurotransmitter release, and blockade of calcium channels associated with inhibition and amplification of depolarizing waves in the cerebral hemispheres. Magnesium sulfate helps reduce intracranial pressure. It is also widely used in traumatic brain injury, subarachnoid hemorrhage, ischemic stroke, eclampsia and preeclampsia, hypoxia of the central nervous system, and central paralysis [5,6].

It is noted that in cases of traumatic brain injury, along with neuroprotectors, nootropic drugs should be used. Piracetam is used as the most effective means for this. In addition to the nootropic effect, piracetam also has antihypoxic, neuroprotective, antixiolytic, antidepressant and analgesic

* Corresponding author:
axmedova.shahlo@bsmi.uz (Axmedova Shakhlo Malikovna)
Received: Aug. 4, 2025; Accepted: Sep. 2, 2025; Published: Dec. 1, 2025
Published online at http://journal.sapub.org/ajmms

effects. Data on the nootropic activity of piracetam have been studied in detail. It has been studied in rodents using various methods (passive conditioned reflex (PCR), active conditioned reflex (ACR) and maze methods). They have been confirmed by many years of clinical practice. It is noted that the drug has an effective effect with long-term use in high doses. However, the positive effect of the drug occurs when taking courses of treatment in small doses [3].

Disability in BMS is associated with primary brain damage and the formation of dysregulation mechanisms and a decrease in adaptive reserves over a long period of time and during the consequences of new clinical syndromes. Therefore, effective neuroprotection requires the use of a complex combination of drugs that act on different links in the chain of pathophysiological processes that develop after traumatic brain injury. Among the evidence-based medical research materials, one of the drugs with proven high medical efficacy is Ceraxon. Its active ingredient, citicoline, is a precursor of phosphatidylcholine (lecithin), which is the main component of neuronal membranes [7,22].

The bioavailability of citicoline for the body is close to 100%. This allows the drug to be administered orally and parenterally. The instructions for use of the drug indicate the following indications for use: acute cerebral edema after acute brain injury and intracranial hypertension in patients with acute stroke. This indicates the absence of side effects in the clinical use of the drug. According to the results of the authors' research, citicoline has shown a number of positive results in hemorrhagic stroke, traumatic brain injury of varying degrees, and in elderly patients with cognitive disorders of vascular and neurodegenerative genesis [8,9].

In experimental studies of local ischemia in rats, the following were found when using long-term citicoline as a therapeutic therapy. It was found that this drug promotes functional recovery of neurons and increases the plasticity of neurons at the border of uninjured brain matter. The analysis of the results of using citicoline in patients with brain injury made it possible to develop an optimal dose selection taking into account the severity of the disease [8]: in mild cases - in the first stage, 500-1000 mg intravenously per day for 5-6 weeks, in the second stage, 600-900 mg orally per day for 3-5 days; in moderate cases - in the first stage, 1500-2000 mg intravenously per day drip for 5-7 days, in the second stage, 900-1200 mg orally per day for 1.5-2 months; in severe head injury - in the first stage, from the day of injury, it is administered intravenously at a dose of 2000 mg/day for 10-14 days, then in the second stage, it is recommended to administer orally (through a gastric tube) at a dose of 1200-2000 mg/day for 2-3 months. Taking into account the proven safety and efficacy of the drug, it is confirmed that citicoline is a reliable drug that should be included in the list of neuroprotective drugs at the first signs of brain injury. The availability of oral and parenteral forms of citicoline makes it convenient for use in all categories of outpatients and inpatients [10,11,12,21].

Severe traumatic brain injuries can lead to disability and, in some cases, death. 10-15% of deaths occur as a primary complication, while the remaining percentage is due to complications associated with secondary brain damage. In developed countries, injuries are the second leading cause of death after cardiovascular and oncological diseases, and in terms of total economic and socio-economic damage (temporary disability, disability and death), traumatic brain injury is the leading cause of death in a number of countries, as it is more common in young and middle-aged people. Although 0.2% of the total number of injured patients die, this figure increases with the severity of the injury. 90% of victims are admitted with mild TBI, and mortality is almost non-existent. The mortality rate in patients with moderate BMJ is from 5% to 20%, and the mortality rate in severe BMJ (this diagnosis is made by less than 10% of victims), according to different authors, reaches 38-80% [10,13,14].

In conclusion, the thymus plays an important role in the development and functioning of the immune system, especially in the early stages of human life. Its condition and response to brain injury can significantly affect the recovery processes and the general condition of the body [8,13,16]. The results of the analysis of the scientific literature show that the morphometric, morphofunctional and immunohistochemical changes in the thymus in different degrees of brain injury, i.e. mild, moderate and severe, have not been sufficiently identified. There is also practically no scientifically substantiated data on modeling brain injury in laboratory animals. This situation requires a detailed study of the morphometric parameters of thymic tissue and the changes that may occur in the thymus in brain injury [14].

Following neuroprotective correction of brain injuries, the thymus exhibited near-normal shape, coloration, and capsule luster. That is, for pharmacological correction, L-lysine aescinate (1 mg/mL) was administered intramuscularly at a dose of 5 mL, and citicoline (125 mg/mL) was administered intramuscularly at a dose of 4 mL for 10 consecutive days. A comparative analysis of morphometric parameters was conducted between animal groups with brain injury and control groups using the "road accident" model. The obtained results were statistically analyzed and described. The findings of the study were documented in a formal report. The following results were obtained when studying the organometric indices of the thymus in 3-month-old white rats after correction of brain injuries with neuroprotectors [18,19,20].

2. Materials and Methods

The dissertation work was carried out in the research laboratory of the Abu Ali Ibn Sino Bukhara State Medical Institute from 2022 to 2024. Based on the results of the morphometric study of thymus parameters under the influence of traumatic brain injury, an algorithm for providing emergency care to patients with traumatic brain injury is developed, taking into account the periods of emergency situations. A method for calculating the prognosis of the condition of patients with traumatic brain injury, taking into account the periods of traumatic brain injury, is determined.

When working with laboratory animals, all biological safety rules and ethical principles for working with laboratory animals given in the methodological manual by Nuraliev N.A., Bektimirova A.M., Alimova M.T., Suvanov K.J. were followed. “Rules and methods of working with laboratory animals in microbiological and immunological research”, approved by the resolution of the Ministry of Health of the Republic of Uzbekistan dated May 25, 2016 (8n-p89), and the information letter of Nuraliev N.A., Suvonov K.J., Khamrakulova M.A. “Ethical principles of working with laboratory animals”, registered by the ONMI of the Ministry of Health of the Republic of Uzbekistan on June 6, 2016 (№0438).

For the purpose of experimental studies, 186 three-month -old white non-breed rats of both sexes, kept in ordinary vivarium conditions, were used. All laboratory animals were kept in plastic cages with wood shavings in the vivarium, at standard room temperature, with a 12-hour light-dark cycle, in accordance with the standards for keeping laboratory animals. All rats were kept in quarantine for one week, after which all animals were visually inspected to ensure that there were no somatic or infectious diseases. After ruling out any disease-specific pathology in the rats, they were transferred to their usual vivarium conditions.

The following groups were formed to determine the morphological and morphometric indicators of the thymus structure at different levels of severity of brain injury.

According to this table, Group I (n=30) served as the control group and consisted of healthy 3-month-old rats.

Group II was the experimental group and included the following subgroups:

- **Group IIA** – consisted of 30 adult, 3-month-old white outbred rats. Morphological changes that occurred after mild traumatic brain injury were studied in this group.
- **Group IIB** – consisted of 39 adult, 3-month-old white outbred rats. Morphological changes following moderate traumatic brain injury were studied; among them, 3 rats died.
- **Group IIC** – consisted of 42 adult, 3-month-old white outbred rats. Morphological changes following severe traumatic brain injury were studied; among them, 3 rats died.

Group III was the group subjected to *correction with neuroprotectors*:

- **Group IIIA** – consisted of 15 white outbred 80-day-old rats. Morphological changes after 10 days of neuroprotective correction following mild traumatic brain injury were studied.
- **Group IIIB** – consisted of 15 white outbred 80-day-old rats. Morphological changes after neuroprotective correction following moderate traumatic brain injury were studied.
- **Group IIIC** – consisted of 15 white outbred 80-day-old rats. Morphological changes after 10 days of neuroprotective correction following severe traumatic brain injury were studied.

During the experiment, a total of 111 animals were subjected to mild, moderate, and severe traumatic brain injuries. Among them, 3 rats died after moderate traumatic brain injury, and another 3 rats died after severe traumatic brain injury. Thus, out of 111 injured rats, a total of 6 animals died.

After inflicting the injury, the animals were placed in special plastic cages and monitored until recovery. During the experiment, some rats exhibited asphyxia, seizures, and bleeding. After 25–30 minutes post-injury, the surviving animals were returned to their cages to resume normal activity.

In the **second stage of the study**, a total of 45 rats that had sustained mild, moderate, and severe traumatic brain injuries underwent correction using neuroprotective drugs. Subsequently, the rats from the control group were compared with those that received neuroprotective treatment following traumatic brain injury. Observations were made on the dynamics of body weight, general condition, and behavioral activity of the animals. Deviations in their general state and behavior were identified, and the results were comparatively analyzed.

In the **third stage of the study**, the experimental group of 3-month-old white outbred rats with mild, moderate, and severe traumatic brain injuries were examined for morphological changes in the thymus tissue using an immunohistochemical method. Microscopic preparations made from the extracted thymus tissue were examined using the CD68 immunohistochemical marker, and the results were obtained based on the level of expression of this marker.

After neuroprotective correction of traumatic brain injury, it was found that the general shape and color of the thymus, as well as the luster of its capsule, approached normal condition. For pharmacological correction, **L-lysine aescinate** (1 mg/mL) was administered intramuscularly in a dose of 5 mL, and **citicoline solution** (4 mL, 125 mg/mL) was injected intramuscularly for 10 consecutive days.

Table 1. Distribution of animals depending on the content of the experiment

Monitoring groups	Number of rats			**Total**
I - Number of rats in the control group	30 yes			30
II - Number of rats in the experimental group	A. Mild brain injury (n=30)	B. Moderate brain injury (n=39) (3)*	C. Severe head injury (n=42) (3)*	111 (6)*
III - Neuroprotective correction	A. Neuroprotectors. Mild traumatic brain injury (n=15)	B. Neuroprotectors. Moderate traumatic brain injury (n=15)	C. Neuroprotectors. Severe traumatic brain injury (n=15)	45

A comparative morphometric analysis was carried out between the groups of animals subjected to traumatic brain injury using the "road traffic accident" model and the control groups. The obtained results were statistically processed and described in a report format.

The mass and volume of the organ increased compared to the untreated traumatic brain injury group, indicating recovery of thymus function.

3. Results

According to the morphometric analysis after neuroprotective correction of traumatic brain injury in 3-month-old white outbred rats, the body weight ranged from 179.79 g to 238.21 g, with a mean of 209 ± 29.21 g. The mean thymus weight was 179.01 ± 2.64 mg, relative weight — 1.12 ± 0.06 mg, length — 12.8 ± 2.21 mm, width — 7 ± 0.56 mm, thickness — 3.5 ± 0.11 mm, and thymus volume — 345.7 ± 44.67 mm³. These values were obtained based on the morphometric analysis results.

Table 2. Organometric indicators of the thymus in 3-month-old white inbred rats following neuroprotective correction of head injuries

orgonometric indicators	M±σ
Rat weight, g	209±29,21 g
Thymus weight, mg	179,01±2,64 mg
Relative weight, mg	1,12±0,06 mg
Thymus length, mm	12,8±2,21 mm
Thymus gland, mm	7±0,56 mm
Thymus thickness, mm	3,5±0,11 mm
Thymus volume, mm^3	345,7±44,67 mm^3

Note: * - indicates a significant difference between the arithmetic mean values compared to the control group (*** - p<0.05; ** - p<0.01; * - p<0.001).

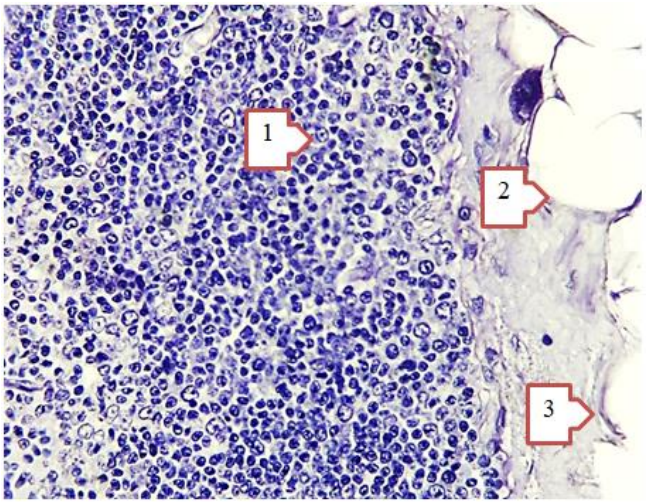

Figure 1. Morphological changes in the thymus after treatment of traumatic brain injury with neuroprotectors. Hematoxylin-eosin staining; magnification ×400. The thymus tissue shows: (1) adipocytes, (2) a cortical layer of lymphoid cells (thymocytes), and (3) a collagenous connective tissue barrier

The organ mass and volume increased compared to the untreated group, indicating restoration of thymus function. Analysis of morphometric parameters after neuroprotective correction of brain injuries showed that the body weight of 3-month-old white non-breeding rats ranged from 179.79 g to 238.21 g, with an average of 209 ± 29.21 g. The average thymus weight was 179.01 ± 2.64 mg, with a relative density of 1.12 ± 0.06 mg. The thymus dimensions were as follows: length 12.8 ± 2.21 mm, width 7 ± 0.56 mm, thickness 3.5 ± 0.11 mm, and volume 345.7 ± 44.67 mm³.

Microscopically, the thickness of the capsule and trabeculae was normalized, and the amount of connective tissue components (collagen) was reduced. Lymphoid tissue regeneration improved, and the boundary between the cortex and medulla became more distinct (Figure 1).

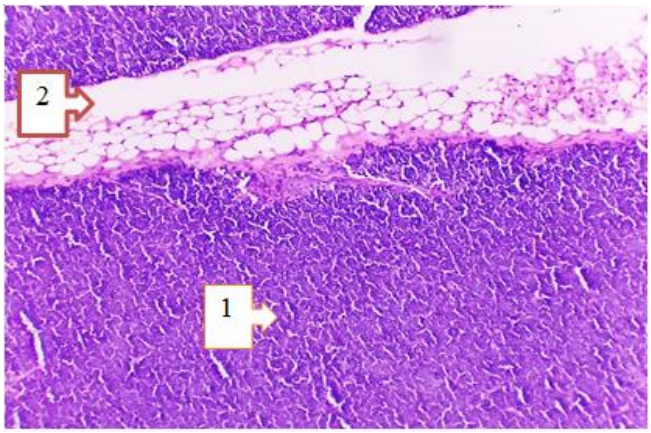

Figure 2. Morphological changes in the thymus after treatment of traumatic brain injury with neuroprotectors. Hematoxylin-eosin staining; magnification ×400. Thymic epithelial cells (1) and areas of fatty metamorphosis (2) are visible

When the ratio of thymic tissue structures in the control group was analyzed in percentages, the average value of the thymus cortex was 56.7 ± 2.89%, ranging from 53.81% to 59.59%. The average proportion of the medulla was 27.79 ± 2.46%, with a minimum of 25.33% and a maximum of 30.25%. The average cortex-to-medulla ratio was 1.88 ± 0.45, with values ranging from 1.43 to 2.33. The average proportion of stromal tissue in the organ was 10.72 ± 2.6%.

Table 3. Thymic tissue section area (%) in 3-month-old white outbred rats after neuroprotective correction of TBI

Structural parts of the thymus	Tissue section area (%)		
	M±σ	Min	Max
Cortical layer"	56,7±2,89	53,81	59,59
Medullary layer	27,79±2,46	25,33	30,25
Cortex-to-medulla ratio	1,88±0,45	1,43	2,33
Organ stroma ratio	10,72±2,6	8,12	13,32

Note: * — compared to the control group (***p<0.05; **p<0.01; *p<0.001); significant difference between mean values.

4. Discussion

The results of our study indicate that neuroprotective correction after traumatic brain injury (TBI) contributes to

the restoration of thymic structure and function. Morphological observations showed that after the administration of neuroprotective agents, the general shape, color, and capsule brightness of the thymus approached normal. This finding suggests improvement in the organ's trophic state and blood circulation.

The use of **L-lysine aescinate** and **citicoline** had a significant effect on the recovery processes in experimental animals. These drugs possess anti-exudative, antioxidant, and neuroregenerative properties that reduce cellular hypoxia and improve metabolic activity in nervous tissue. As a result, the stress response associated with brain injury was alleviated, and gradual normalization of thymic morphology was observed.

Morphometric data revealed an increase in thymus mass and volume compared to the untreated TBI group, indicating activation of thymic function and partial restoration of immune activity. The increase in relative thymus weight and its structural parameters (length, width, and thickness) reflects enhanced proliferative activity and a reduction in atrophic changes. These findings are consistent with previous data showing a close relationship between the integrity of the central nervous system and the condition of immune organs.

Furthermore, the positive changes observed in the general state and behavior of animals after neuroprotective therapy confirm the overall systemic effect of the applied treatment method. Stabilization of body weight and normalization of behavioral responses demonstrate that neuroprotective correction not only alleviates the severity of brain injury but also reduces secondary immunological disturbances.

In general, the combined use of **L-lysine aescinate** and **citicoline** exhibits a clearly defined neuroprotective and immunomodulatory effect, contributing to the recovery of both neural and thymic structures after traumatic brain injury.

5. Conclusions

Following neuroprotective therapy, a significant recovery of the morphological and morphometric parameters of the thymus was observed. In particular, in treated animals compared to the severe BMD group, thymus weight increased by 38.2% and volume by 41.3% ($p < 0.05$). The proportion of the cortex increased to $56.7 \pm 2.89\%$, the medulla to $27.79 \pm 2.46\%$, and the cortex-to-medulla ratio was restored to 1.88 ± 0.45. The proportion of stromal tissue decreased to $10.72 \pm 2.6\%$, indicating a reduction in fibrillar components and collagen.

Histological analysis revealed normalization in the shape and localization of Hassall's corpuscles, increased lymphoid cell density, reduced capillary permeability, maintenance of mucopolysaccharide levels within the normal range, and elimination of hypersecretion. These findings suggest that neuroprotective therapy effectively reduces stress-induced thymic involution and promotes the restoration of immune architecture.

Proliferation of thymocytes and a reduction in the rate of fatty metamorphosis were observed. Focal proliferation of T-lymphocytes was noted in the subcapsular region of the cortex, along with the formation of immature prethymocytes actively dividing by mitosis. Enlargement of the nuclei in thymic epithelial (reticuloepithelial) cells—also undergoing mitotic division—further indicated active cellular regeneration.

Additionally, a reduction in stromal edema was observed. These findings suggest a partial reversal of degeneration in the reticuloepithelial cells and restoration of both T-lymphocyte and epithelial cell function. Such regenerative processes support the production of biologically active substances and reflect the thymus's role in the endocrine regulation of the body.

REFERENCES

[1] Amcheslavsky V.G., Generalov V.O., Amcheslavskaya E.V. // Neuroprotective therapy for traumatic brain injury // Medical business No. 4.2020, 114-121 p.

[2] Avedisova A.S., Akhapkin R.V., Akhapkina V.I., Verigo N.N. Piracetam in the light of modern research (analysis of foreign studies) // Psychiatry and psychopharmacotherapy. – 2000.

[3] Akhmedova Sh M 2022 Morphometric changes in age-related signs of the thymus Special Issue: Applying Foreign Experience In Distance Education To The Education System-Issn: 2181-2594.

[4] Belyaevsky A.D., Lebedeva E.A., Belousova M.E. // Cytokines, oxidative stress and antioxidant protection in isolated and combined traumatic brain injury // General Reanimatology, 2009, V; 6, 36-39 p.

[5] Viktor Alekseyevich Chetvertnix., Yuriy Ivanovich Kravsov., Kirill Vladimirovich Shevchenko, //Izmeneniya immunnogo statusa u postradavshix v ostrom periode cherepno-mozgovoy travmi // Kazanskiy Meditsinskiy Jurnal, 2009 g., Tom 90, № 5, 663-667 s.

[6] Volkov Vladimir Petrovich // Functional Immunomorphology of the thymus during antipsychotic therapy // Innovations in science No. 9 (46), 2015, 109-115 p.

[7] Gao W, Kim MW, Dykstra T, Du S, Boskovic P, Lichti CF, Ruiz-Cardozo MA, Gu X, Weizman Shapira T, Rustenhoven J, Molina C, Smirnov I, Merbl Y, Ray WZ, Kipnis J. Engineered T cell therapy for central nervous system injury. Nature. 2024 Oct; 634(8034) p.

[8] Di Battista AP, Rhind SG, Hutchison MG, Hassan S, Shiu MY, Inaba K, Topolovec-Vranic J, Neto AC, Rizoli SB, Baker AJ. Inflammatory cytokine and chemokine profiles are associated with patient outcome and the hyperadrenergic state following acute brain injury. J Neuroinflammation. 2016 Feb 16; 13: 40 p.

[9] Dyukarev V.V., Yudina S.M., Kravchuk A.D. // The state of innate immunity factors in patients with severe traumatic brain injury // Kursk Scientific and Practical Bulletin "Man and His Health". - 2019. - No. 1., 70-76 p.

[10] Saver J.L. Citicoline: update on a promising and widely

available agent for neuroprotection and neurorepair // Rev. Neurol. Dis. 2008. V. 5. № 4. P. 167–177.

[11] Israilov R.I., Isaev G.E., Sadikova Sh. // Morphological characteristics of Hassall's bodies of the thymus in normal conditions and in sepsis in children //Problems of Biology and Medicine 4 (67) 2011, 37-39 p.

[12] Corps KN, Roth TL, McGavern DB. Inflammation and neuroprotection in traumatic brain injury. JAMA Neurol. 2015 Mar;72(3): 355-62 p.

[13] Ritzel RM, Doran SJ, Barrett JP, Henry RJ, Ma EL, Faden AI, Loane DJ. Chronic Alterations in Systemic Immune Function after Traumatic Brain Injury. J Neurotrauma. 2018 Jul 1; 35(13): 1419-1436 p.

[14] Kalinina N.M Trauma: inflammation and immunity, Kalinina N M, Sosyukin A E and Vologyanin D.A 2005 Cytokines and inflammation. Vol. 4, No. 1. - P. pp 28-35.

[15] Kuzmenko L G, Kiseleva N M and Simonova A.V 2013 Training in the thymus. Journal nauchnyx statey Zdorove i obrazovanie v XXI veke.; 15 (1-4): pp 170-175.

[16] Russkiy (Kuzmenko L G, Kiseleva N M and Simonova A.V 2013 Starenie i timus. Jurnal nauchnyx sostoyaniy zdorovya i obrazovaniya v XXI veke T. 15, № 1-4. P. pp 170-175.

[17] Kurz. C.// The metabolic enhancer piracetam ameliorates the impairment of mitochondrial function and neurite outgrowth induced by ß-amyloid peptide [Tekst] / C. Kurz, I. Ungerer, U. Lipka, S. Kirr, T. Schütt, A. Eckert, K. Leuner, W.E. Müller // British Journal of Pharmacology. – 2010. – Vol. 160, № 2. – P. 246-257.

[18] Kabanov A.A. // Neyroproteksiya pri travmax sentralnoy nervnoy sistemi. // Lechebnoye delo-2011. №1. - S. 59-68.

[19] Marie Hanscom., David J., Loane., Taryn Aubretch., Jenna Leser., Kara Molesworth., Nivedita Hedgekar., Rodney M., Ritze., Gelareh Abulwerdi., Terez Shea-Donohue and Alan Faden. // Acute colitis during chronic experimental traumatic brain injury in mice induces dysautonomia and persistent extraintestinal, systemic, and Cns inflammation with exacerbated Neurological deficits // Hanscom et al. Journal of neuroinflammation (2021) 18: 241-31p.

[20] Ponomareva YE.N., Smichyok V.B. // Lecheniye bolnix, perenesshix cherepno-mozgovuyu travmu // Meditsinskiye Novosti № 7-2014, 4-16 s.

[21] Torxovskaya T.I., Belova O.V., Zimina I.V., Kryuchkova A.V., Moskvina S.N., Bistrova O.V., Arion V.Y., Sergiyenko V.I. // Neyropeptidi, Sitokini i timicheskiye peptidi kak effektori vzaimodeystviya timusa i neyroendokrinnoy sistemi // VESTNIK RAMN /2015/ 70 (6), 727-733 s.

[22] Yang W, Liu Y, Liu B, Tan H, Lu H, Wang H, Yan H. Treatment of surgical brain injury by immune tolerance induced by intrathymic and hepatic portal vein injection of brain antigens. Sci Rep. 2016 Aug 24; 6 -10 p.

Copyright © 2025 The Author(s). Published by Scientific & Academic Publishing
This work is licensed under the Creative Commons Attribution International License (CC BY). http://creativecommons.org/licenses/by/4.0/