

# Correction of Complications After Liver Echinococcatomy Using Minimally Invasive Interventions

Botirov A. K., Turgunboev A. A., Otakuziev A. Z., Botirov J. A.

Andijan State Medical Institute, Andijan, Uzbekistan

**Abstract** To date, significant experience in the surgical treatment of echinococcosis has been accumulated throughout the world, but the 21st century was marked by the fact that at the annual meetings of the WHO, the problem of echinococcosis is not off the agenda, including those related to surgical aspects [1,2,3,4]. The authors, in the course of the study, conclude that the developed diagnostic and treatment measures using ultrasound and fistulography make it possible to establish a diagnosis in the shortest possible time and select the optimal method of treating LE. Laparoscopic sanitation and ultrasound-guided puncture and drainage interventions in the treatment of complicated LE after EE can now find wider clinical application. You should refrain from this technique only in the presence of multilocularity and massive hyperechoic inclusions (sequestra). In other clinical situations, puncture-drainage intervention may be considered the method of choice.

**Keywords** Hydatid echinococcosis of the liver, Residual cavity, Laparoscopic sanitation, Puncture and drainage interventions

## 1. Introduction

To date, significant experience has been accumulated throughout the world in the surgical treatment of echinococcosis, however, there are still no clear recommendations and guidelines regulating the scope of surgical intervention in a given clinical situation, and the issues of anti-scolecidal treatment of the residual cavity (RC) and ways of prevention have not been fully studied complications of liver echinococcosis (LE) [3,6,9]. This is due to the increasing migration of the population, the deterioration of the epidemiological situation, and the low level of medical examination of the population [7,8,10].

The 21st century was marked by the fact that at the annual meetings of the WHO, the problem of echinococcosis is not off the agenda, including those related to surgical aspects [1,2,3,4,5]. In this regard, in this work, an attempt was made to improve the results of surgical treatment of LE and its complications by developing an algorithm of actions when choosing the method of primary and repeated surgical intervention, as well as further improving ways to prevent complications.

**The aim of the research** is to improve the results of treatment of hydatid echinococcosis of the liver (LE) by developing a treatment and diagnostic algorithm, as well as a differentiated approach to the development of complications.

## 2. Material and Research Methods

The dissertation is based on the results of treatment of 217 patients with LE and its complications, who are conditionally divided into 2 groups:

- comparison group - 124 (57.2%) patients with hydatid LE, for the period from 2016 to 2019. (before applying the developed methods).
- main group - 93 (42.8%) patients with hydatid LE, for the period from 2020 to 2023 (prospective part of the study).

The average age was 40.5 years, with a female to male ratio of 2:1 (58.9 - 41.1% and 38.8 - 61.2%).

All patients were distributed by age according to the International Age Classification, WHO [5]. The age limit ranged from 19 to 78 years, with a female to male ratio of 2:1.

The complex of diagnostic research methods used: ultrasound, X-ray and CT examinations, as well as immunological studies, which made it possible to diagnose LE, establish localization, determine the number and size of cysts and choose rational surgical treatment tactics.

The statistical significance of the data collected from the study was examined using Epi Info, R commander and Microsoft Excel 2021 office suite.

## 3. Results and Its Discussion

When conducting ultrasound monitoring of the condition of the residual cavity (RC) after echinococcatomy (EE) of

the liver, our goal was to study the dynamics of the processes occurring in the RC after various types of operations and compare the results obtained with the methods of surgical correction. Also of scientific and practical interest is the establishment of a correlation between the clinical manifestations of RC suppuration and ultrasound data, which will allow timely therapeutic measures to be taken without bringing the process to true suppuration.

21 (9.7%) patients were under observation for complicated RC after liver EE, of which 18 (14.5%) were in the comparison group, 3 (3.2%) were in the main group.

The frequency of RC suppurations from the total number of patients with RC complications was 3.7% (8 patients), the presence of fluid was 5.9% (3 patients). Moreover, in the comparison group, complications of RC in the form of suppuration amounted to 6.4% (8 patients); in the main group, RC suppuration was not observed in any case. Fluid accumulation was 8.1% (10 patients) and 3.2% (3 patients). From the analysis of medical records in the comparison group, 16 (12.9%) patients with complicated residual surgery for LE were completed with external drainage of the cyst cavity, only in 2 (1.6%) the operation was completed with closed EE.

In the main group, 3 (3.2%) patients with complicated RC were operated on using a combined EE method with drainage using one drainage tube.

In the comparison group, 2 patients began to experience small RCs up to 1.5 cm in diameter on the 4th day. On the 5th day, the sizes of the cavities reached 3.5 and 5 cm in diameter, respectively, with liquid heterogeneous contents. In the long-term period, during dynamic ultrasound, fluid accumulation in the RC (2.5 cm) was observed at 5 months after surgery, in which no pathological accumulations in the RC were observed during ultrasound on the 2nd and 3rd days. At the 6th month, the diameter of the formation increased to 4.5 cm.

We see that dynamic correction of drainages located in the RC is the most important method of preventive treatment and prophylactic measures in diagnosing signs of RC formation and infection. Our experience has shown that drains with a diameter of less than 1 cm were often used, which did not provide sufficient outflow of contents. In addition, with a reduction in the volume of RC, as well as with abdominal excursion, mixing of drainages is often observed. In this regard, we fixed the drainage with catgut thread by stitching one of its edges to the bottom of the cavity. Catgut is used 2/0 - 3/0. A drain with an internal diameter of at least 1 cm has 3-4 side holes. Next, we fix it at the outer edge of the fibrous capsule and stitch it to the skin of the anterior abdominal wall.

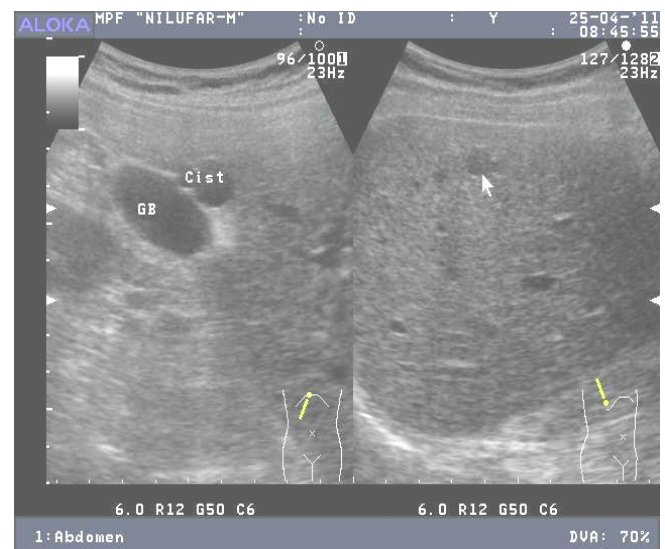
By the time the drainage is removed on days 5-6, the catgut relaxes and the drainage is evacuated without any difficulty. In a similar way, we have already fixed drains in patients of the main group. Only 1 (1.1%) of them had mixed drains and prolapsed. Patients with RC after liver EE were characterized by a polymorphism of clinical manifestations - from a latent and asymptomatic course to the appearance of hepatomegaly. The absence of any clinical symptoms

occurred in 5 (11.6%) patients; in the rest, pain, a feeling of heaviness in the upper abdomen or discomfort after eating were common. The nature of the pain and its localization depended on the size of the RC and concomitant lesions of the hepatopancreatoduodenal zone. Thus, in patients with small cavity sizes, the pain was periodic, moderately aching and localized equally often both in the right hypochondrium and in the epigastric region; in patients with large RC, the pain was constant, dull and localized mainly in the liver and right hypochondrium.

The second characteristic symptom of RC after pain after EE of the liver is more or less pronounced hyperthermia with signs of intoxication of the body.

Diagnosis of RC complications after liver EE included: detection of RC and its differentiation; establishing its size, prevalence and segmental localization; establishing a connection between the RC and the intrahepatic bile ducts; assessment of the nature of the content of the RC; choosing a treatment method or eliminating the need for it. After EE, dynamic ultrasound is performed from the next day. The liver was examined in both transverse, oblique, and direct directions. To capture the image, if necessary, a Polaroid photo attachment was used.

Adhering to this tactic, it was possible to identify a number of characteristic sonographic signs complicated by RC and their relationship with clinical symptoms. During dynamic ultrasound of operated patients, a cavity with fluid accumulation was identified. Differential diagnosis from hydatid cysts was characterized by the presence of a double contour of liver formation. This sign in 100% of cases indicates the parasitic nature of the cyst.



**Figure 1.** Patient M. History No. 624/252. On the projection of the 7th segment, 10 x 10 x 12 mm, irregular oval shape, smooth, clear contours, have a thin capsule of 1 mm, contain liquid, the formation is in contact with the body of the gallbladder

RC was characterized by uneven contours that had scalloped or folded outlines. At the same time, the ultrasound picture of RC and parasitic cyst differed significantly: for example, in the presence of EC disease, a smooth contour,

a thin capsule and liquid, round formations inside the cavity were significantly more often detected. In the presence of RC, an uneven contour of the lesion and echogenic consolidation of pericystic tissue were more often observed (Fig. 1).

The shape of RC gradually approached slit-like or triangular, in contrast to the round configuration characteristic of EC.

In doubtful cases, dynamic monitoring was continued. The dynamics of the size and localization of the formation allowed us to draw a final conclusion about its nature. During dynamic ultrasound, the size of liver RC varied from 15 to 100 mm or more, but most often residual cavities were diagnosed from 20 to 60 mm in diameter - 26 patients or 60.5%.

Diagnosis of RC in these patients was also based on fistulography data in 4. This tactic allowed us to minimize the number of postoperative complications from RC.

We operated on 79 (63.7%) patients for uncomplicated hydatid LE and 48 (51.6) patients in whom RC formation and infection occurred in the postoperative period.

In 8 cases, semi-closed versions of EE were performed, and only in one observation was closed EE performed. The open version of the operation is usually performed forcedly.

Closed EE was performed in 1 patient, who underwent closed EE; the cyst was located in the 4th segment. Its diameter was 8 cm.

On the 5th day, in the evenings the temperature began to rise to 37.5 - 38 °C. Ultrasound data already on the 2nd day revealed the presence of RC up to 2 cm in diameter. On days 4-5, the RC began to have clearer contours. In its cavity, fluid was clearly visible.

We observed fluid accumulation in the RC after semi-closed EE by tamponade of the fibrous cavity with a strand of omentum. In addition to filling the fibrous cavity with an omentum, a vinyl chloride drainage was introduced into it, which was installed to the bottom of the cavity and fixed to the fibrous capsule and to the skin of the patient's anterior abdominal wall. Only on the 6th - 7th day small cavity formations (1.5 - 2 cm) began to be visualized. On the 9th day, the sizes of the cavities reached 3.5 and 5 cm, respectively. The same period also coincided with the appearance of insignificant, up to 3.5 ml, discharge from the drainage, which was cloudy and odorless.

In order to study its nature, bacteriological studies were carried out. As a result of the latter, the following strains of bacteria were identified: *Escherichia coli*. *Staphylococcus aureus*. Clinical signs of the formation and infection of residual cavities first appeared with a typical clinical picture only on the 11th - 12th day after the operation. A semi-closed EE was performed by suturing the fibrous cavity from the inside. The first three days of the early postoperative period were unremarkable. On the 4th day, it was discovered that the drainage did not reach the bottom of the sutured cavity by about 3 cm and there was a level of turbid liquid at the bottom. Having cut off the skin thread fixing it, the drainage was moved to the bottom of the wound, re-fixed and active aspiration of the contents was established.

Thus, after EE from the liver for hydatid echinococcosis,

dynamic ultrasound allows us to timely identify early signs of the formation and infection of RC, as well as carry out the necessary therapeutic measures. At the same time, sonographic signs of RC suppuration precede the appearance of clinical manifestations by an average of 4-5 days.

Those operated on for hydatid LE complicated by suppuration were 23 (18.6%) and 21 (22.5%), respectively. In 3 cases, with suppurating ECs and their localization in 6-7 segments of the liver, open ECs were performed, leaving two drains in the cavity. 6 have semi-closed EEs with one drainage left in the RC. In 3 of them, according to ultrasound data, signs of inadequate drainage appeared already on the 2nd - 3rd day after surgery.

Dynamic sonographic observation revealed that from the 3rd to 4th day after surgery, non-drainable fluid remained at the bottom of the cavity, where the cause in 2 patients was biliary fistulas. The priority of ultrasound in detecting infection and suppuration of RC was not as obvious as in the previous group. According to ultrasound data, on the 4th - 6th day after surgery, a stable level of fluid appeared at the bottom of the RC and a non-functioning drainage occurred.

The open version of EE was used in only 3 patients. This is due to the absence of a sufficiently pronounced omentum and the fact that the screwing in of the edges of the fibrous capsule deformed the lobar bile ducts, which was diagnosed by intraoperative cholangiography.

In 17 (13.7%) patients in the comparison group, the failure of the measures taken was an indication for relaparotomy and drainage of cavities. Only 1 (0.8%) of them underwent PAIR-PD. In the main group, laparoscopic RC sanitation and drainage were performed in 3 (3.2%) cases, and PAIR-PD in 3 (3.2%) cases.

**Treatment of complications of residual cavity.** The main cause of specific complications after traditional methods of EE (combined and open) was the leaving of a dense, calcified fibrous capsule, bearing bile fistulas in its thickness. RC in the presence of such a fibrous capsule cannot be reduced. With closed EE, the applied sutures, as a rule, erupted and formed cavities where bile accumulated from the puncture sites, which contributed to the formation of cystobiliary fistulas, beads and their subsequent suppuration.

With a dead parasite and complicated echinococcosis, due to the destruction of the cuticular membrane and partially fibrous capsule, conditions were created for the pathogen to penetrate beyond the hydatid into the tissue of the host organ. Under these conditions, traditional EE methods, even with removal of the fibrous capsule, did not provide radical treatment in all cases. Thus, a significant number of postoperative purulent-inflammatory complications from RC after traditional EE methods dictated the need to expand the indications for minimally invasive interventions.

Endovideosurgical interventions allow us to consider it a promising direction in surgery for echinococcosis, but not as an alternative to traditional ones. Transfistula endovideoscopy of the RC liver was used in the treatment of 3 patients with functioning drainage of the RC liver due to the formation of external purulent-biliary fistulas, where in

this case coagulation of the cystobiliary fistula was performed.

All 38 patients underwent puncture treatment. The indication was the presence of signs of the presence of infected liquid contents during dynamic ultrasound and the addition of the clinical picture of RC suppuration. An RC diameter of up to 7 cm was noted in 1 patient, a dense mass measuring 4-7 cm in 2 patients, and a homogeneous formation up to 5 cm in 4 patients.

For RC with a diameter of more than 40 mm, we performed puncture and drainage treatment under ultrasound control. It included the following: choosing the trajectory for advancing the puncture needle; inserting a puncture needle into the cavity formation; passing the conductor into the cavity formation; inserting a drainage tube (catheter) into the cavity; aspiration of the contents of cavity formation, medicinal effects, sclerotherapy; removing the drainage tube (catheter).

The puncture-drainage method was carried out in an operating room equipped with Aloka SSD 260 ultrasound equipment and an X-ray television installation from FISCHER IMAGING corporation (Germany).

**Methodology:** The procedure was performed under local anesthesia after premedication with non-narcotic analgesics. Indications for puncture treatment were signs of intoxication, hyperthermia and the presence of a liquid formation more than 35 mm in diameter.

When performing RC puncture, while passing the needle through the tissue, we controlled the trajectory of the needle tip along the dotted line on the monitor screen by turning on the Puncture function.

The location of the puncture was determined individually. However, when hydatid echinococcosis is localized in the right lobe of the liver, the most common place is the 7-8 intercostal space along the axillary midclavicular line, and when localized in the left lobe, the area is approximately 3 cm below the edge of the xiphoid process. Then, under dynamic ultrasound control, puncture is performed with a No. 18 Chiba needle. Under the control of an X-ray machine,

contrast is injected through a puncture needle, which makes it possible to clarify the size, shape and internal structure of the hydatid cyst. A guidewire is inserted into the RC through the lumen of the needle, followed by its expansion with dilators No. 9 and then No. 10.

After removal of dilator No. 9, a pig-tail drainage tube No. 16F is installed along the internal lumen of dilator No. 10 in the RC. After dilatation, the dilator is removed and the drainage tube is fixed to the skin. The entire procedure is carried out under dynamic ultrasound and under the control of an X-ray television installation (Fig. 2).

Simultaneous assessment of the condition of the cavity formation on echograms with the puncture makes it possible to achieve a reduction in size, followed by complete disappearance of the image of the cavity formation;

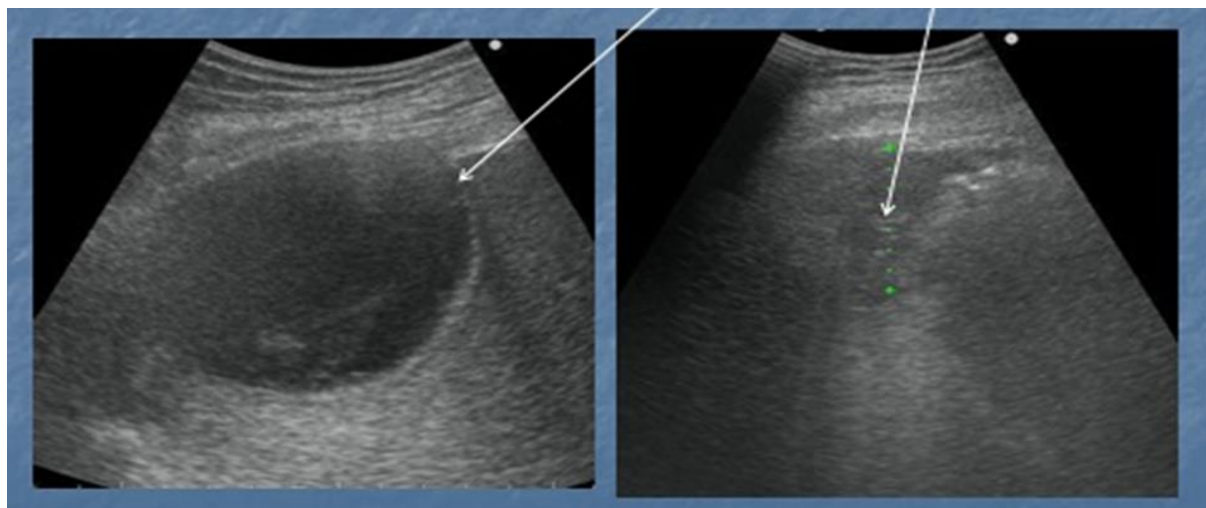
During this procedure, after removing the first 1-2 ml of liquid, the material was taken for bacteriological examination.

Contrast and RC emptying were adequate. No penetration of contrast into the bile ducts was detected.

The dynamics of the pathological process were monitored by ultrasound and fistulscopy (or fistulography). These studies were carried out, as a rule, intraoperatively, and in the postoperative period once every 2 days.

After installing the drainage, the RC was sanitized with Decasan solution. Having completed the sanitation, 5-10 ml of a 1% dioxidine solution was injected into the cavity (depending on its volume) with an exposure of 5 minutes, after which the entire contents were aspirated and the needle was removed.

After puncture and drainage, the RC was washed twice a day with warm (up to 50 °C) furatsilin (1:5000) and Decasan solution with constant active aspiration. Ultrasound and, if necessary, fistulography were performed over time. According to indications, antibiotics were prescribed and infusion therapy was performed. We did not observe any complications during puncture and drainage treatment of RC. There were no patients who died.



Before RC puncture

After RC puncture

**Figure 2.** I/B No. 2571/564. Ultrasound and X-ray television monitoring

After puncture and drainage treatment, the RC size after liver EE was significantly reduced. From 6-7 days after RC cleansing, sclerotherapy was carried out for 10-15 days until the cavity size was reduced to 10-15 mm.

Sclerotherapy was carried out as follows. First, in order to prevent a reaction to iodine, a skin test for sensitivity to 5% iodine was performed. A 2.5% alcohol solution of iodine was used. If the patient had normal sensitivity to iodine, 20% sodium chloride was injected and exposure was carried out for 20 minutes. If the patient was hypersensitive to iodine, ethyl alcohol was used in increasing concentrations - 20°, 45°, 60°, 75°, 96°. When painful sensations appeared, they switched to lower concentrations. The volume of the administered mixture depended on the volume of the cavity and amounted to 15 ml for sclerosis of non-festering cavitory liver formations, and from 3 to 7 ml for abscesses at the final stage of treatment. After exposure, the remaining mixture was removed by aspiration with a syringe. This made it possible to prevent the development of sclerosing cholangitis, which in our observations never developed after sclerotherapy. The procedure was performed once a day until the size of the RC was reduced to 1-1.5 cm. On days 11-13, ultrasound in 2 patients determined complete closure of the RC, after which the drainage was removed.

The average length of hospital stay was  $3.16 \pm 2.43$  days. In only 1 patient the drainage tube functioned for up to 1 month, without any complications. In all patients, the drainage was removed after the elimination of RC and complete cessation of drainage. There were no deaths or complications associated with the use of this treatment method.

For the above indications, the use of percutaneous puncture-aspiration treatment of complications of RC after EE under ultrasonography control has significant advantages over traditional laparotomy, due to low trauma, the ability to perform the procedure under local anesthesia, a reduction in the length of the patient's hospital stay, cost-effectiveness and a low percentage of postoperative complications. This method reduced the risk of surgical aggression in people with concomitant diseases.

After puncture and drainage treatment, local and general complications were observed. Local - noted in 1 (11%) patients: inflammation around the drainage tube in 1 (1.1%). Bleeding from the drainage tube was not controlled after hemostatic therapy. Note that these complications occurred at the stage of development of the technology of puncture-drainage treatment methods under ultrasound control.

Of the general complications, allergic reactions were noted in 2 (2.2%) patients, which were eliminated with drug therapy. There were no deaths. No relapses of cavitory liver formations were detected within 3 years.

Based on the research results, we determined the indications for the puncture-drainage method of treating RC after liver EE, these are: signs of intoxication, hyperthermia, the presence of a liquid formation more than 35-40 mm in diameter. Of the 3 patients who underwent puncture-drainage, 1 (1.1%) had perifocal inflammation around the drainage tube, which quickly regressed after appropriate

local treatment. The average length of hospital stay was  $2.16 \pm 1.43$  days. From the analysis of medical records, it turned out that before the introduction of the puncture-drainage method of treating complicated RC, up to 10.4% of RC suppurations were observed in the postoperative period, due to the failure to conduct timely ultrasound monitoring of RC. In the postoperative period, in 10.4% of cases, relaparotomy was performed, while the percentage of puncture-drainage methods was 0.8%.

The effectiveness of the performed manipulations under ultrasound control was 97.7%. One patient had prolonged discharge of infected discharge through the drainage and signs of intoxication persisted, which served as an indication for laparotomy and an open method of treatment.

Based on the results of the research, we determined the indications for the puncture-drainage method of treatment of RC after EE of the liver, these are: signs of intoxication, hyperthermia, the presence of a liquid formation more than 30 mm in diameter, taking into account indications and contraindications facilitates the implementation of ultrasonic puncture-drainage methods for the treatment of cavitory formations of the liver with large effectiveness and low complications.

Analyzing the results of drainage operations, we can conclude that after puncture-drainage treatment one should abstain in the presence of multilocularity and massive hyperechoic inclusions (sequestra). In other clinical situations, puncture-drainage intervention may be considered the method of choice.

## 4. Summary

Thus, the developed diagnostic and treatment measures using ultrasound and fistulography make it possible to establish a diagnosis and select the optimal method of treatment for RC in the shortest possible time. Laparoscopic sanitation and ultrasound-guided puncture and drainage interventions in the treatment of complicated RC after EE may now find wider clinical application [1,2,3,4,5,6,7,8,9,10].

---

## REFERENCES

- [1] WHO. Echinococcosis. Newsletter N377. April, 2016 – URL: <http://echinococcus.ru/voz-ehinokokkoz-informacionniy-b>.
- [2] WHO. Echinococcosis. News bulletin. February, 2018 – URL: <http://www.who.int/ru/news-room/fact-sheets/detail/echinococcosis>.
- [3] World Health Organization. Echinococcosis // Information bulletin. Access date: 10/13/2019.
- [4] WHO. Echinococcosis: Information bulletin // Geneva: 2020. - March 23. [arch. June 14, 2021].
- [5] Age classification of the World Health Organization (WHO). 2021. April 4. <https://glavkniga.ru/forum/topic/6904#>.

- [6] Kalieva D.K. Modern methods of surgical treatment of liver echinococcosis // Textbook. Karaganda, 2018. 39-44.
- [7] Otakuziev A.Z. and others. Therapeutic algorithm for surgical complications after liver echinococcectomy // Bulletin of the Russian State Medical University. – No. 2. materials of the scientific and practical conference. – M., 2015. P. 485.
- [8] Skakbaev A.S., Doskhanov M.O., Baimakhanov Zh.B. and others // Bulletin of Surgery of Kazakhstan. - 2017. -“2. – pp.
- [9] Shamsiev Zh.A. and others. Results of surgical treatment of liver echinococcosis // European Science, 2017. No. 7. P. 49-54.
- [10] Amado-Diago C.A., Gutiérrez-Cuadra M., Armijañanzas C. Et al. Echinococcosis: A 15-year epidemiological, clinical and outcome overview // Revista Clínica Española. – 2015, Vol. 215(7), pp. 380–384.

Copyright © 2025 The Author(s). Published by Scientific & Academic Publishing

This work is licensed under the Creative Commons Attribution International License (CC BY). <http://creativecommons.org/licenses/by/4.0/>