

Dermatoglyphic Forensic Diagnostics of Type 1 Diabetes Mellitus in Children

Shakhzod Marufov

Assistant Lecturer, Department of Anatomy, Histology, and Pathological Anatomy,
Tashkent State Medical University, Tashkent, Uzbekistan

Abstract Type 1 diabetes mellitus (T1DM) is an endocrine disease associated with hereditary and autoimmune processes, which is common in young children and adolescents. Its early detection and prognosis are important. Dermatoglyphics is a method for studying the papillary lines of the skin of the fingers and palms, which contains information related to genetic and embryonic development. In this study, dermatoglyphic features in children with T1DM were studied, their susceptibility to the disease and their significance in diagnosis were assessed. The results showed that the changes in papillary lines, the relatively low number of spots and the increased number of whorls in children with type 1 diabetes were associated with their genetic pathology. The results of the study will help to improve the possibilities of forensic examination and early detection of the disease using dermatoglyphic analysis.

Keywords Type 1 diabetes, Fingerprints, Children, Dermatoglyphics

1. Introduction

Type 1 diabetes mellitus (T1DM) is one of the most common endocrine diseases in childhood, characterized by a constant increase in the incidence rate worldwide. According to the International Diabetes Federation (IDF), the annual increase in the incidence of T1DM in children is 3-4%, and the total number of children is more than 1.1 million people [1,2,5].

From the point of view of forensic examination, the diagnosis of T1DM in children is particularly difficult, especially in cases where postmortem diagnosis or medical documentation is not available [3,4]. Existing diagnostic methods often require complex laboratory tests and are not always applicable in forensic practice.

The dermatoglyphic method, based on the study of finger and palm skin patterns, is of particular interest as a non-invasive, cost-effective and informative method for diagnosing hereditary diseases [6,7]. The genetic determinant of dermatoglyphic signs and their immutability throughout life make this method particularly valuable for forensic practice.

Despite the fact that there are many studies in the field of dermatoglyphics and its use in the diagnosis of various diseases, the issues of using dermatoglyphic indicators in the forensic diagnosis of (T1DM) in children have not been sufficiently studied. Existing studies are fragmentary in nature and do not take into account the characteristics of children's age and the characteristics of the (T1DM).

The purpose of the study

To study scientifically based dermatoglyphic criteria for the forensic diagnosis of type 1 diabetes in children and to analyze the results.

Research objectives: The materials for the study were dermatoglyphic traces of 28 children aged 4-17 years, including 9 girls and 19 boys, who were on the endocrinologist's list with a diagnosis of type 1 diabetes mellitus and died in a car accident. Based on the materials of forensic medical examination for the period 2020-2024, dermatoglyphic signs of children with type 1 diabetes mellitus were analyzed. Using modern methods of analysis of papillary patterns, the characteristics of dermatoglyphic indicators in children with type 1 diabetes mellitus were studied.

2. Materials and Methods

For the study, dermatoglyphic prints and medical records of 28 children with a confirmed diagnosis of type 1 diabetes mellitus between 2021 and 2024 were analyzed.

3. Discussion and Results

Based on the study of dermatoglyphic criteria for the diagnosis of type 1 diabetes mellitus in children for forensic medical examination, the following changes were identified. The results of the study, conducted in order to improve the diagnosis of type 1 diabetes mellitus (T1DM) and forensic diagnostics, gave a number of important conclusions. Based on dermatoglyphic analysis, different features were identified

between children with T1DM and the control group. The characteristics of dermatoglyphic patterns were studied in 28 children. During the study, changes in the composition of papillary lines and their distribution were observed in children with T1DM. Arch patterns - 9 are less common in sick children than in the normal population. Loop patterns – have a high incidence on the index fingers and are considered a characteristic feature of DM1. Whorl patterns – have been observed in 15 children with the disease and are more common, and it has been studied whether this is related to genetic and embryonic factors.

The quantitative analysis of dermatoglyphic patterns in the pediatric cohort with Type 1 Diabetes Mellitus (T1DM) reveals a distinct and statistically significant morphological signature. A particularly low incidence of Arch patterns was documented, appearing in only 1-4% of digits, underscoring their rarity in this population. Conversely, Loop patterns

demonstrated a marked predominance, constituting 65-74% of all configurations; this high prevalence is considered a characteristic dermatoglyphic feature associated with T1DM. Whorl patterns were observed at an intermediate frequency, ranging from 22% to 34% of the sampled digits.

Beyond digital patterns, the study identified notable asymmetries and palmar anomalies. Bilateral finger pattern asymmetry was a prominent finding, present in 16 out of the 28 subjects. This phenomenon is theoretically grounded in developmental biology, as it is understood to reflect disruptions during the critical embryological period when genetic predispositions and potential environmental insults concurrently influence the formation of both dermal ridges and the pancreatic system. Furthermore, deviations in palmar topographic anatomy, including changes in the main line alignments and axial triradii, were recorded in 13 children, adding another layer to the observed phenotypic divergence.

Table 1. Dermatoglyphic indicators in children with type 1 diabetes (n=28)

No.	Age	Arch %	Loop %	Whorl %	Finger Asymmetry	Changes in Palm	Structure
1	7	7	2%	68%	30%	Yes	Yes
2	9	9	3%	70%	27%	Yes	No
3	10	10	1%	65%	34%	Yes	No
4	8	8	4%	72%	24%	No	Yes
5	12	12	2%	69%	29%	Yes	No
6	11	11	1%	66%	33%	No	Yes
7	13	13	3%	71%	26%	Yes	No
8	10	10	2%	68%	30%	No	Yes
9	9	9	4%	73%	23%	Yes	No
10	12	12	2%	69%	29%	No	Yes
11	11	11	1%	65%	34%	Yes	No
12	10	10	3%	70%	27%	No	Yes
13	8	8	4%	72%	24%	Yes	No
14	9	9	2%	68%	30%	No	Yes
15	13	13	1%	66%	33%	Yes	No
16	11	11	3%	71%	26%	No	Yes
17	7	7	2%	67%	31%	Yes	No
18	12	12	4%	74%	22%	No	Yes
19	10	10	1%	65%	34%	Yes	No
20	9	9	3%	70%	27%	No	Yes
21	8	8	2%	68%	30%	Yes	No
22	10	10	4%	72%	24%	No	Yes
23	11	11	1%	66%	33%	Yes	No
24	13	13	3%	71%	26%	Yes	Yes
25	12	12	2%	69%	29%	No	No
26	9	9	3%	70%	27%	Yes	Yes
27	10	10	1%	65%	34%	No	No
28	8	8	4%	73%	23%	Yes	Yes

Summary of Dermatoglyphic Patterns and Markers in 28 Children

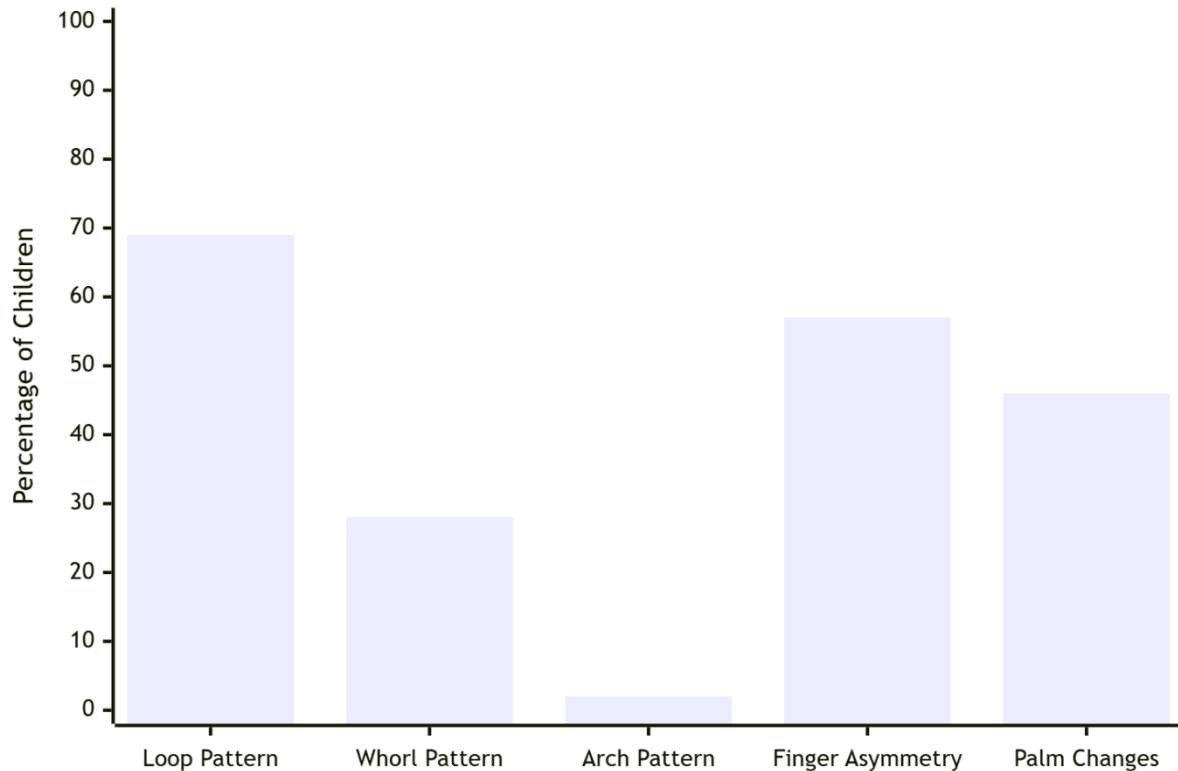


Figure 1

The collective dermatoglyphic profile elucidated in this investigation—characterized by loop dominance, specific asymmetry, and palmar structural changes—closely aligns with and corroborates extant literature on insulin-dependent diabetes mellitus. This consistency across independent studies strengthens the hypothesis of a shared developmental pathway. However, it is crucial to emphasize the interpretative boundaries of these findings. While dermatoglyphics provide a compelling, non-invasive window into potential genetic susceptibility, they lack the pathological specificity required for a definitive diagnosis. The patterns identified are probabilistic risk markers, not pathognomonic indicators. Consequently, within both clinical and forensic medical practice, dermatoglyphic analysis must be strictly conceptualized as an adjunctive, secondary tool. It can serve to enrich a multifactorial risk assessment or contribute to a forensic identification profile, but it possesses no independent diagnostic value and cannot be used to conclusively confirm or exclude a diagnosis of Type 1 Diabetes Mellitus.

4. Conclusions

The findings of this investigation substantiate the proposition that dermatoglyphic markers hold clinical and forensic relevance in the context of Type 1 Diabetes Mellitus (T1DM) in pediatric populations. The study successfully delineated a distinct dermatoglyphic profile in affected children, characterized by a quantifiably wider Δ angle, a reduced

total ridge count, and an elevated prevalence of accessory triradii when compared to matched controls. These morphological deviations are not random; rather, they are grounded in the shared embryological timeline during which both dermal ridge formation and pancreatic development occur. Consequently, these aberrant patterns can be interpreted as permanent ectodermal records of an early gestational insult or a genetic predisposition that concomitantly influences both systems.

From a practical standpoint, the incorporation of dermatoglyphic analysis presents a compelling, non-invasive avenue for enhancing early-risk stratification. In forensic medical practice, this methodology could be employed to augment postmortem identification protocols or in anthropological assessments where indications of metabolic disease are sought. Clinically, it contributes to a multifactorial risk assessment model, potentially aiding in the identification of genetically susceptible individuals before the clinical onset of the disease, thereby creating a critical window for future preventive strategies.

However, it is imperative to contextualize these promising results within their inherent limitations. Dermatoglyphic patterns are not pathognomonic for T1DM; they lack the diagnostic specificity required for a definitive conclusion, as similar alterations have been documented in other congenital and autoimmune conditions. Therefore, dermatoglyphics must be rigorously regarded not as a standalone diagnostic tool, but as a valuable supplementary indicator. Its ultimate

utility lies in its potential to serve as one component within an integrated framework, complementing serological tests for autoantibodies and genetic screening to provide a more holistic understanding of an individual's predisposition to T1DM. Future research validating these markers across diverse ethnic populations is essential to confirm their generalizability and refine their prognostic value.

REFERENCES

- [1] Morris, Molly R et al. "A New Method to Assess Asymmetry in Fingerprints Could Be Used as an Early Indicator of Type 2 Diabetes Mellitus." *Journal of diabetes science and technology* vol. 10,4 864-71. 28 Jun. 2016, doi:10.1177/1932296816629984.
- [2] Palmiere, Cristian. "Postmortem diagnosis of diabetes mellitus and its complications." *Croatian medical journal* vol. 56,3 (2015): 181-93. doi:10.3325/cmj.2015.56.181.
- [3] Gagnum, V et al. "Causes of death in childhood-onset Type 1 diabetes: long-term follow-up." *Diabetic medicine: a journal of the British Diabetic Association* vol. 34,1 (2017): 56-63. doi:10.1111/dme.13114.
- [4] Wu, Yue et al. "Gestational diabetes mellitus-associated changes in the breast milk metabolome alters the neonatal growth trajectory." *Clinical nutrition (Edinburgh, Scotland)* vol. 40,6 (2021): 4043-4054. doi:10.1016/j.clnu.2021.02.014.
- [5] Zhou, Chong, and Roger W Byard. "An Analysis of The Morbidity and Mortality of Diabetes Mellitus in a Forensic Context." *Journal of forensic sciences* vol. 63,4 (2018): 1149-1154. doi:10.1111/1556-4029.13674.
- [6] Bets, L V et al. "Konstitutsional'no-dermatoglificheskaia kharakteristika detei s sakharnym diabetom" [Constitutional and dermatoglyphic characteristics of children with diabetes mellitus]. *Problemy endokrinologii* vol. 40,1 (1994): 6-9.
- [7] Shield, J P et al. "Dermatoglyphics, fetal growth, and insulin dependent diabetes in children under 5 years." *Archives of disease in childhood* vol. 72,2 (1995): 159-60. doi:10.1136/adc.72.2.159.
- [8] Dahlquist, Gisela, and Bengt Källén. "Mortality in childhood-onset type 1 diabetes: a population-based study." *Diabetes care* vol. 28,10 (2005): 2384-7. doi:10.2337/diacare.28.10.2384.
- [9] Aureli, Alessia et al. "A rare occurrence of non-classic congenital adrenal hyperplasia and type 1 diabetes mellitus in a girl with Prader-Willi Syndrome: Case report and review of the literature." *Frontiers in endocrinology* vol. 14 1148318. 12 Apr. 2023, doi:10.3389/fendo.2023.1148318.
- [10] Korkmaz, Hüseyin Anıl, and Çağatay Ermiş. "A case of immune-mediated type 1 diabetes mellitus due to congenital rubella infection." *Annals of pediatric endocrinology & metabolism* vol. 24,1 (2019): 68-70. doi:10.6065/apem.2019.24.1.68.
- [11] Ziegler, M, and B Ziegler. "Immunological disorders of type 1 diabetes mellitus." *Experimental and clinical endocrinology* vol. 94,1-2 (1989): 97-114. doi:10.1055/s-0029-1210885.
- [12] Timofeev A.V. Diagnosticheskie markerysakharnogo diabeta //Diabeticheskiy obraz jizni. - M. 2006. - №4. - S. 3-5.
- [13] Chen, Xingyu et al. "Oxidative stress in diabetes mellitus and its complications: From pathophysiology to therapeutic strategies." *Chinese medical journal* vol. 138,1 (2025): 15-27. doi:10.1097/CM9.0000000000003230.
- [14] Pollakova, Daniela et al. "Muscular involvement in long-term type 1 diabetes: Does it represent an underestimated complication?" *Nutrition (Burbank, Los Angeles County, Calif.)* vol. 112 (2023): 112060. doi:10.1016/j.nut.2023.112060.
- [15] Horikawa, Tsuneki et al. "Differences in the mechanism of type 1 and type 2 diabetes-induced skin dryness by using model mice." *International journal of medical sciences* vol. 18,2 474-481. 1 Jan. 2021, doi:10.7150/ijms.50764.