

Impact of Regional Ozone Treatment on Dental Mucosa When Utilizing Adjustable Dentures

A. H. Jumayev

Bukhara State Medical Institute named after Abu Ali ibn Sina, Bukhara, Uzbekistan

Abstract Based on the results obtained below, a method of local ozone therapy is recommended for elderly patients in need of dental orthopedic treatment, representatives of different social groups. The processes of adaptation to removable dentures of the elderly through local application of ozonated olive oil were evaluated among patients of gerontological age in different social groups.

Keywords Ozone therapy, Removable dentures, Old age, Oral mucosa

1. Introduction

Despite continuous development and improvement of treatment methods and technologies used in dentistry, the need for orthopedic care of patients has gradually increased in recent years [1]. At the same time, the share of removable prostheses relative to the total volume of orthopedic constructions produced is also increasing [2]. These are associated with various factors: an increase in life expectancy in individuals, a higher prevalence of hard tooth tissue pathologies, and periodontal disease [8]. On average, 65% of patients seeking orthopedic care will need prosthetics with removable dentures [5].

The detrimental impact of removable dental appliances on the mucosal layer of the prosthetic foundation, which is ill-equipped to handle chewing stress, has been extensively examined. The array of complications arising in this area is attributed not just to the mechanical influence of the appliance, but also to ongoing inflammation of the mucous layer, the effects of microbial toxins from bacteria that gather on the surface of the appliance, and occasionally by the chemical elements of the prosthetic materials [3].

Concurrently, there is a significant likelihood of developing microcirculation issues, inflammation, and various degrees of regenerative disorders in the mucosal lining of the prosthetic site, particularly in elderly patients. The protective capabilities of the epithelium decline: the migration of leukocytes across the mucosal surface is hindered, and the shedding of epithelial cells notably increases, especially during the initial phase of prosthesis usage [7].

When inflammation occurs, the damage to the epithelium is heightened. The base of the removable prosthesis hinders the touch, flavor, and temperature perception of the oral mucosa.

In most pathological conditions, especially in the presence of severe inflammatory processes, the analgetic effect of ozone is clearly pronounced. On the one hand, this is due to its pronounced anti-inflammatory effects, which we described above and play an important role in acute inflammation. In chronic inflammatory processes, restoring the balance between the composition of peroxidation products and the level of antioxidant protection, accelerating regenerative processes, plays an important role.

Therefore, the search for new therapeutic measures to reduce the effect of removable dentures on the tissues of the patient's prosthetic base and thereby improve the process of adaptation to them is, in our opinion, a very urgent task in dentistry.

Aim of the study. Enhancement of the adjustment procedure for detachable plate prosthetics in senior individuals via localized use of ozonated olive oil.

2. Materials and Methods

A total of 92 individuals (68 females, 24 males), aged between 60 and 70 years (considered elderly according to WHO criteria), participated in the research. Evaluation of patients was carried out on the basis of the Department of Orthopedic Dentistry of BSTI with the registration of specially developed complaints, anamnestic and objective data, registration on the card of the results of laboratory and functional research. The generally accepted methods for identifying caries pits, such as caries, probing, were used by registering the location of carious pits, fillings, and extracted teeth. The intensity of dental caries injury was determined by calculating the KPO and KPOp indices. Clinical examination

* Corresponding author:

jumayev.akbar@bsmi.uz (A. H. Jumayev)

Received: Sep. 19, 2025; Accepted: Oct. 9, 2025; Published: Oct. 11, 2025

Published online at <http://journal.sapub.org/ajmms>

of the oral mucosa involves identifying its color, humidity, the presence of morphological elements of wounds, pain during palpation, and suppleness of the teeth, in case of their complete absence. The hygienic condition of the oral cavity was assessed using the Fedorov-Volodkina index (1971). This index was chosen in most cases due to the infrequent absence of one or more segments of the lateral teeth due to the impossibility of evaluating more modern indices for assessing oral space hygiene in patients with removable dentures. The prevalence of milk inflammation was determined using the PMA index modified by Rappa (1976), which is indicated by %. Bleeding was detected using the Muhleman-Saxer method (Bleeding Index PB1, 1971).

Patients in the observation groups applied ozonated olive oil to the mucous membrane of the prosthetic base. The synthesis of this medication was performed using an ozonator. The key factors of olive oil ozonation include an ozone concentration in the oxygen blend of 20 mg/l, with a foaming duration of 10 minutes for 100 ml of oil. To facilitate dosing, the medication was packaged in standard 20 ml plastic syringes. The applications were performed as follows:

- 1) The patient applied lubricant to the inner surface of the previously sanitized prosthesis(es) (1 ml for each prosthesis) using a syringe (with the needle removed), ensuring an even distribution across the entire area;
- 2) The patient, while wearing the prosthesis(es), refrained from eating or drinking for 20 minutes;
- 3) Following this, the patient placed the prosthesis(es) orally, rinsed their mouth with water, and washed the prosthesis(es) under running water. Afterward, they

reinserted the dentures and continued regular use.

Treatment duration: 10-14 days. This procedure was conducted daily for the patients, once a day, after the hygienic cleaning of the denture for 20 minutes.

3. Research Results and Discussion

The cleanliness status of the mouth in individuals missing full dentition was assessed using the Ambjornsen technique, which relies on the state of the prosthetics (Figure 1).

The analysis indicates that the cleanliness of removable dentures treated with ozonated olive oil remains significantly high (on average, it decreases by 1 point after 2 weeks, 2 points after 1.5 and 3 months, and by 1 point after 6 months). Nevertheless, it can be observed that in both groups, the condition is progressively declining, and after several months of using the prostheses, it becomes insufficient.

An examination of the characteristics of mixed saliva indicated that localized ozone treatment generally did not produce notable alterations in the examined metrics, such as the decomposition rate of mixed saliva and its thickness. Its application in individuals with partially and fully removable dentures resulted in some alterations in parameters - an elevation in the salivary secretion rate paired with a decrease in its adhesive properties, and approximately 1.5 months later, these metrics reverted to their baseline values. There were indications of hyposalivation in a segment of patients over an extended period (Table 1). Comparing these findings with those from the control group does not permit us to claim any substantial differences.

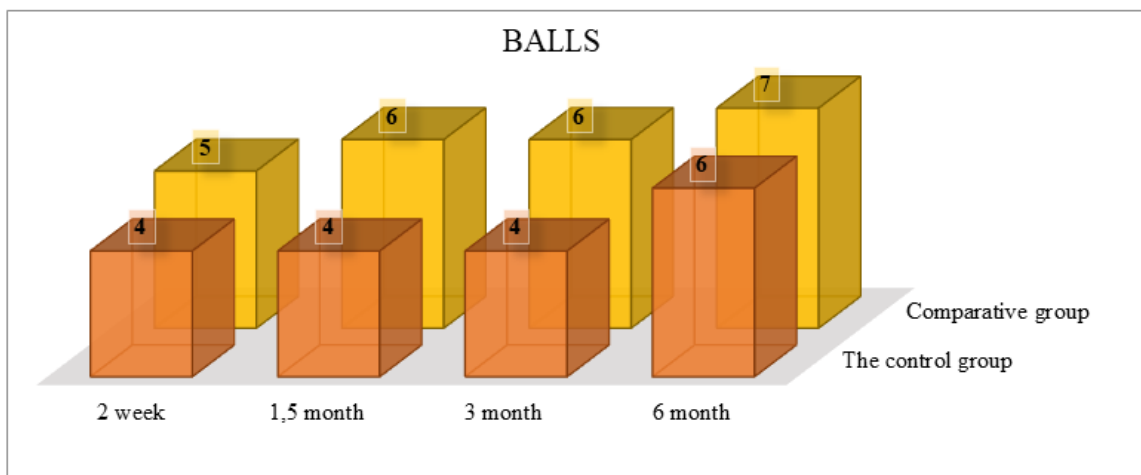


Figure 1. Impact of localized ozone treatment on the cleanliness status of completely detachable plaque dentures

Table 1. The interaction of various glacial features contrasted with the context of local ozone management (n=46)

Parameters	Period of follow-up				
	Before treatment	After 2 weeks	After 1.5 months	After 3 months	After 6 months
Saliva secretion rate (ml/min)	0,21; 0,17-0,42	0,41; 0,2,4-0,89	0,25; 0,19-0,62	0,19; 0,15-0,28	0,19; 0,16-0,24
Saliva density	2,5; 2,2-3,1	1,8; 1,4-2,6	2,2 2,8-17	2,6; 1,8-3,1	2,5; 2,2-3,1

Table 2. Variation of pH levels in combined saliva among individuals with complete removable denture prosthetics (n = 46)

Parameters		Period of follow-up				
		Before treatment	After 2 weeks	After 1.5 months	After 3 months	After 6 months
pH	The control group	7,05; 6,81-7,28	7,21; 6,98-7,36*,**	7,24; 6,93-7,36**	7,14; 7,11-7,3**	7,07; 6,91-7,14*,**
	Comparative group	6,98; 6,81-7,2	6,92; 6,76-7,12	6,8; 6,71-6,92	6,78; 6,73-6,84	6,73; 6,69-6,81

Note: * - significant differences compared to the previous follow-up period, $p < 0.05$, Wilcoxon test,
 ** - significant differences relative comparison groups, $p < 0.05$, Mann-Whitney test.

Marked variations in the pH levels of the combined saliva can be observed among individuals in the research groups with completely removable dentures both in the initial phases and in the long run (Table 2). However, a dynamic analysis of outcomes in a group of patients with ozone therapy revealed no significant differences compared to baseline.

The findings of the antioxidant activity research are displayed are akin to the information gathered in the evaluation of this parameter in individuals with partially removable plate prosthetics.

In contrast to individuals with partial dentition defects, the beneficial effect persisted throughout the entire follow-up duration; however, there was a minor decrease to baseline at 3 and 6 months, yet it remained significantly elevated compared to the control group. The findings of the cytological analysis indicated substantial variations in the condition of the mucosal membrane epithelium of the prosthesis in patients with fully removable dentures when utilizing the localized application of ozonated olive oil. In the early stages of follow-up, the epithelial cell differentiation index increased significantly with local ozone therapy, increasing gradually over the long term.

When compared to the control group, notably elevated index values were observed with the local application of ozonated olive oil in the initial phases and positive adjustments were maintained over the long run. In examining the changes in keratinization index values of epithelial cells, noteworthy differences were also identified between participants in the study groups: a significant rise in the early phases of the keratinization index during local ozone therapy. Unlike patients in the comparison group, this rate also increased throughout the entire follow-up period.

When studying the adsorption reaction of microorganisms by epithelial cells, significant differences in the values of the adsorption reaction of microorganisms by epithelial cells were found between patients in both groups with fully removable prostheses, noted between the groups in the early stages of follow-up, where there were significant differences.

Laser Doppler fluorometry results, which assessed indicators of tissue microcirculation in the mucous membrane of the prosthesis, demonstrated a distinct positive impact of ozone therapy. Despite the exceptionally adverse conditions for the operation of tissues in the prosthetic sites, particularly with completely removable dentures, this has resulted in the

maintenance of the initial level of blood flow even after the placement of these prostheses. The evaluation of the microbiological study outcomes revealed that patients in the follow-up group showed no significant alterations in the quantitative and qualitative composition of microflora during the earlier periods (14 days, 1.5 months). It is also noteworthy that none of the patients in the observation group exhibited laboratory indications of candidiasis (in the comparison group, such results were found in 3 patients).

In terms of long-term follow-up durations, we can observe a negative trend regarding the increase of titers of various microbial flora representatives; however, in the majority of instances, no substantial differences were found compared to the initial levels. An analysis of patient-completed questionnaires aimed at assessing adaptation to removable dentures highlighted some significant variances in the localized application of ozone therapy. In comparison to the conventional prosthetic approach, several major complaints associated with prosthesis usage were notably less frequent in the observation group. Issues such as discomfort under the prosthesis, irritation due to the presence of the prosthesis in the oral cavity, already showed significant differences in the initial follow-up stages. Moreover, a slightly reduced number of patients reported experiencing dry mouth symptoms. Meanwhile, although early on, ozone therapy had a minimal impact on complaints such as speech impairment and sound articulation, as well as difficulties with food biting, these issues were also considerably diminished due to the expedited adaptation process to the prosthesis.

Overall, the adaptation time when applying local ozone therapy was reduced by 30% with fully removable prostheses.

A distinct beneficial impact of local ozone therapy was noted in the case study. This conclusion was reached two weeks after initiating the study, based on a notable decrease in the occurrence of inflammation (PMA index) and a significant reduction in bleeding (Muyleman-Saxer index). Such outcomes can be attributed to ozone's effects on several pathogenic factors of periodontal diseases, namely: a reduction in inflammatory events, enhancement of capillary blood circulation, activation of the antioxidant defense system, and pronounced antibacterial action, particularly against anaerobic flora. This plays a crucial role in the progression of periodontitis. Ozone therapy enhances oxygen supply to periodontal tissues and also has a potential immunomodulatory effect. It is particularly noteworthy that this effect has, in part,

persisted much longer since the initiation of the study, enabling us to discuss the favorable influence of ozone therapy not only on the patient's adaptation to removable prostheses but also on potential occurrences. Overall, the application of ozone in periodontology is regarded as one of the most promising avenues in this branch of dentistry, as this method, coupled with safety, enables the achievement of favorable results.

Therefore, the findings of the research indicate a notable positive impact on several clinical and laboratory measures concerning the oral health of elderly individuals utilizing removable plate prostheses combined with local ozone therapy. This includes enhanced hygiene conditions of both the oral cavity and the removable dentures, a significant decrease in the prevalence and intensity of inflammation in the area of the remaining teeth, and a stimulated regeneration of the mucosal epithelium. Maintaining the original state of the prosthetic site and its blood supply contributes to preserving the qualitative and quantitative balance of the normal oral microflora. The synergy of these beneficial effects, together with the clinical outcomes of local ozone therapy, has led to a considerable speeding up of the adaptation process for seniors to removable plate prostheses and a reduction in the associated complaints that accompany this adjustment.

REFERENCES

- [1] Maxamatov Umidjon Shoirjonovich, Qosimov Zafarbek Odiljon ugli, Jumaev Akbar Khamidovich, Alimova Nigina Pulatovna, Idiyev Oybek Elmurodovich, Khaydarova Nasiba Adkhamovna. Treatment of metabolicly associated fatty liver hepatitis in the young population. (2024). *Cahiers Magellanes -NS*, 6(2), 6512-6515. <https://magellanes.com/index.php/CMN/article/view/984>.
- [2] Klicheva Iqbolkhon Bakhtiyorovna, Jumaev Akbar, Alimova Nigina, Salomov Shokhabbos Nozimjon og'li, Idiyev Oybek Elmurodovich, Pulatova Ugilkhan Sobirjon kizi (2024) Secretary Activity Of The Pancreas And The State Of Enzyme Homeostasis In Hypokinesia And Radiation. *Frontiers in Health Informatics*, 13 (3), 639-647.
- [3] Baymuradov Ravshan Radjabovich, Kamalova Shakhnoza Muzaffarovna, Temirova Nazokat Rustamovna, & Asadova Nigora Khamroyevna. (2023). Morphometric Parameters of The Testis of 6-Month-Old Rats in The Norm and Under Radiation Exposure. *Journal of Advanced Zoology*, 44(S5), 2167–2171. <https://doi.org/10.17762/jaz.v44iS-5.1800>.
- [4] Kamalova Shakhnoza Muzaffarovna, Baymuradov Ravshan Rajabovich, Temirova Nazokat Rustamovna, & Rasulova Mokhigul Matyokubovna. (2023). Assessment of Changes in Trunk Parameters in Children with Scoliosis. *Journal of Advanced Zoology*, 44(S-5), 2200–2202. <https://doi.org/10.17762/jaz.v44iS-5.1806>.
- [5] Kharibova, E., & Kamalova, S. (2024). Comparative analysis of trunk indicators in children with scoliosis. In *BIO Web of Conferences* (Vol. 121, p. 04006). EDP Sciences.
- [6] Teshayev, S., Radjabov, A., Khasanova, D., Temirova, N., Kamalova, S., & Asadova, N. (2024). Ultrasound organometry of the human prostate in the age aspect and its changes in chronic alcoholism. In *BIO Web of Conferences* (Vol. 121, p. 03012). EDP Sciences.
- [7] Muzaffarovna, K. S., Aleksandrovna, X. E., & Jumayevich, T. S. (2021). Morphofunctional Features of the Feet in Children with Scoliosis, Depending on their Constitutional, Gender and Age Characteristics. *Turkish Online Journal of Qualitative Inquiry*, 12(7).
- [8] Akbarov, A. N., & Jumayev, A. (2020). Hygienic condition of prostheses in patients with partially removable dental prostheses. *PalArch's Journal of Archaeology of Egypt/Egyptology*, 17(6), 14351-14357.
- [9] Jumaev A. Kh. (2022). Comparative analysis of the application of bacteriostatic preparation and hygiene activity to dental prosthesis in elderly patients. *Science Asia*, 48 (6), 1121-1127. <https://doi:10.2307/scienceasia1121-1127.2022.SA2395>.