

Clinical and Diagnostic Features of Complicated Chronic Purulent Middle Otitis Media

Khatamov Jhakhongir Abruevich

Samarkand State Medical University, Uzbekistan

Abstract The development of local and intracranial complications in chronic purulent middle otitis media (CPMSO), including fatal cases, necessitates a comprehensive analysis of their occurrence patterns, as well as the development of effective approaches to diagnosis and treatment. We examined 124 CGSA patients with various complications who had been hospitalized for the last 20 years and received complex treatment. The aim of the study is to analyze some indices of endogenous intoxication, to analyze microbial flora of different parts of the middle ear, to assess the sensitivity of these microorganisms to various antibiotics and to identify the degree of hearing loss in CGSA with complications. Infectious processes caused by bacterial agents can lead to an increase in the concentration of fibrinogen in plasma, worsening the rheological properties of blood, disrupting microcirculation and limiting the oxygenation of tissues and organs, which may play a significant role in the pathogenesis of complications of CHSO. At analysis of blood there is a shift of leukocytic formula to the left, as well as an increase in erythrocyte sedimentation rate (ESR) and C-reactive protein (CRP) level. Increased indices of lipid peroxidation products (LPO) and metabolites of endogenous intoxication, which leads to damage to cellular and subcellular structures that in almost all cases to some extent affects auditory perception. Staphylococcus aureus was detected in 63.8% of patients by microbiologic examination. Among them, Staphylococcus aureus was detected in 29.2%, epidermal Staphylococcus aureus in 31.9%, and saprophytic Staphylococcus aureus in 2.7%. Gram-negative flora from the external auditory canal was isolated only in associations of microorganisms (24.9%). Pseudomonas aeruginosa was found in 15.8% of patients and Klebsiella oxytoca in 9.1%. In microbial associations, yeast and mold fungi of the genus Aspergillus spp., Candida spp. and Mucor spp. were detected. Obligate-anaerobic microorganisms were less common, with Peptostreptococcus spp. predominating among them. The combined application of hyperbaric oxygenation with antioxidants and plasmapheresis improves blood biochemical parameters and audiologic characteristics, which can be the basis for further improvement of treatment tactics.

Keywords Chronic purulent otitis media, Otogenic complications, HBO, Plasmapheresis

1. Relevance

Nowadays, early diagnosis and effective treatment of chronic purulent otitis media and its complications occupy a special place in otorhinolaryngologic practice. The development of local and intracranial complications, including fatal cases, necessitates a comprehensive analysis of the patterns of their occurrence, as well as the development of effective approaches to diagnosis and treatment [2,3,9,10,11,16,17,19,20].

Microorganisms, including streptococci, staphylococci, pneumococci, anaerobic bacteria, fungal pathogens and other opportunistic microorganisms, have a significant impact on the development of chronic purulent otitis media with complications. Microbiologic examination of middle ear contents, liquor and purulent foci in the cranial cavity often reveals the presence of mixed microflora [1,7,14,22].

Infectious processes caused by viral or bacterial agents can contribute to an increase in plasma fibrinogen concentration, which leads to the development of hypercoagulability, deterioration of blood rheological properties, impairing microcirculation and limiting tissue and organ oxygenation, which can play a significant role in the pathogenesis of complications of CCHO [2,4,5,8,19].

As a result of the inflammatory process, there is an increase in endogenous intoxication, an increase in body temperature above 38°C, tachycardia and tachypnea, a leftward shift of the leukocytic formula, and an increase in erythrocyte sedimentation rate (ESR) and C-reactive protein (CRP) levels [1,7,12,13,18,20].

Inflammatory processes in the body are caused by damage to cellular and subcellular structures, arising under the influence of lipid peroxidation products (LPO) and metabolites of endogenous intoxication. Disturbance of physiological equilibrium associated with changes in the optimal concentration of these compounds can lead to the development of pathological processes [2].

Changes in the rheological properties of blood, hypoxemia and metabolic acidosis play a key role in the pathogenesis of inner ear lesions. Disruption of metabolic processes first leads to a decrease in functional activity, and then to degeneration and death of hair cells, which is the cause of sensorineural hearing loss [3,6,8].

The frequency of inner ear lesions and hearing impairment in CGSA varies from 40 to 80% of cases. Some patients with CGSA with complications are not always able to determine the degree of hearing impairment due to the severe condition and confused consciousness of patients on admission to the clinic [6,12].

To reduce the effects of endogenous intoxication syndrome, improve the rheological properties of blood and restore immune defense in inflammatory diseases an effective method is plasmapheresis (PA). Replacement of the removed plasma with donor plasma contributes to the restoration of the body's defense mechanisms, accelerates the healing process and promotes the restoration of homeostasis [5,15,21].

Hyperbaric oxygenation (HBO) is effective for stimulation of tissue metabolism in purulent-inflammatory processes by increasing the partial pressure of oxygen and contributes to the reduction of intracranial hypertension, normalization of body temperature and acceleration of surgical wound healing. In this regard, HBO is successfully used in the treatment of chronic purulent-inflammatory processes of the middle ear [3,4,8,13].

However, in the available literature there are no substantiated data on the combined use of HBO with antioxidants in combination with plasmapheresis in various clinical variants of CPSO with complications.

The aim of our work was to evaluate the effectiveness of complex treatment of chronic purulent otitis media with complications.

2. Material and Methods

124 patients with CGSO with complications who received inpatient treatment in the last 20 years in ENT departments of Samarkand city hospitals were included in the study. Men were 68 (54,8%) and women 56 (45,2%) among the examined patients with CHSO complications. Age of examined patients from 18 to 40 years - 72, from 40 to 60 years - 36 and over 60 years - 16 patients.

The study revealed that chronic purulent middle otitis media, epitympanitis was diagnosed in 81 (65,3%) patients, mesotympanitis in 19 (15,3%) and epimesotympanitis in 24 (19,4%) patients. According to the history, the duration of the disease ranged from 3 years to 30 years.

The detected complications among the examined patients were local in 88 (73.0%) patients and intracranial in 36 (27.0%) patients.

All patients were consulted by an otorhinolaryngologist, neurologist, neuropathologist, neurosurgeon, ophthalmologist, infectious disease specialist, therapist, clinical and laboratory tests, RheoEG, CT and MRI of the mastoid process and brain

were performed.

Mastoiditis was diagnosed in 38 patients, 15 with atypical forms of mastoiditis, 12 with facial nerve paresis, and 23 with labyrinthitis. Figure 1

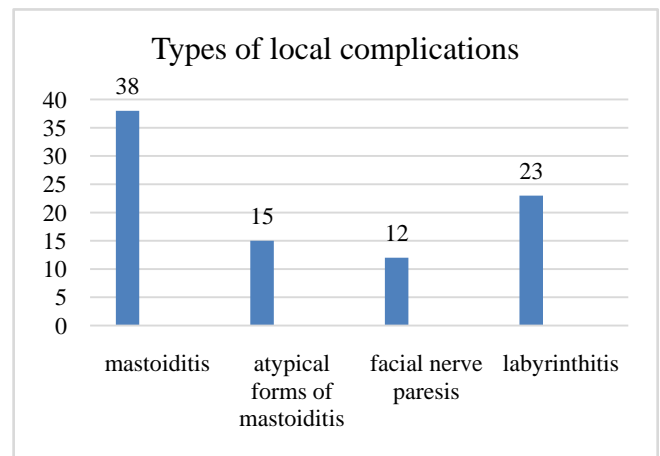


Figure 1

The general condition of patients with local otogenic complications ranged from moderate to severe. Locally, swelling and hyperemia of the skin in the area of the mastoid process was noted, spreading to the neck, occipital and temporal regions. At palpation of the apex of the mastoid process painfulness was noted. Clinically, general symptoms including increased body temperature up to 39°C, headache, moderate dizziness, vomiting, otorrhea, hearing loss, tinnitus and restriction of head movements were detected.

Labyrinthitis is characterized by an acute onset and rapid progression, accompanied by increasing severity of general symptoms. Clinically, there is an intense headache, severe dizziness, impaired stability when walking, vomiting and spontaneous nystagmus. In labyrinthitis, symptoms of peripheral facial nerve involvement are sometimes noted.

Intracranial otogenic complications included meningitis in 7 patients, meningoencephalitis in 5 patients, brain abscess in 5 patients, cerebellar abscess in 3 patients, extradural abscess in 7 patients, perisinusoidal abscess in 5 patients, and sigmoid sinus thrombosis in 4 patients. Figure 2

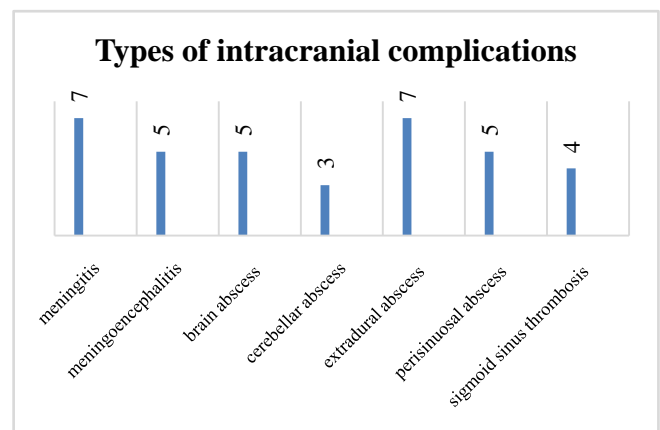


Figure 2

The clinical course of these pathologies was characterized by rapid progression with a marked increase in meningeal symptoms, which could develop within a few hours.

Often extradural abscess was accompanied by meningitis and thrombosis of the sigmoid sinus. The main clinical manifestations in patients were intense headaches, dizziness, nausea, repeated vomiting, movement coordination disorders, chills, hyperthermia, as well as heart rhythm disturbances in the form of bradycardia or tachycardia and congestive changes in the optic disc area. Some patients with purulent meningoenzephalitis had symptoms of central facial nerve damage, hemiparesis, motor aphasia and other general cerebral symptoms.

In patients with otogenic meningitis, lumbar puncture revealed increased liquor pressure up to 180-250 mm of water column. Protein content in cerebrospinal fluid varied from 0.66 to 6 g/l and was accompanied by positive Pandy and Nonne-Apelt reactions. Pleocytosis in the liquor reached 3500 cells in 1 mm³.

The state of hearing was investigated using acumetry, tonal threshold, suprathreshold, speech and computerized audiometry. The clinical results of audiologic examination in the examined patients were classified depending on the form of hearing impairment and the degree of hearing loss.

Analysis of the data shows that in the majority of the examined patients hearing loss is conductive in nature, accounting for 77 (52.0%) of the total number of patients. 55 (37.2%) patients have mixed type hearing loss, which indicates the beginning of pathologic process involvement in the inner ear. In 16 (10.8%) patients sensorineural hearing loss was detected. Figure 3

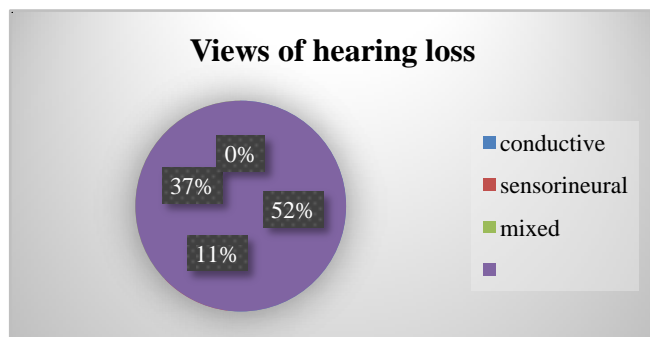


Figure 3

The examined patients were divided into 2 groups: Group I - 62 patients who received traditional treatment. Group II - 62 patients who in addition to conventional treatment received HBO with antioxidants in combination with plasmapheresis.

Biochemical indices characterizing the processes of lipid peroxidation (LPO) in patients' organism, in particular, the indices of malonic dialdehyde (MDA) and diene conjugates (DC) in patients in group I before treatment significantly ($P<0,05$) increased in comparison with the control group: respectively from $4,78\pm 0,12$ to $6,82\pm 0,21$ and from $2,41\pm 0,05$ to $3,92\pm 0,68$. At the same time, the index of total antioxidant activity (AOA), decreased from $36,9\pm 1,58$ to $27,6\pm 1,02$ ($P<0,05$).

MDA and DC indices in patients in group II before treatment significantly ($P<0,05$) increased compared with the control group: from $4,78\pm 0,12$ to $7,86\pm 0,22$ and from $2,41\pm 0,05$ to $4,79\pm 0,09$, respectively. At the same time, total AOA decreased from $36,9\pm 1,58$ to $23,9\pm 2,03$ ($P<0,05$).

In addition to the above-mentioned parameters, some partial blood parameters including pO_2 , pCO_2 were determined. Their values ($pO_2 = 11,32\pm 0,28$; $pCO_2 = 5,31\pm 0,21$;) showed no significant differences compared to the control group. However, taking into account possible changes of these parameters under the influence of HBO, their determination is of practical importance to assess the effectiveness of the conducted therapeutic measures.

In addition to general clinical and laboratory studies, all patients underwent blood analysis for C-reactive protein (CRP) and systemic inflammatory syndrome (SIS), manifested by hyperthermia over $38^\circ C$, tachycardia over 90 beats/min, rapid respiration, leukocytosis and increased COE.

Determination of two or more symptoms of SHS and an increase in blood SRB concentration indicates the presence of acute or chronic inflammation.

Comparative analysis of SRB level and CRP indicators was carried out in the dynamics of observations. According to the obtained data, expressed signs of CRP were observed in all patients (100%) in both groups.

In both groups of patients the increase of SRB level was observed and amounted from - 96.7 mg/l, to - 209.8 mg/l. This index indicates a more intense inflammatory process.

The number of leukocytes in patients increased from - $12,5\times 10^9/l$, to - $17,5\times 10^9/l$. This also confirms a more pronounced inflammatory process in the patients. The increased level of COE additionally supports this conclusion: it ranged from - $20\pm 4,9$ mm/h, to - $60\pm 5,0$ mm/h.

The analysis of hemostasis indicators also revealed a change in both groups. The level of fibrinogen in amounted from - $4,2\pm 0,11$ g/l, to - $4,9\pm 0,11$ g/l, which indicates the strengthening of blood coagulation activity in patients. Prothrombin index (PTI) was from - 108,3 seconds to - 109,8 seconds, which indicates insignificant changes but with a tendency to increase coagulation activity.

The analysis of cerebral blood circulation on the basis of rheoencephalographic (RheoEG) data showed that all patients before the beginning of treatment had changes in blood circulation in cerebral vessels and in the vertebrobasilar system. Increased peripheral vascular resistance, decreased blood vessel filling and venous outflow impediment were detected.

Bacteriological study was performed to analyze the species composition of microflora isolated from the external auditory canal, tympanic cavity, antrum, and operative cavity. Identification of isolated strains was performed using an automated bacteriological analyzer.

In microbiologic examination, microorganisms were often isolated in associations. Staphylococci were detected in 63.8% of patients. Among them, Staphylococcus aureus was detected in 29.2%, epidermal Staphylococcus aureus in 31.9%, and saprophytic Staphylococcus aureus in 2.7%.

Gram-negative flora from the external auditory canal was isolated only in microbial associations -24.9%. *Pseudomonas aeruginosa* was found in 15.8% of patients and *Klebsiella oxytoca* in 9.1%.

Only one species, *Staphylococcus aureus* monoculture, was found in cultures from the tympanic cavity in 38.0% of cases and from the antrum in 31.5% of cases, respectively. Mixed flora obtained from the external auditory canal was most often represented by associations of *Staphylococcus aureus* with Gram-negative flora 33.4%. In 9.6% of cases, yeast and mold fungi of the genus *Aspergillus* spp., *Candida* spp. and *Mucor* spp. were found in microbial associations. In bacterial-fungal associations, the most frequent were *Candida* spp. - 6,7%. These microorganisms complemented the associations of *Staphylococcus aureus* and Gram-negative flora or were observed in combination with each of these pathogens.

Obligately anaerobic microorganisms, including *Fusobacterium* spp., *Bacteroides* spp., and *Peptostreptococci*, were isolated from 9.7% of patients.

In the study of antibiotic resistance of the main microorganisms isolated from the tympanic cavity, it was found that *Staphylococcus epidermidis* has a high level of resistance to benzylpenicillin, roxithromycin and azithromycin. *Pseudomonas aeruginosa* showed resistance to carbenicillin and amoxicillin. *Staphylococcus aureus* had low sensitivity to fusidin and resistance to benzylpenicillin and ampicillin. The highest sensitivity of microbes was established for cephalosporins (cefuroxime, ceftriaxone, cefotaxime) and fluoroquinolones (ciprofloxacin).

Depending on the nature and extent of the inflammatory process, patients underwent general radical surgery and extended radical ear surgery. Before and after the operation, all patients underwent complex intensive therapy according to ICD-10 (antibiotics, detoxification, dehydration, vitamin therapy, diuretics, anesthetics, antihistamines, antifungal drugs, as well as washing the trepanation cavity with antiseptic solutions, taking into account the sensitivity of the flora to the drugs used).

3. Results and Discussion

We conducted a comparative analysis of the dynamics of treatment of patients of groups I and II who were prescribed traditional and modified therapy using HBO with antioxidants in combination with plasmapheresis.

After traditional therapy, a decrease in the concentration of MDA and DK, as well as an increase in AOA, was observed only by day 18 of therapy in patients of group I, reaching values of $6.12 \pm 0.42 \mu\text{mol/L}$, $3.23 \pm 0.21 \mu\text{mol/L}$ and 34.6 ± 1.3 , respectively. However, the level of MDA and other indicators did not reach the control.

The length of stay of patients in the hospital was 18 ± 2.8 bed-days ($p < 0.05$), and there was a positive dynamics of the inflammatory process. A positive effect was noted in 40.4% of patients, which was manifested in an improvement in

speech perception and a decrease in tonal hearing thresholds to 15 dB. All patients showed a slight improvement in blood circulation in the vessels of the brain and pathological changes began to decrease during the RheoEG examination.

After complex treatment using HBOT in combination with antioxidant therapy and plasmapheresis in patients of group II, it was possible to reduce the intensity of free radical oxidation processes and restore the functional state of the antioxidant system.

The MDA content decreased after correction from 7.86 ± 0.22 to $4.98 \pm 0.43 \text{ mmol/l}$, the DC decreased from 4.79 ± 0.09 to 2.48 ± 0.12 , and the AOA index increased from 23.9 ± 2.0 -3 to 35.9 ± 1.2 . The duration of hospitalization of patients was 14.6 ± 1.8 bed-days. The perception of sounds and speech intelligibility in 59.6% of patients showed a decrease in the hearing threshold to 25 dB at high frequencies.

The CRP content decreased to 5.7 mg/l in the first group and to 6.9 mg/l in the second group. This significant decrease compared to the initial indicators indicates the regression of the inflammatory process.

The leukocyte count decreased to $7.5 \times 10^9/\text{L}$ in the first group and $8.5 \times 10^9/\text{L}$ in the second group, which confirms the weakening of the inflammatory response. The ESR (erythrocyte sedimentation rate) decreased to 9.9 mm/h and 11.5 mm/h in the first and second groups, respectively, indicating an improvement in hematological parameters and a reduction in inflammatory activity.

The fibrinogen level decreased to 3.3 g/L in the first group and 3.8 g/L in the second group, indicating the restoration of normal blood clotting. The prothrombin index (PTI) also decreased, amounting to 94.1 sec in the first group and 97.8 sec in the second group, reflecting the normalization of the blood's rheological properties.

After performing a series of diagnostic and emergency therapeutic interventions, the patients showed positive dynamics: the headaches, dizziness, nausea, and vomiting decreased, and the body temperature returned to physiological norms. General brain and meningeal symptoms gradually regressed. In patients with meningitis, cerebrospinal fluid pressure gradually decreased, approaching normal values.

The use of this method significantly accelerated the process of epithelialization of the trepanation cavity, which contributed to a reduction in the duration of postoperative rehabilitation for the patients.

4. Conclusions

Thus, early hospitalization of patients at the onset of the disease, comprehensive preoperative preparation, emergency surgical intervention, postoperative intensive therapy with the use of hyperbaric oxygenation (HBO) and antioxidants combined with plasmapheresis, as well as continuous monitoring of vital functions, contribute to achieving positive clinical outcomes.

In group I, 40.4% of patients showed a positive effect, with improved speech perception and a decrease in tonal

hearing thresholds to 15 dB. Biochemical parameters normalized by the 18±2.8th day of the patients' stay in the hospital.

In group II, 59.6% of patients showed improved hearing on speech testing. A decrease in hearing thresholds from 10 to 25 dB at high frequencies was noted. By the 14.6±1.8th day of hospitalization, the biochemical parameters of the patients returned to normal values.

The results obtained confirm the effectiveness of the selected comprehensive diagnostic and therapeutic approaches and can serve as a basis for further optimization of treatment strategies.

REFERENCES

- [1] Babaev S.Yu., Novozhilov A.A., Abubakirov T.E., Mitrofanova N.N., Kozarenko E.A., Shakhov A.V. Microbiota of the tympanic cavity in patients with chronic purulent otitis media. / Russian Otorhinolaryngology 2019; 18; 3(100) 22-26.
- [2] Bakulina L.S., Mashkova T.A., Zemskov A.M., Maltsev A.B., Nerovny A.I., Zhdanova I.Yu. Dynamics of free-radical oxidation in purulent-inflammatory diseases of the middle ear. Journal: Bulletin of Otorhinolaryngology. 2019; 84(4): 33 38.
- [3] Gadzhimirzaev G.A., Dzhamaludinov Yu.A. et al. Diagnostics and treatment of otogenic intracranial complications. // Vestn. otorinolar 2016. 5; 8-11.
- [4] Efuni S.N. Guide to hyperbaric oxygenation. -M.: Medicine, 1986. -285 p.
- [5] Karneeva O.V., Kononov G.A., Doroshenko N.E. et al. Application of hemapheresis methods in otolaryngology. / Kremlin medicine. -2002. - No. 2. - P. 60~61.
- [6] Kozhantaeva S.K., Ismagulova E.K., Ospanova G.A. Hearing impairment in chronic otitis media. Modern Medicine No. 4 (23) 2021, 30-32.
- [7] Kulmakov S.A., Soldatsky Yu.L., Polunin M.M., Minasyan V.S., Edgem S.R. Ivanenko A.M., Zhilina S.V. Bacterial microbiota in exacerbation of chronic purulent otitis media in children Bulletin of Otolaryngology. 2023; 88(5): 7 11.
- [8] Muminov, A. I., Zh. A. Khatamov, and R. S. Masharipov. "Antioxidants and hyperbaric oxygenation in the treatment of sensorineural hearing loss." Bulletin of otolaryngology 5 (2002): 33.
- [9] Palchun, V. T., Guseva, A. L., Derbeneva, M. L., Guseva, O. A. Intracranial complications of inflammatory diseases of the nose and ear: meningitis and brain abscesses in adults. Journal: Bulletin of otolaryngology. 2019; 84 (6): 61 68.
- [10] Rondaleva A.V. Clinical and pathogenetic features and outcomes of otogenic intracranial complications in acute and chronic purulent otitis media. Journal of Russian Otolaryngology. 2022; 21; 3(118)-80-85.
- [11] Khatamov, Zh.A & Amonov, Sh.E & Nasretdinova, M.T & Khaitov, A.A. (2024). Main Directions in Diagnostics and Treatment of Complicated Forms of Chronic Purulent Otitis Medium. Otorhinolaryngology. Eastern Europe. 14. 358-367. 10.34883/PI.2024.14.3.018.
- [12] Kholmatov D. I. The ratio of conductive and sensorineural components of hearing loss in patients with hearing impairment: diss. ... Doctor of Medical Sciences. Dushanbe, 2004. 241 p.
- [13] Andrea Colletini, Federica Zoccali, Christian Barbato, Antonio Minni. Hyperbaric Oxygen in Otorhinolaryngology: Current Concepts in Management and Therapy. Oxygen 2024, 4(2), 150-162; <https://doi.org/10.3390/oxygen4020010> Submission received: 26 March 2024 / Revised: 17 April 2024 / Accepted: 22 April 2024 / Published: 26 April 2024.
- [14] Balan S., Viswanatha B. Microbiology of chronic suppurative otitis media: a prospective study in a tertiary care hospital. Journal of Otolaryngology-ENT Research. 2017; 9; 1: 1–4.
- [15] Daga Ruiz, D., Fonseca San Miguel, F., González de Molina, F.J. et.al. Plasmapheresis and other extracorporeal filtration techniques in critical patients Medicina Intensiva. 2017, 41 (3): 174–187.
- [16] Dubey, S. P., Larawin V., Molumi C. P. Intracranial spread of chronic middle ear suppuration // Amer. J. Otolaryngol. - 2010. - Vol. 31, № 2. - P. 73-77.
- [17] J.A.Khatamov. (2024). Results of complex treatment for chronic purular epitympanitis with complications. World Bulletin of Public Health, 35, 88-90. Retrieved from <https://scholar.express.net/index.php/wbph/article/view/4330>.
- [18] Nasretdinova Makhzuna Takhsinovna, Xatamov Jahongir Abruevich, Khayitov Alisher Adhamovich, & Dustboboev Dilshod Sadulaevich. (2023). Complex Treatment of Complicated Chronic Purulent Epitympanitis. Texas Journal of Medical Science, 22, 15–17. <https://doi.org/10.62480/tjms.2023.vol22.pp15-17>.
- [19] Nasretdinov T. Kh., Khatamov Zh. A., Mukhamadiev O. Sh. Double otogenic brain abscess in a 14-year-old child // Bulletin of Otorhinolaryngology. – 2007. – No. 2. – S. 60-61.
- [20] Xatamov J.A, Xayitov A.A, Boltayev A.E, & Davronov U.F. Comprehensive diagnosis and treatment of chronic purulent otitis media with complications. World Bulletin of Public Health, 28, (Nov. 2023), 73-75. Retrieved from <https://scholarexpress.net/index.php/wbph/article/view/3401>.
- [21] Shane R. Sergent; John V. Ashurst. Plasmapheresis National Library of Medicine. July 10, 2023.
- [22] Zina Bakir A. Study of Bacterial Isolates and their Susceptibility Pattern in Chronic Suppurative Otitis Media. IOSR Journal of Pharmacy and Biological Sciences. 2015; 10; 6; I: 1–5.