

# Surgical Treatment of Complicated Sacrum Tumors Annotation

Polatova Djamilya Shogayratovna<sup>1</sup>, Alimov Ijod Rustamjonovich<sup>2</sup>, Khamrokulov Bekzod Bahodirovich<sup>3</sup>

<sup>1</sup>Doctor of Medical Sciences, Head of the Department of Oncology and Medical Radiology, Tashkent Dental Institute, Tashkent, Uzbekistan

<sup>2</sup>Doctor of Philosophy in Medical Sciences, Associate Professor, Department of Neurosurgery, Center for the Development of Professional Qualification of Medical Workers, Tashkent, Uzbekistan

<sup>3</sup>Basic Doctoral Student, Department of Neurosurgery, Center for the Development of Professional Qualification of Medical Workers, Tashkent, Uzbekistan

**Abstract** Tumor lesion of the sacrum with the presence of compression of the nerve roots sharply worsens the quality of life of patients. Surgical treatment of tumors of this localization has a number of complex tasks, including radical removal of the tumor with low blood loss, release of nerve roots and restoration of the integrity of the pelvic ring.

**Keywords** Sacral tumors, Surgical treatment

## 1. Introduction

Tumor lesions of the sacrum are relatively rare and account for 1-7% of all spinal tumors. Plasmocytomas, chordomas and chordosarcomas predominate among sacral tumors, as well as tumors in other bone skeletal localities. The detection of tumors of this localization is usually carried out when the tumor reaches a significant size. Therapeutic tactics depend to a certain extent on the aggressiveness of the tumor, its histological characteristics, and its spread to surrounding tissues. [2] After radical removal of tumors, the recurrence rate is much lower, the life expectancy is much longer. [3]

Radical surgical removal of sacral tumors requires performing volumetric operations, during which the stability of the pelvic ring is disrupted, nerve structures may be damaged and a large amount of circulating blood may be lost. With such interventions, decompression of nerve roots is performed, the tumor is removed, the spine with the pelvic ring is fixed. [4]

## 2. The Purpose of the Study

Development and implementation of surgical interventions involving radical removal of sacral tumors without major blood loss, decompression of nerve structures, fixation of the spine.

## 3. Materials and Methods of Research

The study was conducted at the clinical bases of RSNPMTSOIR and RSNPMTSNH in 36 patients treated in the period 2010-2020. We have divided the patients into 2 groups. Group 1 consisted of 13 patients who underwent surgery to remove the tumor in a single unit. Of these, 10 patients had large tumors with lesions of the entire sacrum (SI–SV vertebrae), 2 patients had lesions of the upper sacral vertebrae (SI–SIII), 1 patient had lesions of the lower sacral vertebrae (SIII–SV). Lumbo-pelvic fixation was performed in 12 patients after removal of the tumor. Group 2 consisted of 23 patients in whom the tumor was removed by "lumping". In 10 of them, large tumors with lesions of the entire sacrum (SI–SV) were detected, in 8 patients of the upper sacral vertebrae (SI–SIII), in 5 patients of the lower sacral vertebrae (SIII–SV). Lumbo-pelvic fixation was performed in 6 patients after removal of the tumor.

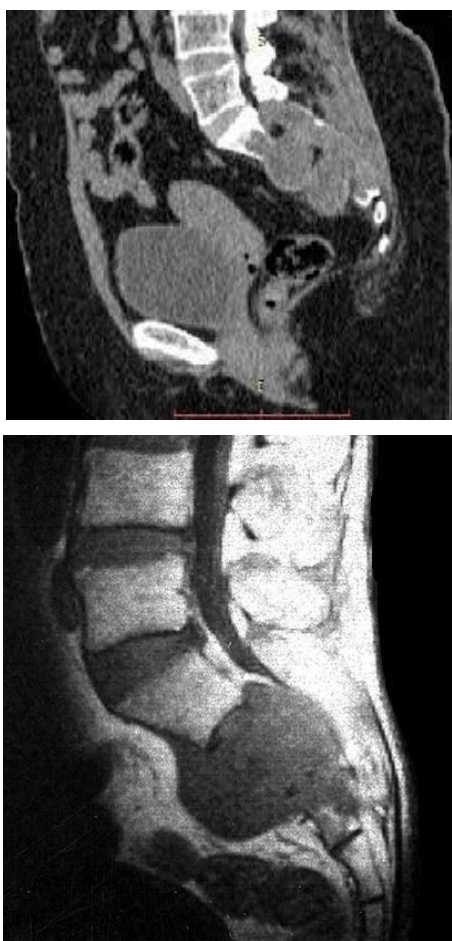CT, MRI, and electroneuromyography were performed from instrumental examination methods. Before the operation, clinical and neurological symptoms were comprehensively studied. Also, in the early postoperative period, all patients underwent control studies, in particular radiography, CT or MRI, neurological symptoms were evaluated in detail.

In the long-term period, the results of treatment of 13 patients (group 1) who had a tumor removed by a "block" were compared with the results of treatment of 23 patients (group 2) with sacral tumors operated on for removal by "lumping" the tumor.

The average duration of follow-up was 3 years. Data in the long-term period were obtained in 29 patients. All patients underwent control MSCT and MRI.

## 4. The Results of the Study

The earliest symptom of sacral tumors was local pain in the sacral region. With the progression of the tumor, root symptoms appeared. With compression of the SI roots, typical manifestations of sciatica, SII–SIV roots, pelvic organ disorders occurred, in far advanced stages, radiculopathy of all sacral roots (SI–SV), pronounced root pain were typical. On a 5-point scale in group 1, radicular pain syndrome averaged 2.3 points, sensory radicular disorders 3.1 points, motor radicular disorders 3 points; on a 3-point scale, pelvic disorders before surgery averaged 2.2 points. In group 2, radicular pain syndrome was 2.5 points, sensory radicular disorders 3.3 points, motor radicular disorders 3.4 points; on a 3-point scale before surgery, pelvic disorders averaged 2.1 points.



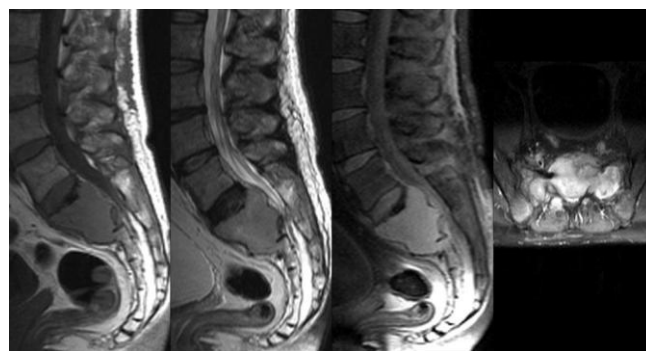
**Figure 1-2.** MSCT, MRI of a tumor lesion of the sacral vertebrae

With the help of MSCT and MRI, both the sacral tumor itself and the direction and volume of its spread were diagnosed. In most situations with sacral tumors, the combined use of MSCT and MRI was necessary. According to the MSCT data, it was possible to fully assess the bone structure of the sacrum, the structure of the pelvis. The advantage of MRI was the assessment of soft tissues, the tumor itself, and neural structures. According to the results of MSCT and MRI, surgical intervention, access, and necessary fixation were planned (Fig. 1, 2).

Radioisotope scanning for the study of metastatic lesions in other bones has been rarely used recently due to its low information content. Assuming a metastatic lesion, spiral MSCT of the thoracic and abdominal cavities was included in the standard study.

Indications for performing radical surgery were determined depending on the size and location of the tumor, the degree of its aggressiveness. In group 1, the tumor was removed totally, by a block with the capture of unaffected tissues along the periphery. In group 2, the tumor was removed by lumping or intra-tumor curetting to unaffected tissues (the technique of operations was described by us earlier). Such removal, even if it is total according to oncological principles, is considered non-radical.

In the presence of SI–SV roots passing through the sacrum and the need to preserve them (Fig. 3), two-stage operations were used for radical removal of the tumor by a block in group 1 in all patients.



**Figure 3.** MRI. The tumor affects the SI-SII vertebrae with epidural and presacral spread of the tumor

The first stage is trans-femoral selective angiography using the Seldinger method of pelvic vessels, followed by embolization of the vessels "feeding" the tumor. In this case, an angiographic study was performed to determine the volume and number of feeding vessels of the tumor, taking into account the localization of the tumor process, embolization of sacral vessels was performed to eliminate intraoperative bleeding during radical removal of the tumor. Angiographically significant vessels at risk of intraoperative damage are branches of the internal iliac artery (a.iliaca inferior), lateral sacral artery (a.sacralis lateralis) and inferior gluteal artery (a.glutea inferior). All the listed patients underwent angiography of sacral vessels in the first stage, without complications. It should be noted that all the parietal branches of the internal iliac artery were anastomosed with each other.

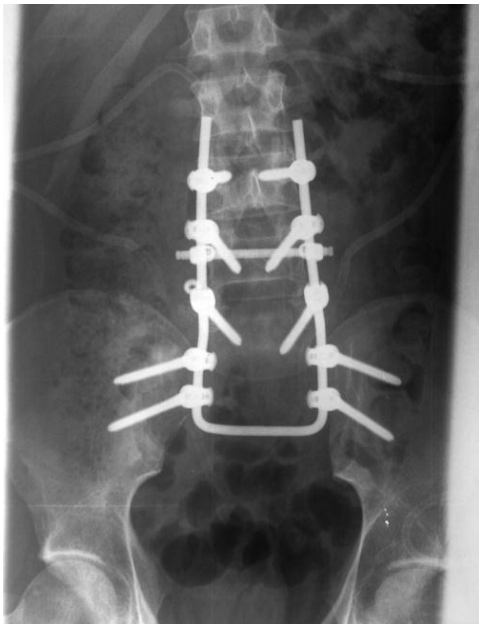The second stage: Radical removal of the tumor process of the sacrum. In this case, the localization, prevalence and extent of the tumor process, the integrity of the pelvic ring bones, including the sacrum, took place. A median incision was made from the coccyx to the LV level. The gluteus maximus was crossed laterally from the place of its attachment to the sacrum. The pear-shaped muscles lying under it were cut off. The upper and lower gluteal arteries, genital and posterior cutaneous nerve of the thigh were isolated and preserved.

They crossed the anal-coccygeal, sacro-tubercular, sacro-spinous ligaments, as well as the muscles that attach to the coccyx. The posterior bone structures of the sacrum were subperiostally isolated, the sacro-spinal muscles were transversely crossed.

LV or SI-SV laminectomy was performed, the dural sac and SI-SV roots were exposed. The posterior bone structures, together with the tumor affecting them, were removed with a block. The dural sac and roots were carefully isolated and separated from the posterior part of the tumor.

After removal of the tumor, the transpedicular system was fixed in the bodies LIII, LIV or LV (depending on the lesion of adjacent lumbar vertebrae) and the crests of the iliac bones. A polyaxial transpedicular system was necessarily used. Screws 7-9 cm long were installed in the iliac crest, which, like screws in bodies LIII, LIV, were fixed to the rod.

In group 1, all tumors were removed totally by a block. After the operation, all patients underwent a control MSCT and X-ray examination.

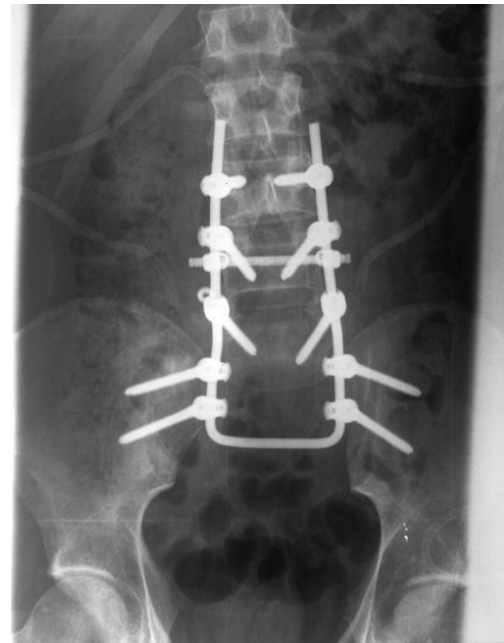

**Figure 4.** Postoperative X-ray of the patient after lumbo-pelvio fixation

In group 2 out of 10 patients with large tumors and lesions of the entire sacrum, 6 had tumors removed totally, the rest partially. Out of 8 patients with a tumor of the upper sacral vertebrae, tumors were totally removed in 6, in 2 — partially. In all patients with lesions of the lower sacral vertebrae, a total removal of the tumor was performed.

Block removal was performed only in 4 patients with lesions of the lower sacral vertebrae, in the rest - tumors were removed by lumping.

According to histological studies in group 1, chordoma was found in 2 patients, osteosarcoma in 2, chondrosarcoma in 1, plasmocytoma in 7. In group 2, chordoma was found in 2 patients, osteosarcoma in 1, chondrosarcoma in 3, osteoblastoclastoma in 6, aneurysmal bone cyst in 4, giant cell tumor in 2, hemangioendothelioma in 1, angiosarcoma in 1, plasmocytoma in 2, cancer metastasis in 1.



**Figure 5.** Postoperative MSCT image of the patient after lumbo-pelvio fixation

All patients after surgery were recommended to carry out fractional irradiation of the sacrum at a dose of 65Gy. In the presence of tumors amenable to chemotherapy, it was carried out in an oncological dispensary.

Before discharge of patients in group 1 on a 5-point scale, radicular pain syndrome averaged 3.9 points, sensory radicular disorders - 4.1 points, motor radicular disorders - 3.9 points; on a 3-point scale, pelvic disorders averaged 2.4 points.

In group 2, on a 5-point scale, radicular pain syndrome averaged 3.8 points, sensory radicular disorders - 3.9 points, motor radicular disorders - 3.8 points; on a 3-point scale, pelvic disorders averaged 2.3 points.

Information about the timing of continued tumor growth after surgery was statistically analyzed using the Kaplan-Meier method.

In group 1, there were no relapses during the follow-up period up to 2 months, after 6 months, tumor recurrence occurred in almost 50% of patients, after 14 months - in almost all patients. In group 2, there were no relapses before 3 months, after 4 months, tumor recurrence was detected in almost 70% of patients, after 6 months - in all patients. Thus, the predominance of tumor recurrence in the early period in patients after non-radical removal of the tumor by "lumping" is clearly visible.

## 5. Discussion

Previously, it was found that only radical interventions provide a significant increase in the average life expectancy of patients with sacral tumors. [5] The technique of radical resection of sacral tumors with a block was introduced by B. Stener, B. Gunterberg. [6] The authors emphasized that the purpose of the operation is to resect the tumor with a sacral

block with the inclusion of unaffected tissues around the circumference of the tumor. In accordance with generally accepted principles, sacral resection should be performed one segment above the rostral border of the tumor. High resection of the sacrum is technically more complicated, associated with large blood loss, instability of the pelvic ring and lumbar spine, functional disorders due to damage to the SI-SV roots. [7] Sacral resection using combined posterior and anterior transperitoneal access was described by S. McCarty and co-authors. [8] Currently, many authors also prefer two-stage interventions. [9] Currently, the most popular technique of high resection of the sacrum by Stener and Gunterberg.

Recently, neurosurgeons, performing sacral resection, preserve all sacral roots. [10] At the same time, it is impossible to remove the sacrum in a single block and not damage the roots when using a single access. In this regard, combined front and rear accesses are used. [11] After a high resection of the sacrum, the stability of the pelvic ring, the connection of the lumbar spine with the sacrum, is always disrupted. Upon completion of the stage of tumor removal and high resection of the sacrum, a stabilizing operation is necessary. [12] Our studies have also convincingly demonstrated an increase in the duration of the period without recurrence of the tumor after its radical removal.

Thus, the results of treatment and prognosis in the presence of malignant sacral tumors are better after performing radical operations, reliable intraoperative fixation of the spine with a pelvic ring, the use of radiation treatment and chemotherapy after surgery.

## REFERENCES

- [1] Long-term outcomes following en bloc resection for sacral tumor: a retrospective analysis of 93 cases / Z.Y. Zhang, C.F. Fu, Y.X. Yang [et al.] // *Orthopedics*, 2011; 8(34): 403–407.
- [2] A retrospective review of long anterior fusions to the sacrum / Y.P. Lee, H. Ghofrani, G.J. Regev, S.R. Garfin // *Spine J.*, 2011; 11(4): 290–294.
- [3] Sacral tumor resection: the effect of surgical staging on patient outcomes, resource management, and hospital cost / M.J. Brown, D.J. Kor, T.B. Curry [et al.] // *Spine*, 2011; 1(36): 1570–1578.
- [4] Asavamongkolkul A. Wide resection of sacral chordoma via a posterior approach / A. Asavamongkolkul, S. Waikakul // *Int. Orthop*, 2012; 36(3): 607–612.
- [5] Trans-sacral resection of a solitary fibrous tumor in the pelvis: report of a case / H. Katsuno, K. Maeda, T. Hanai [et al.] // *Surg. Today*, 2011; 41(11): 1548–1551.
- [6] Stener B. High amputation of the sacrum for extirpation of tumors. Principles and technique / B. Stener, B. Gunterberg // *Spine*, 1978; 3: 351–366.
- [7] Ahuja S.K. Treatment strategy for chondromyxoid fibroma of the sacrum / S.K. Ahuja, S.P. McCanna, E.M. Horn // *J. Clin. Neurosci*, 2011; 18(11): 1550–1552.
- [8] The surgical treatment of presacral tumors: a combined problem / C. McCarty, J. Waugh, C. Mayo, M. Coventry // *Proc. Staff. Meet Mayo Clin*, 1952; 27: 73–84.
- [9] Reconstruction of the pelvis and lumbar-pelvic junction using 2 vascularized autologous bone grafts after en bloc resection for an iliosacral chondrosarcoma / E. Mendel, J.L. Mayerson, N. Nathoo [et al.] // *J. Neurosurg. Spine*, 2011; 15(2): 168–173.
- [10] Choudry U.H. Functional reconstruction of the pelvic ring with simultaneous bilateral free fibular flaps following total sacral resection / U.H. Choudry, S.L. Moran, Z. Karacor // *Ann. Plast. Surg*, 2006; 57(6): 673–676.
- [11] En bloc resection of primary sacral tumors: classification of surgical approaches and outcome / D.R. Fourny, L.D. Rhines, S.J. Hentschel [et al.] // *J. Neurosurg. Spine*, 2005; 3(2): 111–122.
- [12] Reconstruction after total sacrectomy: early experience with a new surgical technique / I.D. Dickey, R.R. Hugate Jr., B. Fuchs [et al.] // *Clin. Orthop. Relat. Res.*, 2005; 438: 42–50.