

The Role of Intraoperative Monitoring of Visual Evoked Potentials in Patients with Tumors of the Chiasma-Sellar Region

Akmaljon Mukhamedov¹, Uygun Altybaev¹, Gayrat Kariev², Rano Ismailova³

¹Department of Oncology, Republican Specialized Scientific Practical Medical Center for Neurosurgery, Tashkent, Uzbekistan

²Director of the Republican Specialized Scientific Practical Medical Center for Neurosurgery, Tashkent, Uzbekistan

³Department of Spinal Neurosurgery, Republican Specialized Scientific Practical Medical Center for Neurosurgery, Tashkent, Uzbekistan

Abstract The microsurgical removal of tumors within the chiasm-sellar region is a crucial intervention to minimize recurrences and enhance the long-term quality of life for affected individuals. This study explores the efficacy of microsurgical procedures in conjunction with intraoperative monitoring of visual evoked potentials for assessing and preserving the functional integrity of the visual pathway structures during tumor removal. **Methods:** A retrospective analysis was conducted on 117 patients who underwent microsurgical interventions for chiasm-sellar region tumors at the Republican Scientific-Practical Medical Center of Neurosurgery from 2014 to 2021. Surgical procedures, primarily involving transcranial approaches, were performed with meticulous intraoperative monitoring of visual evoked potentials. **Results:** In the early postoperative period, an investigation into visual functions revealed notable outcomes. Among the 117 patients, 85 experienced an improvement in their visual functions, 25 patients maintained their preoperative levels, and 7 patients demonstrated a decline in vision. These findings underscore the positive impact of the surgical interventions on visual outcomes for the majority of patients. **Conclusion:** Microsurgical removal, coupled with intraoperative monitoring of visual evoked potentials, emerged as a promising strategy for achieving favorable long-term outcomes. This approach not only contributed to reduced recurrences but also facilitated a stable improvement in the quality of life for patients. The use of intraoperative monitoring was deemed objective and highly informative, preventing and minimizing visual complications associated with surgical interventions.

Keywords Pituitary gland adenoma, Meningioma, Craniopharyngioma, Chiasm glioma, Tumors of the chiasma-sellar region, Intraoperative monitoring

1. Introduction

The prompt diagnosis and treatment of tumors within the chiasmatic-sellar region of the brain represent a contemporary challenge in the fields of neurosurgery and neurology. Neoplasms in the chiasmatic-sellar region (CS) are notable among intracranial tumors, constituting 15-18% of cases [1] [3] [4]. Predominantly, benign tumors of the pituitary gland are the most frequent within the sellaturcica region [1] [2], with the majority measuring less than 10-15 mm and remaining confined to the sellaturcica [5]. In these instances, clinical manifestations primarily result from the hormonal activity of the tumor.

However, when tumors exceed these dimensions, clinical symptoms emerge due to the compression of adjacent structures [6]. These symptoms include headaches, impaired visual function, reduced secretion of tropic hormones from

the adenohypophysis, and hyperprolactinemia. Deciding on the appropriate treatment approach requires assessing the tumor's hormonal activity and topographic and anatomical characteristics [7].

The clinical nuances of CS region tumors, the selection of surgical strategies, and the prognosis of the disease hinge on factors such as tumor localization, size, growth characteristics, histological nature, and the degree of associated hydrocephalus. A thorough analysis of comprehensive examination results, encompassing CT and MRI scans, in conjunction with clinical data, is crucial for determining the optimal treatment plan and achieving enduring positive outcomes.

Employing visual function monitoring during tumor removal allows for the timely identification of excessive irritation to the visual pathway, enabling the implementation of appropriate measures [8]. Consequently, this approach contributes to vision preservation and preventing irreversible damage to the visual system.

The paramount objective of our research is to investigate the role of intraoperative monitoring of visual evoked potentials in patients with tumors located in the chiasm-sellar region. Understanding the impact of this monitoring technique in the context of chiasm-sellar tumors is crucial for advancing our knowledge in neurosurgery and optimizing patient care. This study aims to contribute valuable insights into the significance of visual evoked potential monitoring during surgical interventions in this patient population.

2. Materials and Methods

A total of 117 patients with tumors in the chiasm-sellar region (CSR) were admitted for inpatient treatment at the Republican Scientific-Practical Medical Center of Neurosurgery from 2014 to 2021. Surgical interventions were performed on all patients utilizing transcranial approaches, with intraoperative monitoring of visual evoked potentials.

Comprehensive preoperative and postoperative neurological examinations, cranial radiography, computed tomography (CT), magnetic resonance imaging (MRI), echoencephalography, electroencephalography, visual evoked potentials, and other neurophysiological assessments were conducted for all patients. Diagnostic procedures were carried out in accordance with established standards for brain tumor evaluation.

The Karnofsky Performance Status scale assessed the neuro-oncological patients' overall condition, evaluated upon admission and discharge. Neurological status was assessed upon admission, in the early postoperative period, and at discharge. In addition to the Karnofsky scale assessment, the level of consciousness was evaluated using the classic classification of consciousness disorders. The severity of global and focal neurological symptoms was also assessed.

Histological analysis of the tumor was performed for all patients who underwent radical surgery to determine the nature of the neoplasm. This comprehensive approach aimed to provide a thorough understanding of the patient's neurological and oncological status before, during, and after surgical interventions, enhancing the overall outcomes assessment.

3. Results and Discussion

Table 1. Distribution of Patients by Gender and Age

Gender	Number of Patients (n=117)	
	Abs	%
Male	64	54,70%
Female	53	45,29
AverageAge	30-35	

The study included a diverse age range of patients, spanning from 6 to 60 years, with an average age of 30-35 years. The male-to-female ratio was 1.2:1, and there was no statistically significant correlation between age and gender (Table 1).

The assessment of patients' quality of life was conducted utilizing the "Quality of Life Assessment for Patients with CNS Disorders" scale, which relies on the Karnofsky scoring system. This scale is a widely recognized tool in medical research for evaluating the functional status and well-being of patients with various neurological conditions. In our study, the results revealed that 85% of the participants exhibited an "average quality of life" based on the scale's criteria. This indicates that most patients maintained a moderate level of daily functioning and overall well-being despite the challenges posed by tumors in the chiasm-sellar region.

Furthermore, 12.4% of the patients were identified as having a "satisfactory quality of life." This subset of individuals likely experienced a higher level of functioning and satisfaction with their daily lives than those categorized under the "average" designation. Recognizing a segment of the patient population with a satisfactory quality of life underscores the potential variability in outcomes and the importance of considering individual patient experiences and perspectives.

These findings shed light on the nuanced impact of chiasm-sellar region tumors on the day-to-day lives of affected individuals. The assessment not only provides valuable insights into the patients' overall well-being but also serves as a foundation for understanding the potential correlations between the quality of life and other clinical parameters, such as the nature of the tumors, treatment approaches, and postoperative outcomes.

Disease onset was characterized by symptoms such as decreased optic nerve function and increased intracranial pressure. In the preoperative period, 19 patients did not exhibit any visual impairments, 46 patients experienced reduced visual acuity in one eye, often accompanied by bitemporalhemianopsia in 36 patients, and 16 patients presented with amaurosis in one eye (Table 2). Throughout all stages of the operation, monitoring of visual evoked potentials of the optic nerves and chiasm was conducted.

Table 2. Preoperative Visual Impairments

Visual Impairment	Number of Patients	
	Abs.	%
No visual impairments	19	16.24%
Reduced visual acuity	36	30.77%
Bitemporalhemianopsia	46	39.32%
Amaurosis	16	13.67%

The incorporation of visual evoked potential monitoring throughout the surgical procedure aimed at ensuring the preservation of visual function and preventing potential damage to the visual pathways. The observed distribution of visual impairments underscores the importance of such intraoperative monitoring in tailoring surgical strategies for optimal patient outcomes.

By histological analysis, adenomas of the pituitary gland were identified in 44 patients, constituting 37.60% of the total cohort. Additionally, meningiomas were detected in 27

patients (23.07%), craniopharyngiomas in 27 patients (23.07%), chiasm gliomas in 11 patients (9.40%), and other types in 8 patients (6.83%) (Figure 1).

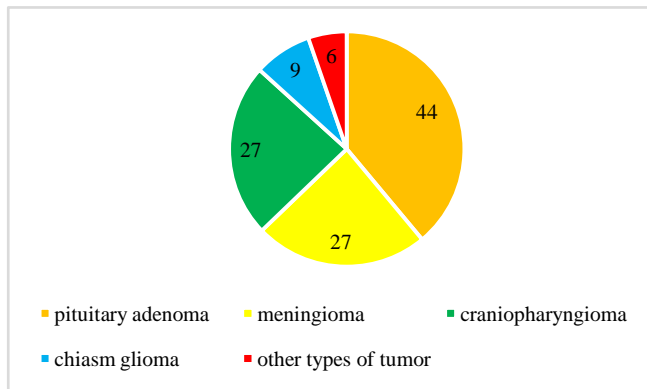


Figure 1. Distribution of Tumor Types

This histological diversity underscores the heterogeneous nature of tumors within the chiasm-sellar region. Adenomas, being the most prevalent, highlight the significance of pituitary gland involvement in this patient population. The presence of meningiomas, craniopharyngiomas, gliomas, and other tumor types emphasizes the complexity and varied origins of lesions affecting this anatomical region.

In the early postoperative period, an investigation into visual functions revealed notable outcomes. Among the 117 patients, 85 experienced an improvement in their visual functions, 25 patients maintained their preoperative levels, and 7 patients demonstrated a decline in vision. These findings underscore the positive impact of the surgical interventions on visual outcomes for the majority of patients.

The research further demonstrated that monitoring visual evoked potentials played a crucial role in preventing complications associated with prolonged effects on the optic nerves and chiasm. This monitoring approach proved to be instrumental in identifying and addressing potential complications, emphasizing its significance in preserving and optimizing visual function during and after surgery.

Upon examining the degree of radicality of the surgical procedures using postoperative CT scans, it was determined that over 68% of primary surgical interventions concluded with subtotal tumor removal. Partial removal occurred in 3% of cases, while total removal was achieved in 27.5% of cases. This distribution highlights the complexity of these surgeries and the challenges in achieving complete tumor resection, underscoring the need for individualized approaches to optimize outcomes based on the nature and extent of the tumors. The utilization of postoperative imaging contributes crucial insights into the efficacy of the surgical interventions and aids in refining future treatment strategies for patients

with chiasm-sellar region tumors.

4. Conclusions

Microsurgical removal of tumors in the chiasm-sellar region results in fewer recurrences and contributes to a sustained improvement in the quality of life for patients in the long term.

Intraoperative monitoring of visual evoked potentials is considered an objective and highly informative method for assessing the functional status of the visual pathway structures during removing tumors in the chiasm-sellar region.

The intraoperative monitoring of visual evoked potentials prevents and reduces the incidence of visual complications during surgical interventions. This technique proves instrumental in preserving visual function and minimizing adverse outcomes associated with the surgical removal of tumors in the chiasm-sellar region.

REFERENCES

- [1] Kalinin PL, Fomichev DV, Kutin MA, Kadashev BA, Astaf'eva LI, Shkarubo AN, Alekseev SN, Fomochkina LA. Endoskopicheskayaendonazal'nayakhirurgiya adenoma gipofiza (opyt 1700 operatsiy). *Voprosynevrokhirurgiiim*. N.N. Burdenko. 2012; 76(3): 26-33. (In Russ.)
- [2] Adenomygipofiza: klinika, diagnostika, lecheniye. Pod red. prof. BA Kadasheva. M.—Tver': Triada, 2007; 368. (In Russ.)
- [3] Bersnev VP, Khachatryan VA, Mamatkhanov MR, Matsko DE. *Khirurgiyaopukholeytret'yegozheludkagolovnogomozga*. 2006. (In Russ.)
- [4] Chicani CF, Miller NR. Visual outcome in surgically treated suprasellarmeningiomas. *J Neuroophthalmol*. 2003; 23: 3-10.
- [5] Fahlbusch R, Scott W. Pterional surgery of meningiomas of the tuberculum sellae and planumspenoidale: surgical results with special consideration of ophthalmological and endocrinological outcomes. *J Neurosurg*. 2002; 96: 235-243.
- [6] Klistorner AI, Gracham SL, Grigg J, et al. Objective perimetry using the multifocal visual evoked potential in central visual pathway lesions. *Br J Ophthalmol*. 2005; 89(6): 739-744.
- [7] Pulumati A, Dwarakanath BS, Verma A, Papineni RVL. Technological advancements in cancer diagnostics: Improvements and limitations. *Cancer Rep (Hoboken)*. 2023; 6(2): e1764. doi:10.1002/cnr2.1764.
- [8] Solli E, Turbin RE. Primary and Secondary Optic Nerve Sheath Meningioma. *J NeurolSurg B Skull Base*. 2021; 82(1): 27-71. doi:10.1055/s-0041-1723801.