

Preoperative Diagnosis of Patients with Nodular Goiter

Salokhiddinov Jurabek Saidakhmadovich

Samarkand State Medical University, Samarkand, Republic of Uzbekistan

Abstract The study included the results of an examination of 112 patients with toxic forms of goiter. Methods for complex preoperative diagnosis of toxic forms of goiter should include ultrasound and CT, which make it possible to non-invasively obtain information about the size, topography, echostructure of the thyroid gland and pathological formations detected in it, as well as to study the condition of the zones of regional lymphatic drainage. Radionuclide scanning is indicated for autonomous thyroid nodules, relapse of toxic goiter, and atypical localization of the thyroid gland. A hormonal study of thyroid function includes determining the concentration of TTH, T3, T4, thyroid binding globulin and the titer of antibodies to thyroglobulin.

Keywords Toxic goiter, Research methods

1. Introduction

According to the World Health Organization, "more than 750 million people worldwide are affected by thyroid pathology, while patients with diffuse and mixed toxic goiter occupy the first place among thyroid diseases." Due to the lack of a downward trend in the number of patients and the existence of endemic regions, where the incidence rate varies from 1.2 to 9.0 per 100,000 population, thyroid diseases continue to be a serious medical and social problem, including in Uzbekistan, despite the long-term struggle with iodine deficiency.

At the present stage, the diagnosis of toxic goiter forms does not present significant difficulties, largely due to the emergence of non-invasive imaging methods, the information content of which reaches 95-100% in a complex application. At the same time, the lack of alertness leads to late diagnosis and, consequently, an increase in complicated forms of the disease.

2. Purpose of the Study

Optimization of diagnostic methods for toxic forms of thyroid diseases.

3. Material and Methods of Research

The study is based on the results of examination of 112 patients with toxic goiter forms who were admitted to the

surgical departments of the multidisciplinary clinic of Samarkand State Medical University and City Clinical Hospital No. 1 in the period from 2012 to 2021.

Female patients prevailed – 88 (78.6%), men – 24 (21.4%). The patients ranged in age from 21 to 65 years.

Out of 112 patients, 102 (91.1%) patients were diagnosed with toxic goiter for the first time, 10 (8.9%) patients had recurrent toxic goiter, of which 8 patients had primary relapse. Out of 10 patients, 6 patients underwent the first operation in our clinic in different years. 4 had a history of strumectomy in other hospitals. Postoperative recurrent goiter was detected up to 5 years in 7 patients and up to 10 years in 3. It should be noted that among 10 patients with recurrent toxic goiter, 3 patients had primary multi-node non-toxic goiter basedified within 3 years, the remaining 7 patients were operated earlier for diffuse toxic goiter.

The size of the degree of thyroid enlargement in patients with toxic goiter forms was evaluated according to the classification of O. V. Nikolaev based on ultrasound and palpation of the thyroid gland, and 43 (38.4%) patients were diagnosed with a toxic goiter form of II-III degree, 69 (61.6%) IV-V degree.

The severity of thyrotoxicosis was assessed on the basis of physical criteria according to the classification of V. G. Baranov: mild was detected in 35 (31.2%), moderate in 52 (46.4%) and severe in 25 (22.3%) patients.

Pathomorphologically, diffuse toxic goiter was detected in 50 (44.6%) patients, mixed toxic goiter in 39 (34.8%), toxic adenoma in 13 (11.6%) and recurrent toxic goiter in 10 (8.9%) patients.

Before being referred for surgery, patients were observed for a long time and received conservative therapy. Up to 1 year of treatment, 7 (6.2%) patients were treated, 29 (25.9%) patients were treated from 1 year to 3 years, and 76 (67.8%) patients were treated for more than 3 years.

* Corresponding author:
sammi-xirurgiya@yandex.com (Salokhiddinov Jurabek Saidakhmadovich)
Received: Nov. 1, 2023; Accepted: Nov. 26, 2023; Published: Dec. 2, 2023
Published online at <http://journal.sapub.org/ajmms>

4. Research Results and Discussion

All patients with toxic forms of goiter were examined according to a single comprehensive scheme, which included interviewing and examining the patient, taking blood for laboratory analysis and conducting an instrumental study.

When interviewing patients, they specified their profession, the nature of work and place of residence, their complaints, the time of their appearance, and the presence of thyroid diseases in relatives.

During the examination, attention was paid to the size and deformity of the neck (its configuration), the condition of the eyeballs, the presence or absence of finger tremor, and the condition of the skin (dryness, humidity, puffiness, pigmentation).

The presence of a nodular formation that shifts when swallowing in the projection of the thyroid gland of one or another density in the absence of cytological signs of neoplastic growth allowed us to think of a nodular goiter. At the same time, the presence of multiple formations in the thyroid gland, signs of infiltration of tissues on the neck indicated thyroid cancer, which required a thorough differential diagnosis.

Anamnesis collection and physical examination revealed ophthalmopathy, thyroid dysfunction, and the degree of its enlargement.

Most often, patients with toxic forms of goiter complained of neck pain (44.6%), limb tremor (63.4%), palpitation (56.2%), increased blood pressure (64.3%), weight loss (48.2%), and changes in the eyes.

The severity of the condition of patients with thyroid pathology was largely determined by concomitant diseases.

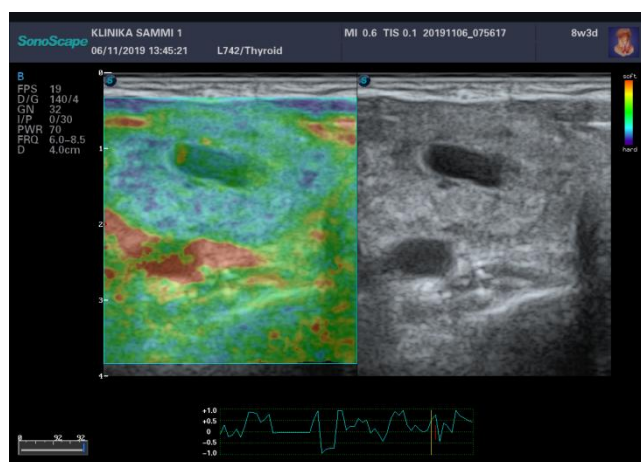


Figure 1. Thyroid ultrasound. In the left thyroid lobe, a nodular formation with a volume of up to 20 cm³ is determined

Coronary heart disease (22.3%), hypertension (20.5%), and diabetes mellitus (4.5%) significantly affected the prognosis of the disease course. Among patients with toxic goiter who received antithyroid therapy, a high percentage of cholelithiasis (25.0%), peptic ulcer of the stomach and duodenum (16.9%), chronic pancreatitis (13.4%), and chronic diseases of the large intestine (14.3%) were noted.

Ultrasound examination of the thyroid gland and areas of regional lymph outflow was performed in real time, i.e. at baseline and at different times after surgery (Fig. 1).

Ultrasound in the diagnostic algorithm of examination of patients with thyroid pathology has taken a leading place, allowing non-invasively to obtain reliable information about the size, topography, echostructure of the thyroid gland and the pathological formations detected in it, as well as to study the state of regional lymph outflow zones.

Ultrasound examination was performed in all 112 patients, and a fine needle puncture biopsy was performed in 49 (43.7%) patients with thyroid lesions. The puncture was performed without additional anesthesia with disposable needles for intramuscular injections. The material obtained during the puncture was examined by a cytologist. If follicular structures were detected during the examination of the node, then indications were given for performing scintigraphy.

Radionuclide scanning and scintigraphy were performed in 37 (33.0%) patients using radionuclides ¹³¹I or ^{99m}Tc. The study was performed using a scanner or gamma camera (scintigraphy) and the placement of the thyroid gland was determined. The size, distribution contours, and intensity of radionuclide accumulation indicated diffuse or focal thyroid damage, and functional activity of nodular formations. The minimum size of the nodular formation detected on the scan was 1 cm.

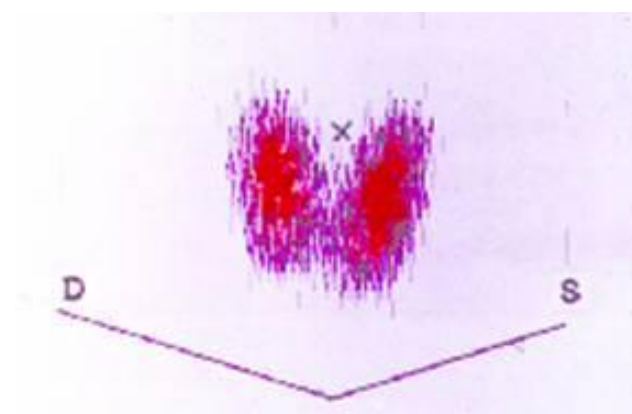


Figure 2. Thyroid scan. Diffuse toxic goiter

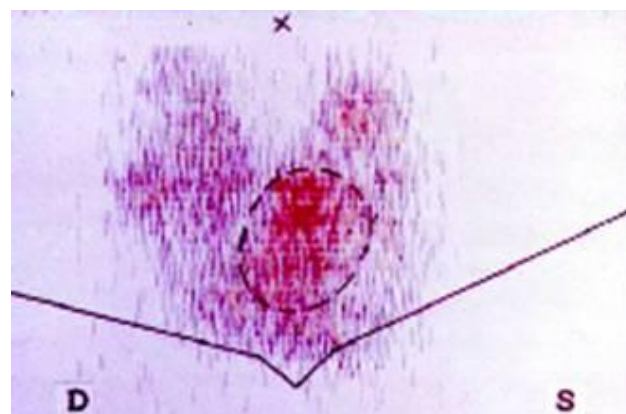


Figure 3. Thyroid scan. "Hot knot" in the left thyroid lobe. Toxic adenoma

Scanning is not a screening method and was performed for the following indications: - autonomous thyroid node (s) (toxic adenoma, nodular or multi-nodular toxic goiter); - recurrent goiter or thyrotoxicosis after thyroid surgery; - atypical localization of thyroid tissue or abnormalities of thyroid development (retrosternal goiter, thyroid dystopia, including goiter of the tongue root, hemiagenesis or thyroid agenesis (Fig. 2-3).

Computed tomography (CT) of the thyroid gland was performed in 52 (46.4%) patients. CT was performed for differential diagnosis of thyroid gland formations to exclude malignant tumors, the presence of primary multiple thyroid lesions, as well as for solving tactical issues (determining indications for the method of strumectomy depending on the stage of pathology development, localization, and the nature of complications) (Fig. 4,5).

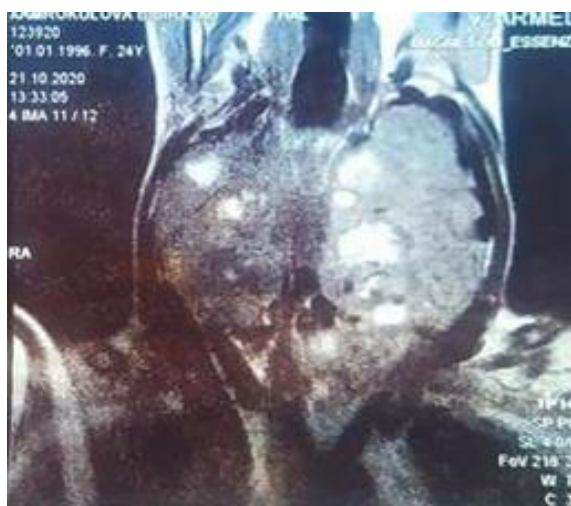

Figure 4. Thyroid CT scan. Multi-node goiter

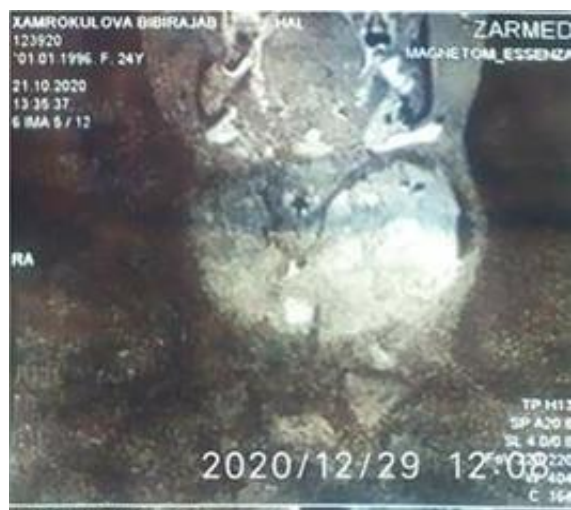

Figure 5. Thyroid CT scan. Toxic IV grade IV adenoma

The study of thyroid hormone function was performed in all 112 patients. For this purpose, the concentration of TSH, T₃, T₄, thyroid-binding globulin and anti-thyroglobulin antibody titer were determined. An increase in TSH levels suggested hypothyroidism, while a decrease in TSH levels

suggested thyrotoxicosis. An increase in T₃ and T₄ concentrations₄ confirmed the presence of thyrotoxicosis.

5. Conclusions

1. Methods of preoperative diagnosis of toxic goiter forms should include ultrasound and CT, which allow noninvasively obtaining information about the size, topography, and echostructure of the thyroid gland and the pathological formations detected in it, as well as studying the state of regional lymph outflow zones.
2. Radionuclide scanning is indicated for autonomous thyroid nodules, recurrent toxic goiter, and atypical thyroid localization.
3. Hormonal tests of thyroid function include determination of TSH, T₃, T₄, thyroid-binding globulin and anti-thyroglobulin antibody titer. An increase in TSH levels suggested hypothyroidism, while a decrease in TSH levels suggested thyrotoxicosis. An increase in T₃ and T₄ concentrations₄ confirmed the presence of thyrotoxicosis.

Information about the source of support in the form of grants, equipment, and drugs. The authors did not receive financial support from manufacturers of medicines and medical equipment.

Conflicts of interest: The authors have no conflicts of interest.

REFERENCES

- [1] Abdurakhmanov D. S., Rakhmanov Q. E., Davlatov S. S. Clinical questions extreme currents syndrome Mirizzi // Electronic innovation bulletin. – 2021. – №. 6. – P. 37-40.
- [2] Kurbaniyazov Z.B., Babajanov A.S., Zayniev A.F., Davlatov S.S. Factor analysis of recurrence of nodular goiter in residents living in an iodine-deficient region. // Problems of biology and medicine. - Samarkand. - 2019, - No. 3 (111). p. 58-62.
- [3] Bartalena, L. Management of hyperthyroidism due to Graves' disease: frequently asked questions and answers (if any) / L. Bartalena, L. Chiovato, P. Vitti // Journal of Endocrinological Investigation. - 2016. - Vol. 39. - P. 1105-1114.
- [4] Shin YW. et al. Diminished Quality of Life and Increased Brain Functional Connectivity. Patients with Hypothyroidism After Total Thyroidectomy // Thyroid. -2020. - Vol. 26, № 5. - P. 641-649.
- [5] Shukurullaevich A. D. et al. Quality of life of patients before and after surgical treatment of diffuse toxic goiter // Bulletin of Science and Education. – 2021. – №. 3-2 (106). – C. 80-87.
- [6] Schneider D.F. et al. Thyroidectomy as primary treatment optimizes body mass index in patients with hyperthyroidism // Ann Surg Oncol. - 2021. - Vol. 21, № 7. - P. 2303-2309.
- [7] Sulatanbaevich B. A. et al. Analysis of the results of surgical treatment of patients with thyroid nodules // Bulletin of

Science and Education. – 2019. – №. 4 (49). – C. 186-192.

research. – 2023. – №. 1 (79). – C. 37-40.

[8] Pirnazarovich K. U., Zarifovich K. B. Evaluation of the lipid peroxidation system and the antioxidant system of the blood during surgical interventions in endocrine practice // European

[9] Zayniyev A. F. et al. Results of differentiated surgical treatment of benign origin thyroid nodules // Annals of the Romanian Society for Cell Biology. – 2021. – C. 1962-1969.

Copyright © 2023 The Author(s). Published by Scientific & Academic Publishing

This work is licensed under the Creative Commons Attribution International License (CC BY). <http://creativecommons.org/licenses/by/4.0/>