

Histological Study of Adrenal Gland in Cases of Traumatic Brain Injury

Sukhrob Rayimberdiev¹, Ibragim Bakhriev²

¹Andijan State Medical Institute, Andijan, Uzbekistan

²Tashkent Medical Academy, Tashkent, Uzbekistan

Abstract The article presents the results of a comparative study of the morphofunctional reaction of the human adrenal glands in cases of violent death caused by traumatic brain injury. The pathomorphological characteristics of the adrenal glands in people who died of a brain variant of thanatogenesis of people who died from mechanical trauma were compared. Morphological differences in the adrenal response were revealed. It is proposed to use the assessment of the morphofunctional state of the adrenal glands as additional forensic criteria for diagnosing death from traumatic brain injury.

Keywords Traumatic brain injury, Adrenal glands, Morphology, Forensic diagnostics

1. Introduction

Currently, there is increasing interest in studying the mechanisms of damage and structural restructuring of the organs of the endocrine system caused by various pathological factors [2,4,5], affecting both physiological and emotional nature, which cause stress reactions in the body, which can become the pathogenetic basis of various conditions [3]. The harmful effect of a stressor depends on its strength, duration or repeatability, as well as on the reactivity of the organism itself, which has been subjected to excessive stress. Therefore, the same stressor in different people can cause different consequences and manifestations.

On the one hand, a stress reaction can be considered as a way to achieve resistance of the body under the action of excessive factors and be adaptive, with subsequent restructuring of the body's defense mechanisms. On the other hand, stress can be a determinant that has a damaging effect on organs and their systems, which ultimately leads to the development of pathologies. Constant stress effects on the body cause changes in the mass of stress marker organs, changes in the concentration of stress response hormones and general changes in the physical condition of a person in an unfavorable direction.

The endocrine system, having a wide range of hormonal influences on various organs and systems, plays a key role in the body's response to environmental factors and its adaptation processes to changing external conditions.

The main effector gland of internal secretion during the development of a stress reaction is the adrenal gland, the cells of the cortical layer of which secrete the hormone

cortisol, responsible for adaptation, resistance and stress resistance of the body.

The study of the histological reaction of the adrenal gland [1], taking into account its multifaceted functions, can be widely used to develop methods for correcting the pathology that has arisen, and the possibility of comparing the differences in the histological picture reflecting the functional state of the organ allows it to be used as diagnostic criteria [6].

2. Materials and Methods

The object of the study was the adrenal glands of 43 men who committed suicide (a fact established by the investigation) by hanging and died of mechanical asphyxia. As a control, the adrenal glands of 39 men who died from a life-incompatible mechanical injury without the development of the agonal period were used.

The adrenal glands (AG) were extracted and fixed in calcium formol for 24 hours. For histological examination, fragments from the middle part of the AG were taken, on which all zones of cortical (CZ) and cerebral (CS) substance were present.

On a telemetry unit consisting of a Micros light microscope, a Celeron-2000 personal computer, and a Sony camera, a karyometric study of at least 30 endocrinocytes was performed using Adobe Photo Shop 6.0 for Windows [Lakin G.F., 1980.]. The average area of endocrinocyte nuclei and its coefficient of variability were calculated.

3. Results and Discussion

The results of the morphological study showed that against the background of severe traumatic brain injury in

the adrenal glands, the development of some discirculatory, dystrophic-necrotic and dysregenerative changes is noted. At the same time, these pathomorphological changes are more pronounced in the glomerular and bundle zones of the cortical layer and manifested by loosening, vacuolization, sometimes complete destruction of parenchymal cells. The glomerular zone destroys its typical structure due to pronounced vacuolar dystrophy and necrosis of adrenocorticocytes (Fig. 1).

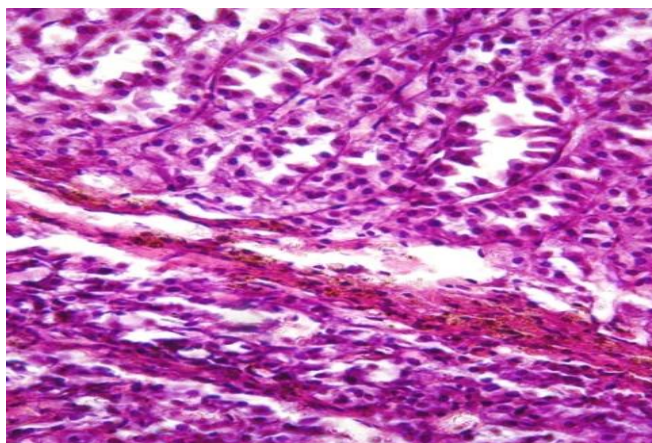


Figure 1. Glomerular zone, stroma edema, vacuolization adrenocorticocytes. Color: G-E. X: 10x20

Due to vacuolization of the adrenal parenchyma cells between the bundles and glomeruli, the interstitial tissue and vessels are expanded in volume and edematous, in places there are small foci of hemorrhage. On the part of the capsule, there is some thickening of its connective tissue layers due to the proliferation of young lymphohistiocytic cells, in places there is a germination of connective tissue towards the parenchyma.

In the bundle zone, the above-described pathomorphological dystrophic-destructive changes are more pronounced and almost completely destroy the bundle arrangement of adrenocorticocytes. If in some areas vacuolization of parenchymal cells reaches complete decay and necrosis (Fig. 2), then in other areas adrenocorticocytes are preserved in the form of hyperchromic regenerative clusters of cells with the formation of narrow beams, between which the vessels and connective tissue stroma are expanded and edematous. At the same time, the network zone of the adrenal glands relatively retains its girder and mesh structure of the parenchyma, only some vasodilation and stroma edema are noted. In the cytoplasm of adrenocorticocytes, the presence of small vacuolar formations is detected. In the cerebral layer, there are more pronounced discirculatory and edematous changes in the form of pronounced interstitial edema, focal hemorrhage. On the part of the pheochromocytoma cells of the cerebral layer, some activity and hyperplasia were noted with the formation of separate foci of proliferation of these cells.

With combined traumatic brain injury, there was more pronounced damage to the histostructure of both the cortical and medullary layers of the adrenal glands. In the cortical layer, there was an increase in discirculatory and edematous

phenomena of the connective tissue stroma and vessels. At the same time, there was a thickening of the capsule due to proliferative changes in young connective tissue cells and fibers. On the part of parenchymal cells, an increase in the regenerative activity of adrenocorticocytes was noted. Foci of active cells with hyperchromic nuclei appeared in places, without pronounced dystrophic disorders of their cytoplasm (Fig. 3).

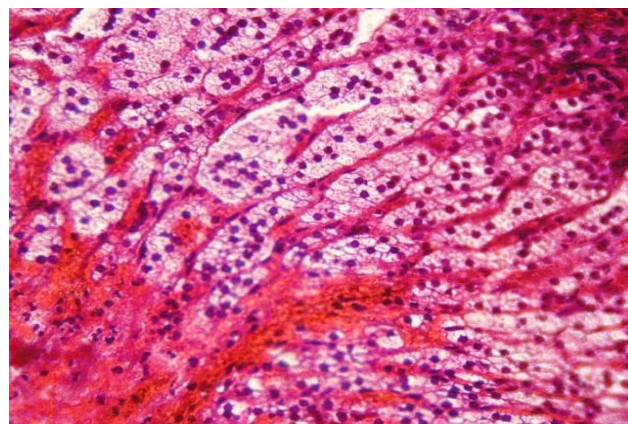


Figure 2. Foci of parenchymal decay and foci of hemorrhage in the bundle zone. Color: G-E. X: 10x20

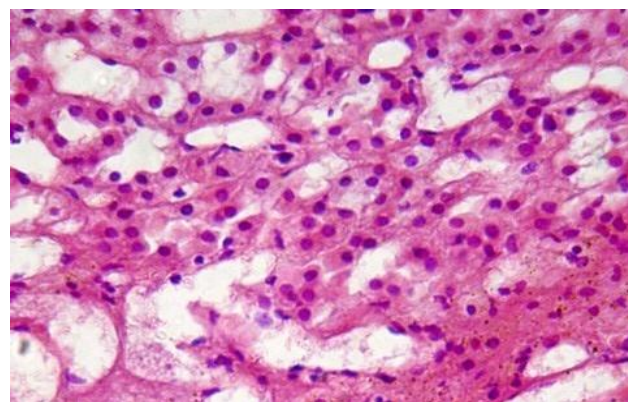


Figure 3. Increased edematous phenomena, the formation of foci of regenerates in the glomerular zone of the adrenal cortex. Color: G-E. X: 10x20

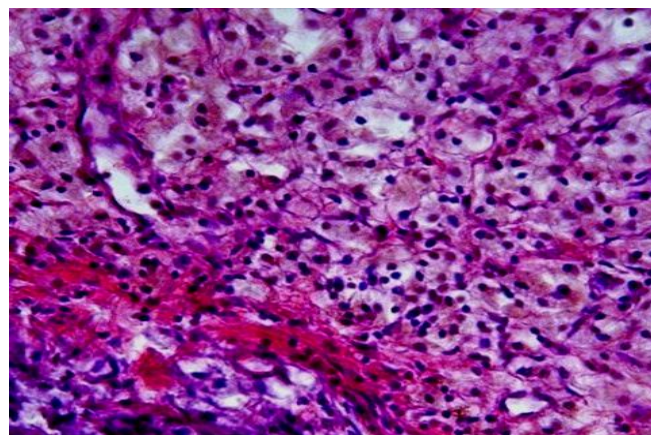


Figure 4. Bundle zone, focal interstitial edema, preservation of the bundle arrangement of adrenocorticocytes. Color: G-E. X: 10x20

In the bundle zone, the degree of circulatory and dystrophic changes is even more pronounced. Between the bundles of parenchymal cells, edematous stroma phenomena have a focal character. The main mass of adrenocorticocytes does not retain its typical structure in the form of elongated trabeculae (Fig. 4). Foci of interstitial edema, hemorrhage and dystrophic disorders of pheochromocytoma cells remain in the cerebral layer.

The results of microscopic examination of the adrenal glands showed that, unlike the previous groups, acute dyscirculatory and dystrophic-destructive changes in the adrenal cortex have the maximum severity, there is an expansion of the interstitial tissue due to edema. In the glomerular zone of the gland, there is pronounced hyperplasia of adrenocorticocytes with the formation of large foci of regenerates (Fig. 5). The nucleus of their rounded shape is hyperchromic, the cytoplasm is relatively narrow without vacuolar changes. In the interstitial tissue, there is some thickening of connective tissue layers and an increase in fibrous structures.

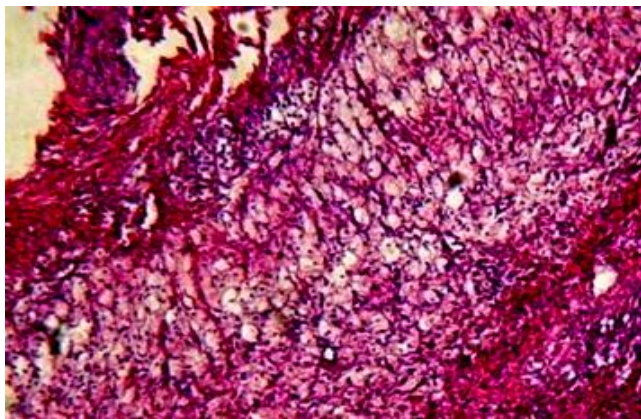


Figure 5. Pronounced destruction of adrenocorticocytes of the bundle zone of the cortex. Color: G-E. X:10x40

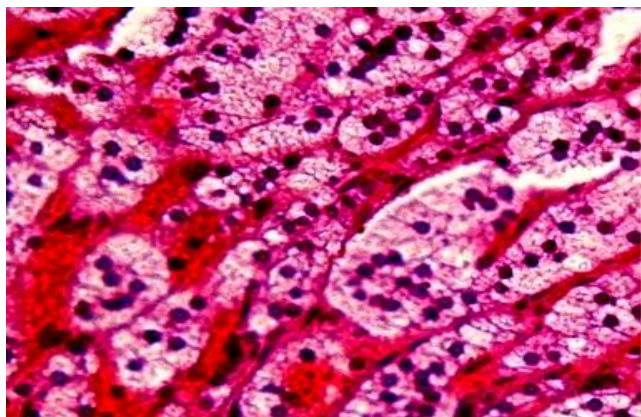


Figure 6. Bundle zone, edema, loosening of cells in the form of the formation of destructive adrenocorticocytes. Color: G-E. X: 10x20

In the bundle zone of the cortex, some focal edematous phenomena persist with the expansion of the inter-girder space, and adrenocorticocytes retain their beam and bundle structure, their vacuolar formations are not detected in the cytoplasm (Fig. 6). Some of them are in a state of active

regenerative transformation with increased stainability of both cytoplasm and nuclear structures.

4. Conclusions

Thus, against the background of severe traumatic brain injury, pronounced dyscirculatory, dystrophic-destructive changes develop in the adrenal glands, and these changes were more pronounced in the glomerular and bundle zones of the cortical layer, and in the cerebral layer, along with edematous changes, some activation of pheochromocytoma cells was noted. With combined trauma, some increases in dyscirculatory and edematous phenomena were noted separately, but foci of vacuolar rearrangements of adrenocorticocytes remained in the cortical layer. At the same time, there was an increase in dyscirculatory and edematous phenomena, active destruction of parenchymal cells was also observed, especially in the glomerular zone of the cortex in the form of the formation of foci of necrosis, destruction and hemorrhage.

The obtained data can be used to increase the validity of a forensic medical conclusion on the thanatogenesis of trauma, which indicates the expediency of referral to a microscopic examination of the adrenal glands from the corpses of persons who died as a result of traumatic brain injury or suspected of such.

REFERENCES

- [1] Avtandilov G.G. Osnovy kolichestvennoy patologicheskoy anatomii: uchebnoye posobiye / G.G. Avtandilov. - M.: Meditsina, - 2002. - 240 s. Avtandilov G.G. Fundamentals of quantitative pathological anatomy: textbook / G. G. Avtandilov. - M.: Medicine, - 2002. - 240 p.
- [2] Bakhriyev, I.I., Yeshmuratov, B.A., Raimberdiyev, S.A., Shammatov, I.YA., & Yokubov, B.T. (1(3) 2023). Patomorfologicheskiye osobennosti cherepno-mozgovoy travmy. Journal of Universal Science Research, 136-144. Bakhriev, I.I., Eshmuratov, B.A., Raimberdiev, S.A., Shammatov, I.Ya., & Yokubov, B.T. (1(3) 2023). Pathological features of traumatic brain injury. Journal of Universal Science Research, 136-144.
- [3] Dzhanbolotov S.T., Mukashev M.SH. Soderzhaniye gormona i morfofunktsional'noye sostoyaniye puchkovoy zony nadpochechnika pri suitsidal'noy smerti // Vestnik KGMA im. I.K. Akhunbayeva, - 2022, - №5, - S. 49-54. Dzhanbolotov S.T., Mukashev M.Sh. The content of the hormone and the morphofunctional state of the fascicular zone of the adrenal gland in suicidal death // Bulletin of the KSMA I.K. Akhunbaeva, - 2022, - No. 5, - S. 49-54.
- [4] Proshina Yu.V. Funktsional'naya morfologiya gipotalamo-gipofizarno-nadpochechnikovoy sistemy pri tyazhely cherepno-mozgovoy travme // Avtoreferat diss ... k.m.n., - Moskva. - 2007. - 26 s. Proshina Yu.V. Functional morphology of the hypothalamic-pituitary-adrenal system in severe traumatic brain injury // Abstract of the thesis ... PhD, - Moscow. - 2007. - 26 p.

- [5] Raimberdiyev, S.A; Bakhriyev, I.I. (2022). Struktura nadpochechnikov pri tyazheloy cherepno-mozgovoy travme. Finland International Scientific Journal of Education, Social Science & Humanities, 10 (12), 544-548. Raimberdiyev, S.A; Bakhriyev, I.I. (2022). The structure of the adrenal glands in severe traumatic brain injury. Finland International Scientific Journal of Education, Social Science & Humanities, 10(12), 544-548.
- [6] Shevchenko K.V. Morphological changes in the hypothalamic-pituitary-adrenal system in acute traumatic brain injury // Perm Medical Journal. - 2010. - T. 27. - No. 4. - S. 73-78.