

Selection Criteria for Hernioallo- and Abdominoplasty Based on the Results of Hernioabdominometry

Akhmadjon Sultanbaevich Babajanov, Saydinjon Botirjon Ugli Makhmudov

Department of Surgical Diseases of the Pediatric Faculty, Samarkand State Medical University, Samarkand, Republic of Uzbekistan

Abstract Computer hernioabdominometry was performed to determine the size of the hernial gate, the volume of the contents of the hernial sac, as well as for preliminary determination of the method of hernioallo- and abdominoplasty. This method was performed in 58 (86.6%) patients with ventral hernias and morbid obesity. The obtained forms of violation of the topography of the anterior abdominal wall made it possible to develop rational preparation of the patient before surgery, as well as to choose the optimal method of hernioplasty individually for each patient.

Keywords Ventral hernias, Computer hernioabdominometry

1. Introduction

The increase in the number of patients with obesity-related diseases, including ventral hernias, dictates the need to identify the features of surgical treatment of hernias in such patients, develop optimal surgical methods, identify possible complications in the postoperative period, and develop measures to prevent them. The variety of surgical schools and hernioplasty techniques that exist today, sometimes diametrically opposed views of different surgeons on the same problem, dictate the need for systematization and correct assessment of existing knowledge on this problem [2,3,4,6].

Thus, it is obvious that so far there is no consensus among surgeons in choosing the method and scope of surgical intervention in overweight and obese patients with ventral and recurrent postoperative hernias [1,5]. In addition to developing a unified concept, the following tasks are relevant: not only to perform hernioplasty in an obese patient without relapse, but also and not to neglect the aesthetic component [7,8]. In this regard, it is necessary to optimize and develop algorithms for surgical treatment for this category of patients.

2. The Purpose of the Research

To determine the possibilities of computer hernioabdominometry for determining the method of hernioallo- and abdominoplasty in patients with ventral hernias and morbid obesity.

3. Material and Methods of the Research

Computer hernioabdominometry (CTHA) was performed in order to determine the size of the hernial gate, the volume of the contents of the hernial sac, to identify additional defects of aponeurosis, to identify concomitant pathology of the abdominal cavity, thickness and uniformity of subcutaneous fat of the anterior abdominal wall, as well as for preliminary determination of the method of hernioallo- and abdominoplasty. This method was performed in 58 (86.6%) patients with ventral hernias and morbid obesity.

During the study, the topography of muscle-aponeurotic tissues was described: the location of the defect, the size of the hernial sac, the gate, connective tissue junctions between the wall of the hernial sac and its contents, as well as tissue changes: their structure, density, thickness. When performing CTHA to patients, attention was paid to the patient's position, which plays a significant role. When examining the patient in a horizontal position, the corrected hernial protrusion is corrected and becomes inaccessible for study, therefore, the patient was examined standing with tension of the muscles of the anterior abdominal wall. The thickness and uniformity of the distribution of subcutaneous fat of the anterior abdominal wall were taken into account, while evaluating the possibility of performing abdominoplasty.

4. Results and Discussions

A defect in the projection of hernial protrusion was reliably visualized in 34 patients. In their length, they were formations from 50 to 250 mm, with a width from 50 to 180 mm. Elements of the omentum, loops of the small intestine, as well as the most mobile parts of the large intestine were identified in the projection of the hernial gate (Fig. 1).

Adhesions were detected between the contents of the hernial sac and its walls. The frame of the anterior abdominal wall in the area of the hernial gate was thinned, its thickness

sometimes reached 3-4 millimeters ($p < 0.05$). Its main mass was represented by the skin and the parietal leaf of the peritoneum (Fig. 2).

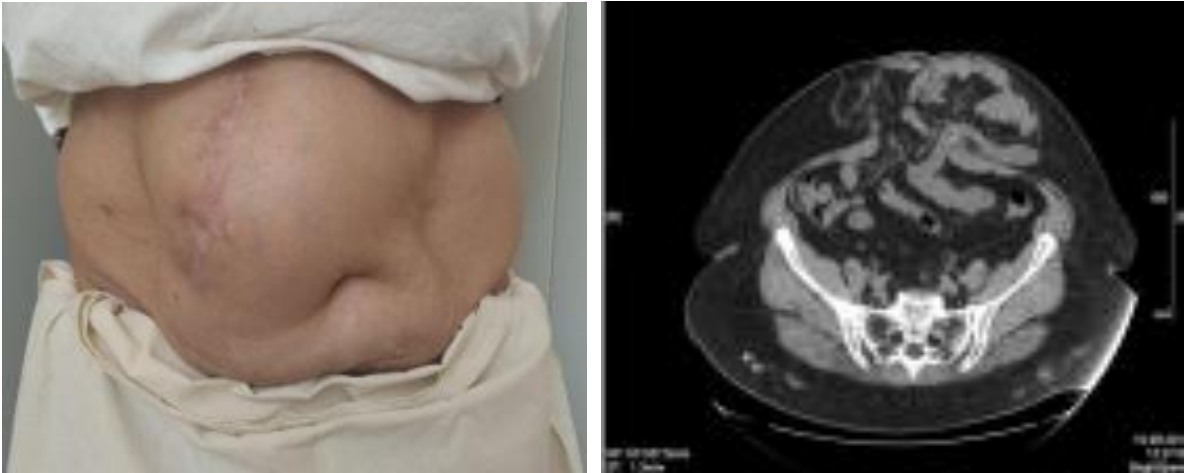

Figure 1. View of the anterior abdominal wall and computer hernioabdominometry of patient P., 56 years old with postoperative ventral hernia ($M_2W_3R_0$)

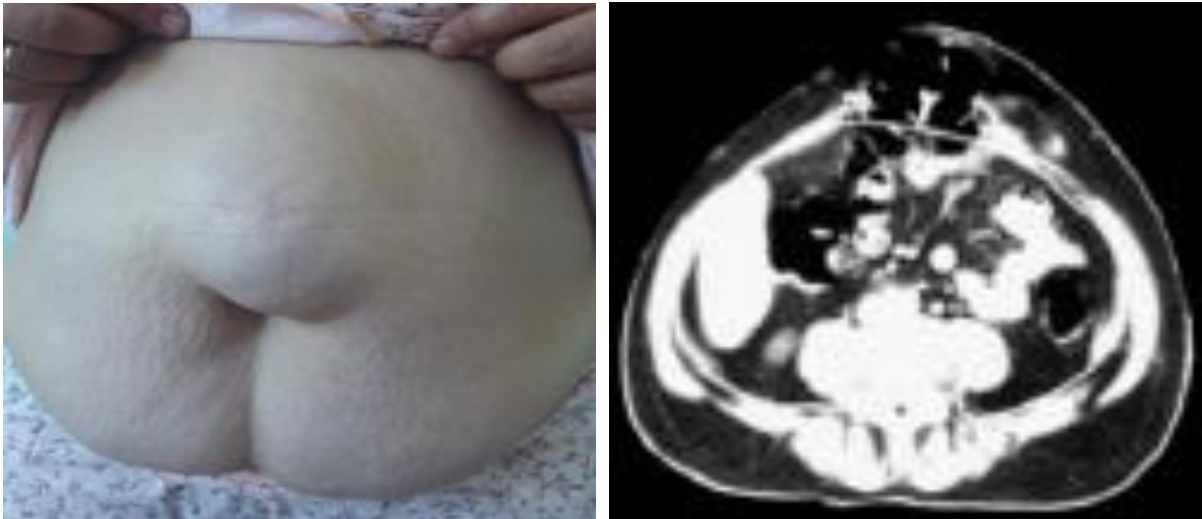


Figure 2. View of the anterior abdominal wall and computer hernioabdominometry of patient K., 52 years old with postoperative ventral hernia ($M_2W_2R_0$)

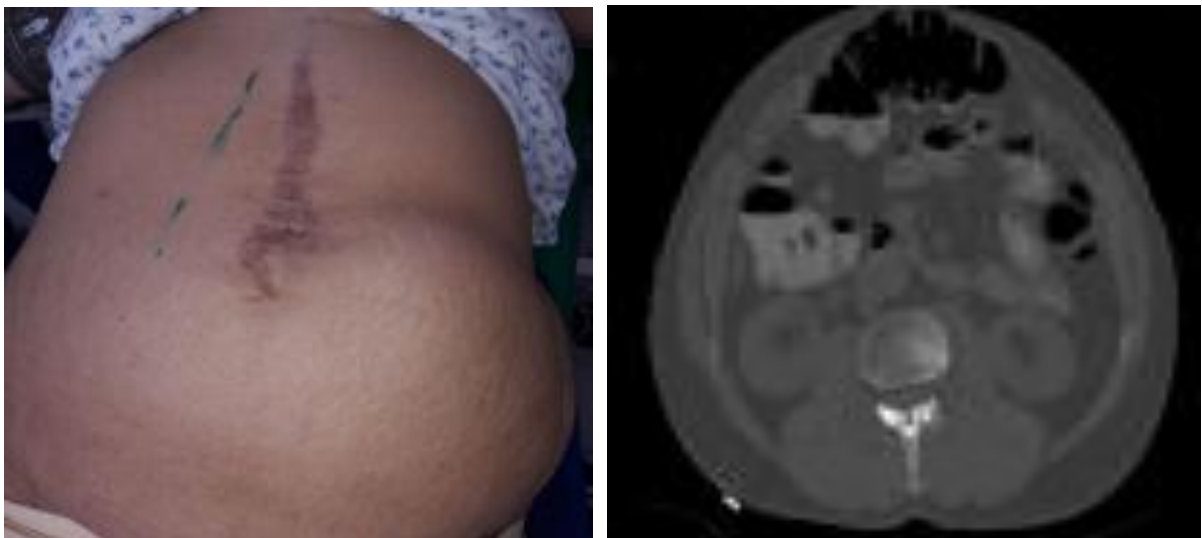


Figure 3. View of the anterior abdominal wall and computer hernioabdominometry of patient S., 62 years old with postoperative ventral hernia ($M_2W_3R_0$)

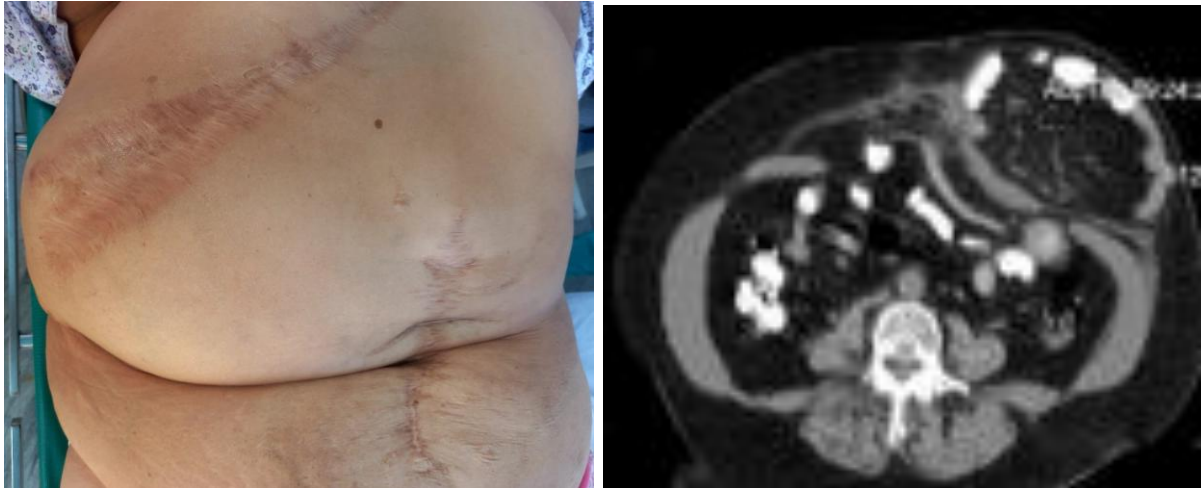


Figure 4. View of the anterior abdominal wall and computer hernioabdomenometry of patient G., 54 years old with postoperative ventral hernia (L₁W₃R₂)

The unchanged tissue of m. rectus abdominis muscles in 21 (36.2%) patients with postoperative ventral hernia was visualized homogeneous, the density of its structure was up to 40-50 units of NU, more than one centimeter thick, and clear, smooth, unchanged contours. In 37 (63.8%) of the subjects examined in m. rectus abdominis, a sharp thinning, areas of tissue fibrillation were observed (Fig. 3). A diffuse change in the density of muscle structures with a decrease in density to 20-30 HU units was determined. Against the background of a diffuse decrease in density, areas of replacement of muscle elements with connective tissue were reliably determined, and the appearance of fatty tissue between groups of muscle fibers of the rectus abdominis muscles was also observed (Fig. 4).

The size of the hernial gate was estimated by the formula $A/2 \times B/2 \times 3.14 = \text{cm}^2$, taking the hernial gate as an ellipse, where A is the largest, B is the smallest diameter of the ellipse. The volume of hernia and abdominal cavity with pelvis was measured by a direct method by tracing each section and adding their results. Since a number of authors (Rodrigues A.J., 2003) assume that a hernia is a ball, its volume was measured using the formula $a \times b \times c \times 0.52 = \text{cm}^3$, where a, b, c are transverse, anteroposterior dimensions and extent of the hernia (Fig. 5).

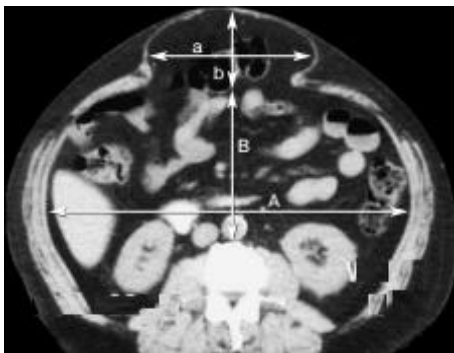


Figure 5. Measurement of the volume of the hernia and abdominal cavity: a – transverse size of the hernia, b – anteroposterior size of the hernia; A – transverse size of the abdominal cavity, B – anteroposterior size of the abdominal cavity

Since the abdominal cavity with the pelvis is taken for an ovoid, their volume was calculated using the same formula: $A \times B \times C \times 0.52 = \text{cm}^3$, where A is the transverse size of the abdominal cavity, B is the anteroposterior size, C is the extent of the abdominal cavity with the pelvis from the dome of the diaphragm to the pelvic floor. The anteroposterior size of the abdominal cavity was measured at the level of aortic bifurcation from the anterior edge of the vertebra to the abdominal wall or hernial gate, when there was none. Additionally, MPR reconstruction (sagittal or frontal) of the abdominal cavity and hernia was performed for clarity.

With a relative volume of hernial protrusion less than 5% of the volume of the abdominal cavity, hernias were considered small. If the relative volume of hernial protrusion ranged from 5.1% to 14.0% of the abdominal volume, they were considered medium hernias and considered it possible to perform tension methods of hernioplasty – implantation of an endoprosthesis "on lay" with suturing of the defect.

With a relative volume of hernial protrusion in the range of 14.1%-18%, the hernia was considered large, while the method of choice was non-tensioning prosthetic plastics, "correction" or "reconstruction" of the anterior abdominal wall. With 18% or more of the relative volume of hernial protrusion from the volume of the abdominal cavity, the hernia was considered gigantic, the choice of surgery occurred only in favor of non-tensioning plastic surgery - implantation of the endoprosthesis "onlay" without suturing the defect, implantation by the combined method "onlay + sublay" of the endoprosthesis without suturing the defect and implantation by the combined method "onlay + sublay" without suturing the defect with mobilization of the vaginas of the rectus abdominis muscles by Ramirez.

5. Conclusions

CT hernioabdomenometry is informative in diagnosing the condition of the anterior abdominal wall tissues in patients with postoperative ventral hernia. The use of this technique

allows us to obtain a more detailed and clear description of the picture that influenced the change in the topography and structure of the elements of the muscular-aponeurotic framework. The resulting forms of topography disorders allowed to develop rational preparation of the patient before surgery, depending on the size of the hernia, as well as to choose the optimal method of hernioplasty individually for each patient.

REFERENCES

- [1] Akhmedov, B. A., Mamanov, M. C., Abdurakhmanov, D. S., & Usarov, S. N. (2021). ADVANCED LONG-TENSION HERNIOALLOPLASTY METHOD FOR INGUINAL HERNIA. In *VOLGAMEDSCIENCE* (pp. 335-336).
- [2] Angio, L. G., Pirrone, G., Campolo, V., De Caridi, G., Santagati, C., & Famulari, C. (2001). Anterior inguinal hernioalloplasty by the modified Valenti's technique. Preliminary results of our experience. *Il Giornale di Chirurgia*, 22(4), 127-132.
- [3] Nasirov, M. I., Dzhamalova, T. P., Dzhamalov, F. G., Akhundov, I. T., Guseinov, S. G., & Sharifov, É. I. (2015). Analysis of remote results of simultaneous hernioalloplasty and abdominoplasty in patients with postoperative ventral hernias and obesity. *Khirurgiia*, (2), 70-74.
- [4] Kurbaniyazov, Z. B., Davlatov, S. S., Rakhmanov, K. E., & Igamberdiev, A. A. (2017). Optimization Of Tension-Free Hernioalloplastic For An Inguinal Hernia.
- [5] Taschieri, A. M., Danelli, P., Kurihara, H., Montecamozzo, G., Porretta, T., & Molteni, B. (1998). Preperitoneal hernioalloplasty by anterior access under local anesthesia. Personal technique. *CHIRURGIA-TORINO-*, 11, 352-356.
- [6] Baylón K. et al. Past, present and future of surgical meshes: a review // *Membranes*. – 2017. – T. 7. – №. 3. – C. 47.
- [7] Berrevoet F. et al. A multicenter prospective study of patients undergoing open ventral hernia repair with intraperitoneal positioning using the monofilament polyester composite ventral patch: interim results of the PANACEA study // *Medical devices (Auckland, NZ)*. – 2017. – T. 10. – C. 81.
- [8] Elstner K. E. et al. Preoperative progressive pneumoperitoneum complementing chemical component relaxation in complex ventral hernia repair // *Surgical endoscopy*. – 2017. – T. 31. – №. 4. – C. 1914-1922.