

# Technical Aspects of Laparoscopic Prosthetic Hernioplasty

Sayinaev Farrukh Karomatovich<sup>1</sup>, Kurbaniyazov Zafar Babajanovich<sup>1</sup>,  
Rakhmanov Kosim Erdanovich<sup>1</sup>, Davlatov Salim Sulaymonovich<sup>2,\*</sup>

<sup>1</sup>Samarkand State Medical Institute, Republic of Uzbekistan, Samarkand

<sup>2</sup>Bukhara State Medical Institute, Republic of Uzbekistan, Bukhara

**Abstract** The problem of treating patients with ventral hernias currently remains not fully understood and is very relevant. The aim of the study is to improve the quality of treatment of ventral hernias by improving the tactical and technical aspects and optimizing endovideosurgery in hernioplasty. The article presents the data of a clinical examination of 117 patients with ventral hernias who were operated on in the surgical department of the 1st clinic of the Samarkand State Medical Institute for the period from 2016 to 2020. Depending on the choice of treatment tactics, the patients were divided into two groups. The first group, the comparison group, consisted of 65 (55.5%) patients who underwent open hernia repair. The second group, the main group, consisted of 52 (44.5%) patients who were initially planned for laparoscopic prosthetic hernioplasty. The use of the proposed modified Undo Close needle made it possible to technically optimize the stage of fixing the prosthesis to the anterior abdominal wall by simplifying the stitching of tissues in a direction parallel to the horizontal plane in intracorporeal conditions.

**Keywords** Ventral hernia, Alloplasty, Pneumoperitoneum, Endovideosurgery

## 1. Relevance

The problem of treating patients with ventral hernias currently remains not fully understood and is very relevant. Despite a significant number of works devoted to the surgical treatment of ventral hernias, the solution of the problem of preventing recurrence of the disease in the treatment of patients with hernias of the anterior abdominal wall remains very relevant [3,7,14].

The literature indicates that the trend in the treatment of ventral hernias and the prevention of recurrence are based on the restoration of the strength of the anterior abdominal wall, physical rehabilitation in the postoperative period and the implementation of the cosmetic effect [1,4,5,9,11,13]. Given this, the choice of the method of surgery until now is an urgent problem. The modern concept dictates the need to close the hernial defect by combined methods using mesh implants, which ensures the restoration of the function of the anterior abdominal wall [2,6,8,10,12].

## 2. The Aim of the Study

To improve the quality of treatment of ventral hernias by improving the tactical and technical aspects and optimizing endovideosurgery in hernioplasty.

## 3. Materials and Methods of Research

The study is based on a clinical examination of 117 patients with ventral hernias who were operated in the surgical department of the 1st clinic of the Samarkand State Medical Institute for the period from 2016 to 2020. All patients were operated on as planned. Depending on the choice of treatment tactics, the patients were divided into two groups. The first group, the comparison group, consisted of 65 (55.5%) patients who underwent herniation by the open method. The second group, the main group, consisted of 52 (44.5%) patients who were scheduled for laparoscopic prosthetic hernioplasty.

In the main group, 49 (94.2%) laparoscopic prosthetic hernioplasty was performed. Of these, 37 (75.5%) patients (subgroup 1) used standard mesh polypropylene implants, and 12 (24.5%) patients (subgroup 2) used composite mesh implants "Physiomesh" or "Prosid" (Ethicon).

In the main group of patients, several stages of standard endovideosurgical hernioplasty were improved: the sites of working trocars were standardized; the dimensions of the implant along the perimeter were 5 cm larger than the size of the hernial defect; the implant was fixed to the anterior abdominal wall using an Endo Close needle modified by us.

\* Corresponding author:

salim.davlatov@bsmi.uz (Davlatov Salim Sulaymonovich)

Received: Nov. 22, 2021; Accepted: Dec. 6, 2021; Published: Dec. 15, 2021

Published online at <http://journal.sapub.org/ajmms>

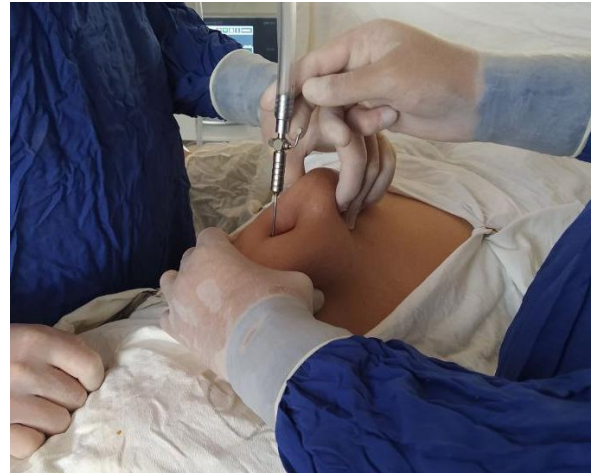Surgical intervention was performed according to the standard procedure.

Stage I - introduction of the first trocar. Depending on the primary or postoperative hernia, the introduction of the first trocar was carried out in two ways:

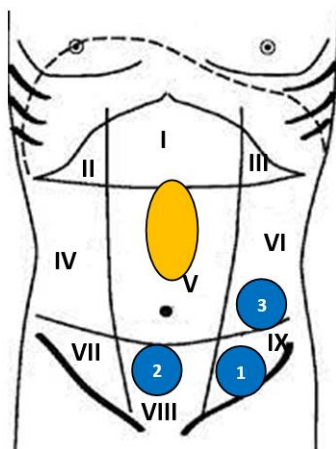
1. Patients with primary ventral hernia used the standard method with the introduction of a Veresh needle (Fig. 1), the pneumoperitoneum was inflated to a pressure of 12-14 mm Hg, after removing the needle, a trocar was injected into the abdominal cavity. Usually, entry into the free abdominal cavity was carried out using a special optical trocar "Visiport™" (Covidien), then the abdominal cavity was audited;
2. With the probability of adhesions, patients with postoperative ventral hernias used the Hassen technique, i.e. the abdominal wall was opened in layers with a 2-4 cm long incision, the adhesions were separated around the wound under visual control and a trocar with an obturator was inserted through the incision, the wound was sealed.

Stage II of the operation – after the introduction of the first trocar with optics and revision of the abdominal cavity, 2 or 3

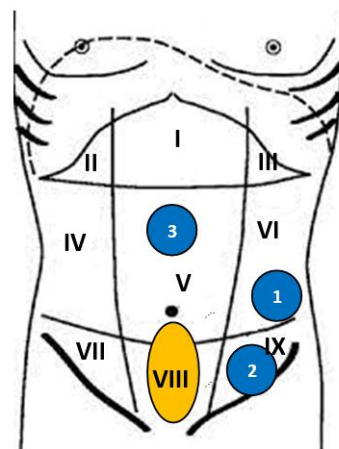
working trocars were introduced. The places of introduction of trocars were standardized and selected where it was more convenient and safe. At the same time, we tried to observe the principle of interaction of two laparoscopic instruments at an angle of at least 45° to each other (Fig. 2).



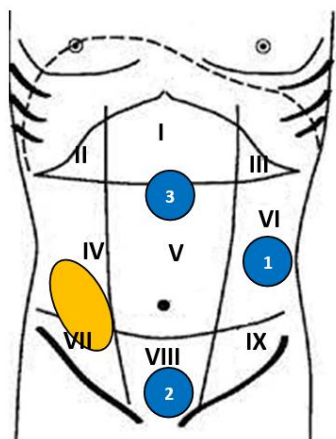
**Figure 1.** Insertion of the Veresh needle and the imposition of a pneumoperitoneum



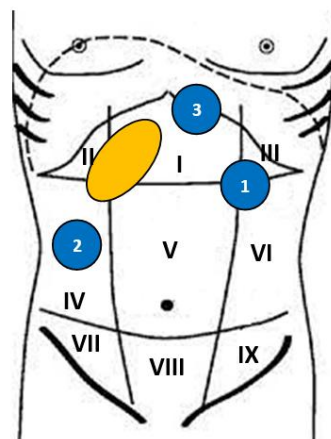
**Hernia of the white line of the abdomen above the navel ( $M_1$ )**



**Hernia of the white line of the abdomen below the navel ( $M_3$ )**

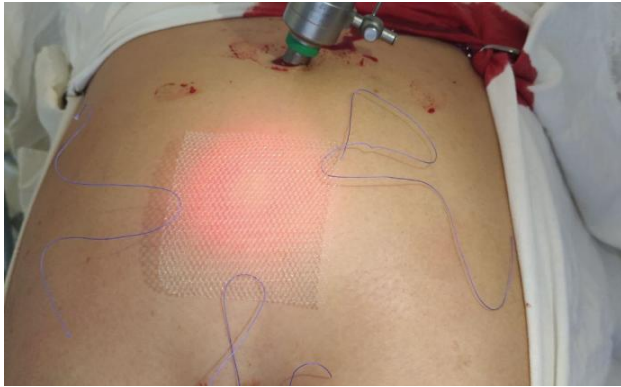

**Postoperative abdominal hernia of the right iliac region ( $L_3$ )**

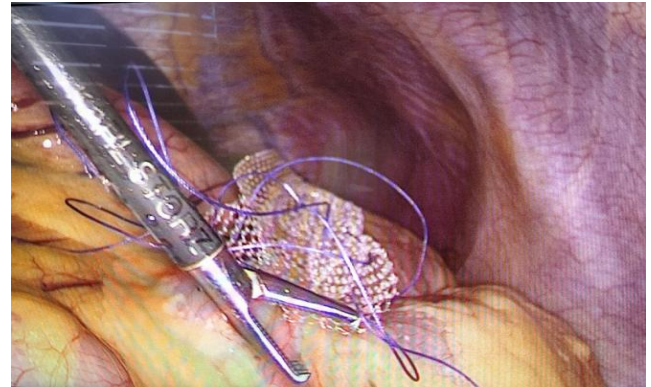


**Postoperative hernia of the abdomen in the right hypochondrium ( $L_1$ )**


**Figure 2.** Scheme of trocar insertion points in the most typical localization of ventral hernias



**Figure 3.** A type of mesh polypropylene implant whose perimeter dimensions are 5 cm larger than the size of the hernial defect



**Figure 4.** Unfolding into a rolled-up mesh implant



**Figure 5.** Modified Endo Close needle for suturing the implant to the anterior abdominal wall

The third stage was adhesiolysis. The separation of adhesions between the hernial sac, the anterior abdominal wall and nearby organs was performed using electrocoagulation.

Stage IV - identification of the aponevros defect, determination of the true size of the hernial gate, selection of a mesh implant of the appropriate size.

Stage V – cutting out the implant, whose perimeter dimensions are 5 cm larger than the size of the hernial defect and modeling of the mesh implant (if necessary), marking the hernial gates and ligature fixation points, stitching the edges of the mesh implant with ligatures for its intra-abdominal straightening and pressing against the anterior abdominal wall before final fixation (Fig. 3.).

Stage VI. At the sixth stage of the operation, depending on the type of mesh implant, the patients of the main group were divided into two subgroups. Subgroup 1 included 37 (75.5% of 49 patients who underwent laparoscopic prosthetic hernioplasty) patients who used standard mesh polypropylene implants. The 2nd subgroup included 12 (24.5%) patients who used composite mesh implants "Physiomes" or "Prosid" (Ethicon).

Patients of subgroup 1, before the implant was inserted into the abdominal cavity, the peritoneum was opened, a hernial sac was allocated and a "pocket" was created in the preperitoneal space, the indentation along the perimeter from the hernial mouth was 5-6 cm.

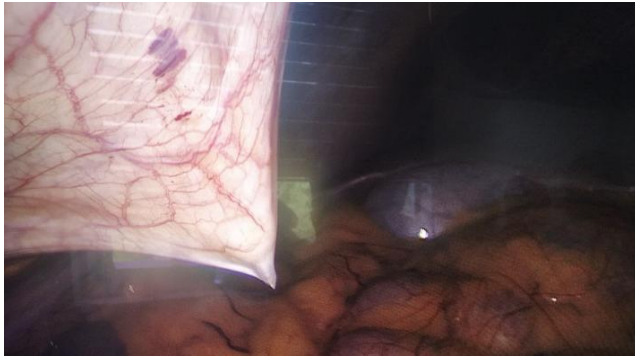
Next, a mesh implant rolled into a tube was inserted into the abdominal cavity through a trocar, unfolded and placed in the created preperitoneal "pocket" (Fig. 4). Pressing it against the anterior abdominal wall was carried out using ligatures tied at the edges of the implant.

The suturing of the implant thread to the anterior abdominal wall was performed using a modified Endo Close needle (Fig. 5).

The one-time use and high cost of the needle for suturing trocar punctures ENDO CLOSE prompted us to invent a modified needle for reusable use. In an innovative difference from the prototype, the tip of the modified needle is armed with a hook that captures and securely holds the thread when it is carried through the fabric. A special cutting on the needle section prevents the thread from slipping when the implant is stitched to the anterior abdominal wall. The special shape and grooved surface of the handle are designed for the most reliable and comfortable grip of the needle. The abdominal wall was pierced with a needle from the outside with a margin of 5-6 cm from the hernial gate and the needle was visually controlled from the abdominal cavity with an endovideolaparoscope (Fig. 6).

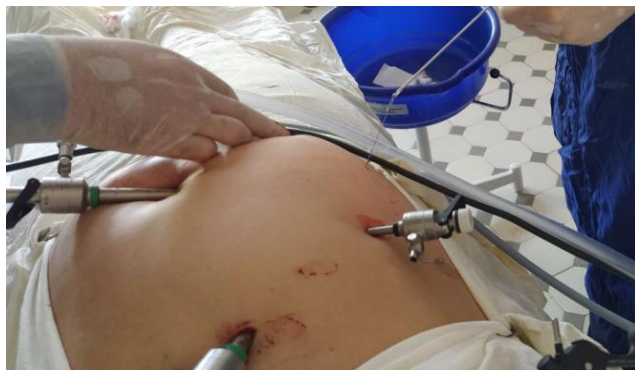The use of composite mesh implants "Physiomes" or "Prosid" (Ethicon) in 12 (24.5%) patients of subgroup 2, made it possible to avoid the need to create a pre-peritoneal "pocket" before fixing the prosthesis to the anterior abdominal wall.





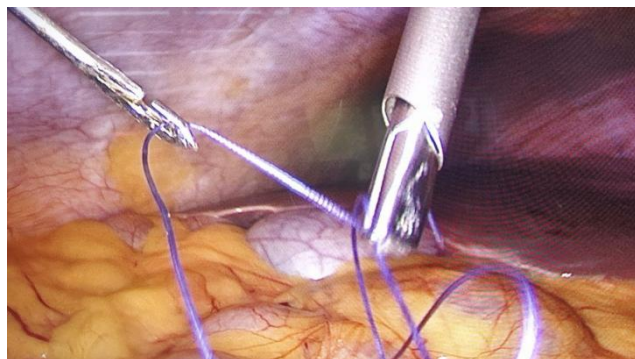
**Figure 6.** Puncture of the needle from the abdominal cavity visually under the control of endovideolaparoscopy

The implant was fixed by stitching with a modified Endo Close needle, a non-absorbable suture material was used. The threads were tied ex-corporately, after their complete removal (Fig. 7).



**Figure 7.** View of the suture threads removed from the side of the abdominal wall

Stage VII was also different depending on the type of implant used. 37 patients of subgroup 1 who used standard polypropylene nets required peritonization of the implant in order to prevent the adhesive process of the abdominal cavity. Peritonization was performed using a modified Endo Close needle. At this stage, the use of a modified Endo Close needle for peritonization of the implant accelerated the course of the operation. The use of the modified Endo Close needle was convenient for the surgeon and safe for the patient rather than intraportally piercing the peritoneum (Fig. 8).



**Figure 8.** Peritonization of a standard mesh implant using a modified Endo Close needle

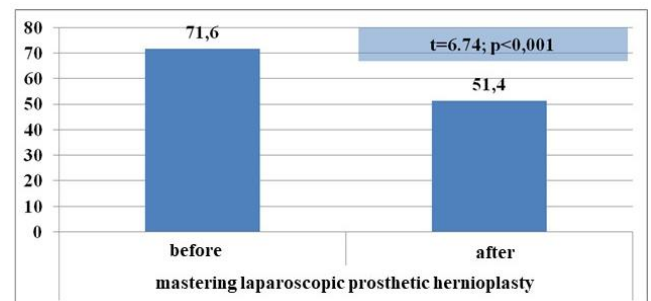
Patients in subgroup 2 who used composite mesh implants did not require implant peritonization, i.e. this stage was absent in this subgroup.

At the end of the operation, patients in both subgroups underwent hemostasis control, gas desufflation, trocar removal and suturing of 10 mm punctures of the anterior abdominal wall, application of intradermal absorbable sutures to skin incisions and aseptic dressings.

## 4. The Results of the Study

Improving the choice of tactics for surgical treatment of ventral hernias, techniques for performing laparoscopic prosthetic hernioplasty and other innovations developed and implemented within the framework of this study could not but affect the immediate results of management of this category of patients.

In the early years, i.e. during the development of laparoscopic technology for performing prosthetics hernioplasty took quite a long time (to  $71.6 \pm 0.7$  min), however, with increasing experience of surgeons and the development of technology, the surgery significantly decreased to  $51.4 \pm 0.6$  min (T-criterion = 6,74,  $P < 0.001$ ) (Fig. 9).



**Figure 9.** The time of the operation during the development of endovideosurgical surgery (min.)

In addition it should be noted that in the period of development of method 3 (5,8%) patients underwent conversion, i.e. hernia repair is completed by an open method.

**Table 1.** The reason for the conversion of laparoscopic prosthetic hernioplasty

Reason for conversion	Number of patients (n=3)	
	abs.	%
Pronounced adhesive process and elongation of the stage of separation of adhesions more than 50 min.:	3	100,0
- Intraoperatively increased A/D	2	66,7
- Intraoperative reduction of saturation	1	33,3

The reason for the conversion was due to a pronounced adhesive process in the abdominal cavity, concomitant diseases of the cardiovascular and respiratory systems that reacted to prolonged pneumoperitoneum. The reasons for the conversion are shown in Table 1.

As can be seen from Table 1, in all cases (5.8% of the total number of patients in the main group), the cause of conversion was a pronounced abdominal spa process in patients with postoperative ventral hernias.

For a long time, the separation of adhesions for more than 50 minutes, i.e. prolonged pneumoperitoneum manifested itself by an increase in blood pressure intraoperatively to 200/100 mm Hg. in 2 patients and in 1 patient with concomitant chronic respiratory tract disease, led to a decrease in blood oxygen saturation.

In all the above 3 cases, the operations were completed by open allogernioplasty using the "on lay" method.

The abrupt changes in the parameters of the cardiovascular and respiratory system during surgery can be explained by the prolonged course of the pneumoperitoneum, which is a rather stressful factor associated with stretching of the peritoneum, rich in nerve endings. It should also be noted that the return to the initial level of indicators of the cardiovascular and respiratory system occurred after conversion, i.e. elimination of pneumoperitoneum.

## 5. Conclusions

The use of the proposed modified Undo Close needle made it possible to technically optimize the stage of fixing the prosthesis to the anterior abdominal wall by simplifying the stitching of tissues in a direction parallel to the horizontal plane in intracorporeal conditions.

The improvement of technical aspects allowed: due to the differentiated introduction of the first trocar, such complications as perforation of the wall of the hollow organ were eliminated; due to the standardization of the maintenance of working trocars, the technique of the operation was simplified; due to the fixation of the implant with an offset from the hernial gate by 5-6 cm, the recurrence of hernia in the long-term postoperative period was minimized; due to the use of a modified needle, it was possible to eliminate technical difficulties in fixing the prosthesis and in peritonizing standard non-composite mesh implants with a reduction in this stage of the operation from  $27.4 \pm 0.5$  to  $12.6 \pm 0.7$  minutes ( $P < 0.001$ ).

**Information about the source of support in the form of grants, equipment, and drugs.** The authors did not receive financial support from manufacturers of medicines and medical equipment.

**Conflicts of interest:** The authors have no conflicts of interest.

## REFERENCES

[1] Abdurakhmanov D. S., Rakhmanov Q. E., Davlatov S. S.

Criteria for choosing surgical treatment of patients with ventral hernias and obesity // *Electronic innovation bulletin*. – 2021. – №. 7. – C. 57-67.

- [2] Abdurakhmanov D. S., Rakhmanov Q. E., Davlatov S. S. Tensioned hernioplasty and abdominoplasty in patients with morbid obesity // *Electronic innovation bulletin*. – 2021. – №. 3. – P. 20-27.
- [3] Azamat S., Zafarjon K., Salim D. Criteria's of choice method in surgical treatment of patients ventral hernia with concomitant obesity // *European science review*. – 2016. – №. 3-4. – P. 232-234.
- [4] Davlatov S. S., Suyarova Z. Eliminate postoperative complications after ventral hernia repair in patients with morbid obesity // *Scientific discussion (Praha, Czech Republic)*. – 2017. – T. 1. – №. 8. – C. 4-7.
- [5] Kurbaniyazov Z. B. et al. Advanced method of non-tension hernioplasty for inguinal hernias // *Hospital surgery. Magazine named after LA Kovalchuk*. – 2017. – №. 1. – P. 71-74.
- [6] Kurbaniyazov Z. B. et al. Pull hernioplastics in patients with inguinal hernia // *Materials of a scientific-practical conference with international participation. Problems of biology and medicine*. – 2016. – №. 4. – P. 1.
- [7] Machado N. O. Laparoscopic repair of Bochdalek diaphragmatic hernia in adults // *North American journal of medical sciences*. – 2016. – T. 8. – №. 2. – P. 65.
- [8] Mirdamadi S. A., Arasteh M. Hiatal hernia: An unusual presentation of dyspnea // *North American journal of medical sciences*. – 2010. – T. 2. – №. 8. – P. 395.
- [9] Nazyrov F. G. et al. Age-related structural changes in aponeuroses of the rectus abdominal muscles in patients with postoperative ventral hernias // *Clinical and experimental pathology*. – 2018. – T. 17. – №. 3.
- [10] Sayinaev F. K. et al. Laparoscopic treatment of incisional ventral hernias // *湖南大学学报 (自然科学版)*. – 2021. – T. 48. – №. 7. – P. 143-149.
- [11] Shamsiev A. M., Davlatov S. S. Khirurgicheskoe lechenie bol'nykh ventral'nyimi gryzhami s soputstvuyushchim ozhireniem [Method of surgical treatment of ventral hernia in patients with obesity]. *Hospital surgery // Journal by LYA. Kovalchuk*. – 2016. – T. 1. – P. 78-83.
- [12] Shamsiev A. M., Davlatov S. S., Saydullaev Z. Y. Optimization of treatment of patients with postoperative ventral hernia // *Science, technology and education*. – 2017. – №. 10. – P. 94-99.
- [13] Sulaymonovich D. S. Ways to Eliminate Postoperative Complications after Ventral Hernia Repair in Patients with Morbid Obesity // *American Journal of Medicine and Medical Sciences*. – 2017. – T. 7. – №. 3. – C. 147-150.
- [14] Teshaev O. R., Alimkulov Y. S. Analysis of relapse after alloplasty paleoposition of ventral hernias // *Biology and Integra-tive medicine*. – 2021. – №. 2 (49). – Pp. 77-83.