

Justification of Simultaneous Operations on the Organs of the Abdominal Cavity and Abdominal Wall in Patients with Ventral Hernia

Kurbaniyazov Zafar Babajanovich, Mardanov Bobosher Amirovich,
Davlatov Salim Sulaymonovich*, Rakhmanov Kosim Erdanovich

Samarkand State Medical Institute, Republic of Uzbekistan, Samarkand

Abstract **Relevance.** According to domestic and foreign literature, 15-20% of patients who underwent hernia repair, in the coming years after surgery undergo repeated surgical interventions for other surgical diseases. **The aim of the study** is to improve the quality of treatment of patients with ventral hernia by reducing the frequency and severity of complications after simultaneous and reconstructive surgery on the abdominal organs and abdominal wall. **Materials and research methods.** The study included the results of treatment of 197 patients with simultaneous pathology of the abdominal cavity and abdominal wall, admitted to the surgical department of the 1st clinic of Samarkand State Medical Institute. **The results of the study.** On average, one patient in the comparison group had 2-3 complications in the form of a combination of bronchopulmonary and / or cardiovascular complications with wound complications. In general, in the comparison group there were 17 (18.3% of 93) patients with various complications. **Findings.** Improving the tactical and technical aspects allowed: in 47.1% of cases in the main group to perform a simultaneous operation from separate two accesses and thereby reduce the frequency of performing simultaneous operations through one access to 52.9%, and the duration of the operation from 98.5 ± 4.9 to 72.5 ± 2.9 minutes (t -test = 4.23; $p < 0.001$).

Keywords Ventral hernia, Simultaneous operations, Abdominal cavity, Postoperative complication

1. Relevance

According to domestic and foreign literature, 15-20% of patients who underwent hernia repair, in the coming years after surgery are subjected to repeated surgical interventions for other surgical diseases [2,5].

This determines the urgency of the problem of simultaneous operations. Attention should be paid to the irrationality of performing only hernia repair in case of hepatitis A if the patient has a combined disease of the abdominal organs. If only hernia repair is performed, repeated surgery for abdominal pathology often negates the results of hernioplasty [1,4,7].

The analysis of the literature indicates that current trends in the treatment of patients with hepatitis B and simultaneous surgical diseases of the abdominal cavity and the prevention of complications in the early and long-term postoperative periods are based on the restoration of the abdominal wall

function, physical rehabilitation after surgery and the achievement of a cosmetic effect. A significant percentage of unsatisfactory outcomes, the lack of a choice of the optimal treatment method, prompt further research in this area [3,6]. In connection with the foregoing, it seems relevant to develop effective methods and principles of surgical treatment of patients with large and giant umbilical and postoperative ventral hernias in combination with another pathology of the abdominal organs. The development of simultaneous and reconstructive surgery on the organs of the abdominal cavity and abdominal wall in patients with ventral hernias requires an integrated approach consisting of many component tasks within the framework of one problem.

The aim of the study is to improve the quality of treatment of patients with ventral hernia by reducing the frequency and severity of complications after simultaneous and reconstructive surgery on the abdominal organs and abdominal wall.

2. Materials and Research Methods

The study included the results of treatment of 197 patients with simultaneous pathology of the abdominal cavity and abdominal wall, admitted to the surgical department of the 1st clinic of Samarkand State Medical Institute.

* Corresponding author:

salimdavlatov@sammi.uz (Davlatov Salim Sulaymonovich)

Published online at <http://journal.sapub.org/ajmms>

Copyright © 2020 The Author(s). Published by Scientific & Academic Publishing

This work is licensed under the Creative Commons Attribution International

License (CC BY). <http://creativecommons.org/licenses/by/4.0/>

Depending on the tactics of preoperative preparation and the choice of surgical intervention, patients are conditionally divided into two groups: In 2012-2015. operated on 93 (47.2%) patients who made up the comparison group. From 2016 to 2019 under our supervision there were 104 (52.8%) patients who entered the main group.

Preoperative preparation of patients of both groups was carried out according to standard methods. The physical status of patients in the comparison group was evaluated by the ASA classification. All patients took into account the presence of concomitant somatic diseases. In the preoperative preparation algorithm, we included those items that directly affect the identified and correctable risk factors.

191 patients had one concomitant surgical pathology of the abdominal organs, and 6 patients had two. All patients in the study groups underwent simultaneous operations.

After a thorough preoperative preparation in the preoperative period, the surgeon must solve at least two questions: 1. Operation access, simultaneous operation to be performed through one access or two separate accesses; 2. If it is necessary to perform through separate accesses, which stage should be performed first, the main stage or the simultaneous stage.

Since in all the patients examined by us, the main pathology was a ventral hernia, and the simultaneous pathology was a surgical disease of an organ of the abdominal cavity when choosing a surgical approach, first of all, the location of the hernia gate, then the location of the organ with simultaneous pathology in the areas of the abdominal cavity was taken into account (fig. 1).

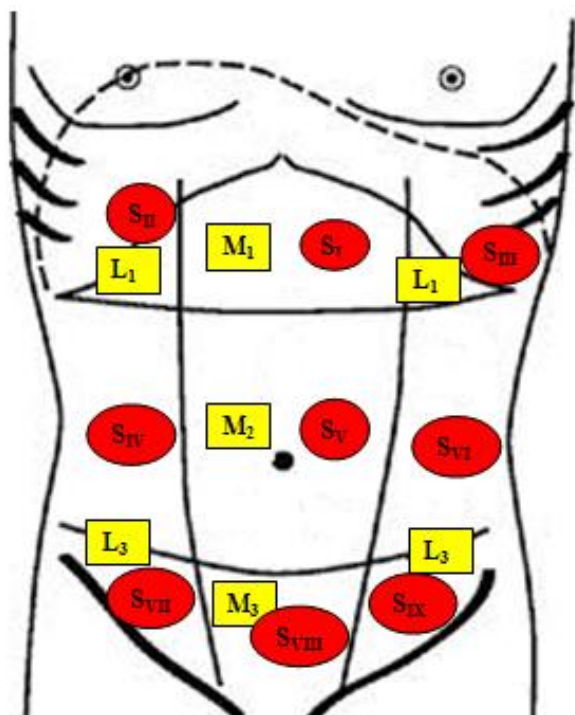


Figure 1. A schematic arrangement of a hernia in the anterior abdominal wall and of simultaneous abdominal pathology (L, M - localization of the hernia Chervel J. P and. Rath A. M (1999),. S - localization of simultaneous disease in different areas of the abdominal cavity)

In the main group of patients with the location of surgical diseases at a wide distance from each other, each pathology was operated through separate accesses (table 1). Until 2016, in such situations, when performing simultaneous operations, they used exclusively traditional wide accesses, i.e. herniolaparotomy was expanded to the epigastric region, which greatly facilitated the surgeon to perform the simultaneous stage of the operation. Further, the elimination of a hernial defect took a lot of time, the duration of the operation increased. In addition, there were a number of serious and well-known shortcomings - high invasiveness of the operation, increased risk of postoperative wound and general complications, unsatisfactory cosmetic results, a long period of early rehabilitation, etc.

Table 1. Distribution of patients of the main group at the location of the hernia and simultaneous pathology

Hernia nature		The location of the simultaneous pathology in the areas of the abdominal cavity				Total	
		S _{II}	S _V	S _{VIII}	S _{II-SVIII}		
S	M	M ₁	15*		15	1	31
		M ₂	19	13	17		49
		M ₃	7	1	5		13
		M ₄	1				1
	L	L ₁	1		2	1	4
		L ₃	1			2	3
		ML		3			3
		44	17	39	4		
W	W ₁	23	5	6	1	35	
	W ₂	18	8	20	3	49	
	W ₃	2	3	7		12	
	W ₄	1	1	6		8	
R	R ₀	39	13	38	3	93	
	R ₁	4	1	1	1	7	
	R ₂		3			3	
	R ₃	1				1	

* Note:
 - simultaneous operation through one access;
 - simultaneous operation through separate accesses

In general, in the comparison group, in 93.5% of cases, simultaneous surgery was performed through wide median access, in 6.5% of patients - hypochondrium. After performing herniolaparotomy, we started the simultaneous stage of the operation, then we performed the main stage of the operation - the elimination of the laparotomy wound and hernial defect. In 82.8% of cases, the suture line on the aponeurosis was covered with a polypropylene mesh. Alloplasty was not performed in 16 (17.2%) patients due to infection of the surgical wound. The cause of infection of the wound was: suppuration echinococcosis of the liver, suppuration ovarian cyst. He made plastic of the anterior abdominal wall with double-row interrupted sutures.

In the main group of patients, 55 (52.9%) patients received simultaneous surgery through one access, after herniolaparotomy. In 49 (47.1%) patients, the simultaneous

operation was performed through separate accesses, while adhering to the principles of asepsis to choose the sequence of the main or simultaneous stage of the operation. Comparative indicators of the duration of the operation in minutes depending on the access undertaken are shown in Fig. 2. A significant difference was also noted for these values ($p < 0.001$).

Thus, taking into account the dystopia of the hernia and the simultaneous pathology of the abdominal organs, in 47.1% of cases in the main group we performed a simultaneous operation from two separate accesses and thereby reduced the frequency of performing simultaneous operations through one access to 52.9%, and the duration operations from 98.5 ± 4.9 to 72.5 ± 2.9 minutes (t -test = 4.23; $p < 0.001$).

In general, hernioplasty in combination with the simultaneous stage of the operation is shown in table 2.

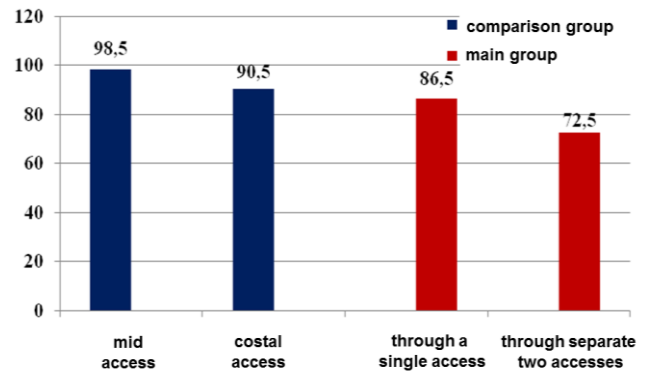


Figure 2. Comparative indicators of the duration of the operation (min) depending on the access undertaken

Table 2. The nature of the performed simultaneous operations in patients of the main group

Simultaneous operation phase	Through one access (n = 55)								Through separate two accesses (n = 49)								Total	
	Autoplasty		Onlay implant implantation with defect closure		Onlay implant without suturing defect + DLE		Implantation of an onlay endoprosthesis without suturing of a defect with mobilization of the vagina of the rectus abdominis muscle according to Ramirez + (DLE)		Onlay implant implantation with defect closure		Onlay implant implantation without suturing defect + (DLE)		Onlay implant implantation without suturing of a defect with mobilization of rectus sheath muscles according to Ramirez + DLE					
	ađc.	%	ađc.	%	ađc.	%	ađc.	%	ađc.	%	ađc.	%	ađc.	%				
HhE			2	6,4					21	53,8	4	100	6	100	33	31,7		
ChE + choledochostomy									2	5,1					2	1,9		
EEP	closed	4	28,6	1	3,2				1	2,6					6	5,8		
	half closed	2	14,3												2	1,9		
Ideal EE from BS					1	20,0									1	0,9		
Liver cyst fenestration					1	20,0									1	0,9		
Ovarian Cystectomy	7	50,0	4	12,9			4	80,0	3	7,7					18	17,3		
Subvaginal Uterus Amputation			12	38,7	1	20,0			8	20,5					21	20,2		
viscerolysis			12	38,7	2	40,0	1	20,0							15	14,4		
Small bowel resection	1	7,1													1	0,9		
CE + ovarian cystectomy									3	7,7					3	2,9		
CE + supravaginal amputation of the uterus									1	2,6					1	0,9		
Total	14	100	31	100	5	100	5 (2)	100	39	100	4 (1)	100	6	100	104	100		

3. The Results of the Study

On average, one patient in the comparison group had 2-3 complications in the form of a combination of bronchopulmonary and / or cardiovascular complications with wound complications. In general, in the comparison group there were 17 (18.3% of 93) patients with various complications. In the main group there were 9 (8.6% of 104) patients with various complications. Relative improvement in the number of complications showed a significant improvement in the main group (Criterion $\chi^2 = 4.043$; Df = 1; $p = 0.045$) (fig. 3).

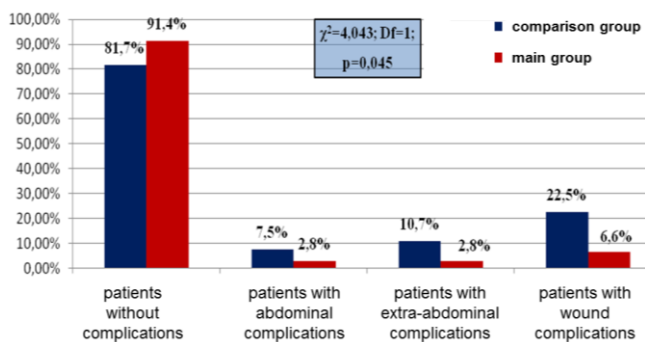


Figure 3. The distribution of patients according to the frequency of complications after simultaneous surgery

4. Findings

Improving the tactical and technical aspects allowed: in 47.1% of cases in the main group to perform a simultaneous operation from separate two accesses and thereby reduce the frequency of performing simultaneous operations through one access to 52.9%, and the duration of the operation from 98.5 ± 4.9 to 72.5 ± 2.9 minutes (t -test = 4.23; $p < 0.001$).

The application of the proposed algorithm, taking into account the improved tactical and technical aspects of surgical treatment of hypertension with simultaneous surgical pathology of the abdominal organs, reduced the

overall frequency of postoperative complications from 18.3% to 8.6% ($p = 0.045$), including wound from 22.5% to 6.6% and extra-abdominal from 10.7% to 2.8%, as well as significantly reduce the duration of surgical treatment and rehabilitation periods after various options for hernioplasty.

REFERENCES

- [1] Azamat S. et al. Abdominoplastics of postoperative ventral hernia in patients with obesity of III-IV degree //European science review. – 2016. – №. 3-4.
- [2] Birolini C. et al. Elective colonic operation and prosthetic repair of incisional hernia: does contamination contraindicate abdominal wall prosthesis use? //Journal of the American College of Surgeons. – 2000. – T. 191. – №. 4. – C. 366-372.
- [3] Bittner R. et al. Guidelines for laparoscopic treatment of ventral and incisional abdominal wall hernias (International Endohernia Society [IEHS])-Part III //Surgical endoscopy. – 2014. – T. 28. – №. 2. – C. 380-404.
- [4] Le Ruyet A. et al. Differences in biomechanics of abdominal wall closure with and without mesh reinforcement: A study in post mortem human specimens //Journal of the Mechanical Behavior of Biomedical Materials. – 2020. – T. 105. – C. 103683.
- [5] Lipman J., Medalie D., Rosen M. J. Staged repair of massive incisional hernias with loss of abdominal domain: a novel approach //The American journal of surgery. – 2008. – T. 195. – №. 1. – C. 84-88.
- [6] Kryvoruchko I., Tonkoglas A., Goni S. K. Abdominal Surgery. Contents module 1. Hernias. – 2019.
- [7] Sulaymonovich D. S. Ways to Eliminate Postoperative Complications after Ventral Hernia Repair in Patients with Morbid Obesity //American Journal of Medicine and Medical Sciences. – 2017. – T. 7. – №. 3. – C. 147-150.