

Clinical-Morphological Parameters of Tumor Tissue of Breast Cancer with Positive and Negative Phenotypes of Expression of Receptors to Estrogen and Progesterone

A. Kh. Rakhmanov^{1,*}, A. A. Abduvaliev¹, Z. Z. Khakimov¹, Sh. R. Mavlanov¹, F. W. Wang²

¹Tashkent Medical Academy, Tashkent, Uzbekistan

²Chengdu Institute of Biology, Chinese Academy of Sciences, China

Abstract A study of clinical and morphological parameters of tumor tissue of breast cancer with positive and negative phenotypes of receptor expression to estrogens and progesterone (ER (-) / PgR (-)) was conducted. 48 samples of tumor tissue of breast cancer were selected for the study in patients who underwent surgery for the treatment of this disease at the Republican Cancer Research Center in Tashkent (Uzbekistan). The average age of women were $52,04 \pm 1,52$ years old. There was positive expression to estrogen receptors (from 2+ to 3+ by 4 point scale count of immunohistochemical reaction) in $66,66 \pm 6,80\%$ examination of tumor samples and the expression of receptors to estrogens were absent in $33,4 \pm 6,80\%$ samples. There was positive expression to progesterone receptors (from 2+ to 3+ by 4 point scale count of immunohistochemical reaction) in $60,41 \pm 7,05\%$ examination of tumor samples and the expression of receptors to progesterone were absent in $39,58 \pm 7,05\%$ samples.

Keywords Breast cancer, Expression of receptor, Estrogen, Progesterone

1. Introduction

Microchipping of the tumor cells' DNA of breast cancer (BC) has made it possible to identify several genetically different forms of this disease. This molecular genetic classification has been actively used in clinical practice for the purpose of individualizing therapeutic approaches and studying new methods of treatment. According to the molecular genetic classification, the following variants of breast cancer are defined, which differ according to the prognosis and sensitivity to different types of drug therapy [1, 2]:

- luminal A ER (+) and / or PgR (+) / HER-2 / neu (-);
- luminal B: ER (+) / and / or PgR (+) / HER-2 / neu (+);
- HER-2 / neu (+): ER (-) / PgR (-) / HER-2 / neu (+);
- basal-like: ER (-) / PgRQ / HER-2 / neuQ.

Histogenetic basal-like BC is associated with basal epithelium, which in the healthy mammary gland composes external layer adjacent to the basal membrane, lining the ducts and lobules. This is a morphologically and immunophenotypically heterogeneous population with the features of epithelial and smooth muscle cells, which is reflected in their name – myoepithelial [3, 4].

In addition to other markers, the expression of high molecular basal cytokeratins (CK5/6, CK14, CK17), EGFR (HER1), p-cadherin, CAV1 and CAV2 are typical for these cells [5]. The expression of genes typical for basal /myoepithelial cells are also determined in the basal-like breast cancer cells. Many products of these genes perform a structural role, participate in the proliferation of cells, the oppression of apoptosis, migration and/or invasion i.e. in processes inherent for cancer [6].

At the same time, the expression of ER, ER-dependent and other genes characteristic for luminal epithelial cells of normal breast tissue, as well as HER-2 amplicon in basal-like tumors, is minimal [7].

Thus, at the base of the aggressive phenotype of basal-like tumors lies the corresponding genotype, indicating the origin from the least differentiated (possibly even stem) cells [8].

Endocrine therapy is indicated for most patients with breast cancer (BC) with receptor-positive tumors (ER+/PR+) [9, 10]. Ovarian steroid production decreases with age and development of estrogen in postmenopausal women occurs primarily in peripheral tissues such as adipose tissue and adrenal androstenedione where in the corticosteroid is converted (transformed) first into estrone and then to estradiol. This peripheral conversion occurs via aromatase (enzyme complex consisting of the cytochrome P450 and flavoproteins), which is a catalyst for the converting of androgens to estrogens [11].

Currently, the treatment of basal-like breast cancer with a

* Corresponding author:

dr.ali.fl@mail.ru (A. Kh. Rakhmanov)

Published online at <http://journal.sapub.org/ajmms>

Copyright © 2017 Scientific & Academic Publishing. All Rights Reserved

negative phenotype of the expression of receptors for estrogens and progesterone (ER (-) / PgR (-)) is an actual problem in oncology. We conducted a study of clinical and morphological parameters of tumor tissue of breast cancer with positive and negative phenotypes of receptor expression for estrogens and progesterone (ER (-) / PgR (-)).

2. Material and Methods

48 samples of tumor tissue of breast cancer were selected for the study in patients who underwent surgery for the treatment of this disease at the Republican Cancer Research Center in Tashkent (Uzbekistan). Criteria for selection were a verified diagnosis of breast cancer and surgical intervention in this regard.

The routine clinic examinations were carried out in all patients (biochemical status, clinical characteristics of the tumor, histological, ultrasound, radiographic examination, computer tomography).

Determination of the expression of receptors to estrogens and progesterone was carried out by using test kits (DAKO) for the immunohistochemical study. The received results were subjected to the statistic processing with the using of standard software package Biostat 2009 on well-known method of variation statistics with an estimation of the statistic significance of indicators ($M \pm m$) and differences between groups were analyzed using the Student's t-test. $P < 0.05$ was considered significant.

3. Results and Discussion

The average age of women were $52,04 \pm 1,52$ years old.

The primary symptoms of women who addressed to medical care with the reason of breast disease and concomitant disease were given in 1st figure. It was determined that there was hereditary pathology i.e. "cancer family" where close relatives by female line suffered from the oncopathology of breast and reproductive organs length several generation in one woman ($2,08 \pm 0,2\%$).

The results of determining of localization and consistency of tumor were showed in table 1.

Table 1. The results of determining of localization and consistency of tumor

Nº	Parameter	Absolute number	%
1	Localization of tumor:		
	upper-external	19	$39,58 \pm 7,05$
	upper-interior	11	$22,91 \pm 6,06$
	Lower-external	6	$12,5 \pm 4,77$
	Lower-interior	4	$8,33 \pm 3,98$
	Damage of papilla	2	$4,16 \pm 2,88$
2	Consistency of tumor:		
	Dense	21	$43,75 \pm 7,16$
	Dense-elastic	4	$8,33 \pm 3,98$
	soft-elastic	1	$2,08 \pm 1,06$
	Soft	1	$2,08 \pm 1,06$
	Inhomogeneous	18	$37,5 \pm 6,98$

The upper-external and upper-internal localization of tumor mass was determined in majority of women whose tumor samples were selected for further investigation. The consistency of tumors predominantly was dense and inhomogeneous.

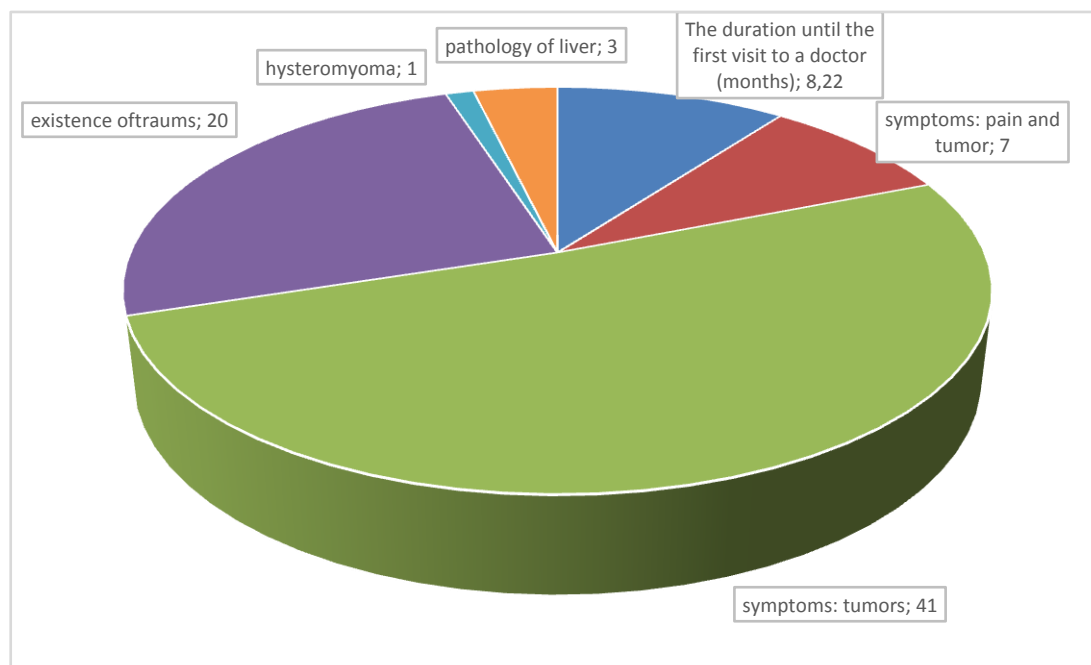


Figure 1. The primary symptoms of women who addressed to medical care with the reason of breast disease and concomitant disease (in absolute numbers)

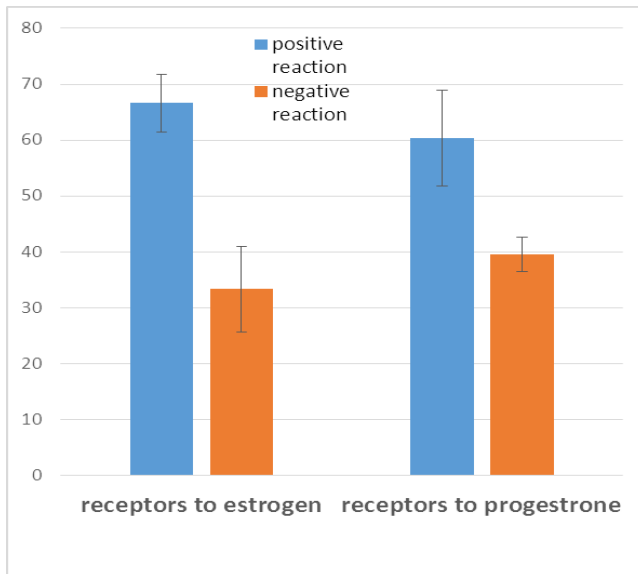


Figure 2. The determination of expression of receptors to estrogens and progesterone on the surface of tumor cells with the immunohistochemical visualization method (n=48)

The selected tumor samples (n=48) was examined for the determination of expression of receptors to estrogens and progesterone on the surface of tumor cells with the immunohistochemical visualization method (figure 2). There was positive expression to estrogen receptors (from 2+ to 3+ by 4 point scale count of immunohistochemical reaction) in

66,66±6,80% examination of tumor samples and the expression of receptors to estrogens were absent in 33,4±6,80% samples.

There was positive expression to progesterone receptors (from 2+ to 3+ by 4 point scale count of immunohistochemical reaction) in 60,41±7,05% examination of tumor samples and the expression of receptors to progesterone were absent in 39,58±7,05% samples.

The spread of tumor process by TNM system in patients with breast cancer of 1st and 2nd groups was showed in figure 3. It was shown in figure that the spread of tumor process mostly was T₁N₀M₀ (37,5±12,1%) in estrogen-negative forms of breast cancer, whereas this form of spreading in estrogen-positive phenotype was observed only in 9,3±5,15% cases. Notably, the breast cancer with absence of the expression of receptors to estrogens is diagnosed in majority of cases in early stages of disease. However, low-effective therapy without considering the phenotypic features of cancer cells does not allow reaching favorable outcomes of disease.

The results of morphological verification of breast cancer in patients with estrogen negative and estrogen-positive phenotypes were given in table 2.

The most frequent morphological type of the tumor was infiltrating cancer, a quarter of the investigated cases were ductal cancer.

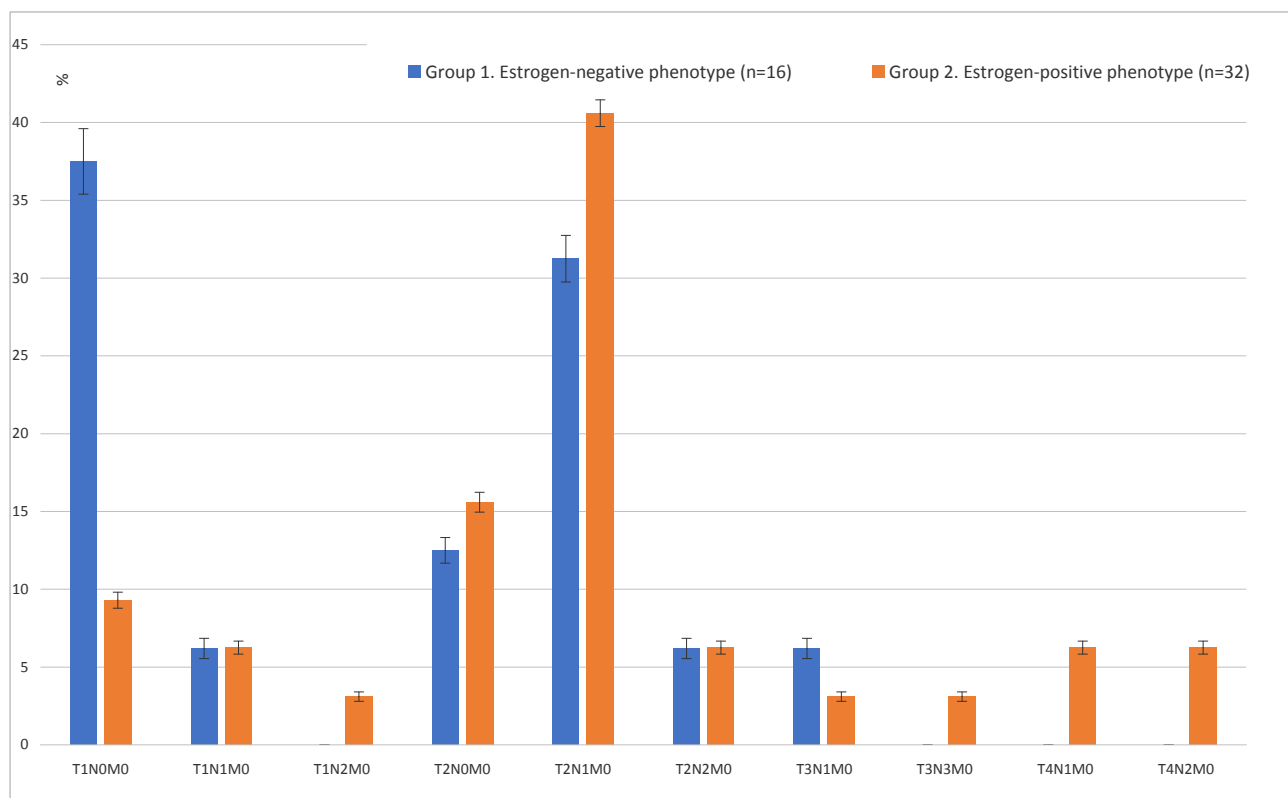


Figure 3. The spread of tumor process by TNM system in patients with breast cancer with estrogen-negative and estrogen-positive phenotypes

Table 2. Results of morphological verification of breast cancer in patient with estrogen-negative and estrogen-positive phenotypes

№	Morpho-gical characteris-tics of tumor	Group 1. Estrogen-negative phenotype (n=16)		Group 2. Estrogen-positive phenotype (n=32)	
		Absol-ute	%	Absol-ute	%
1	Adenocarcinoma	1	6,25±6,05	3	9,37±5,15
2	Infiltrating cancer	11	68,75±11,58	20	62,5±8,55
3	Ductal cancer	4	25,0±10,82	8	25,0±7,65
4	Cancer in situ	0	-	1	3,125±3,07

Receptor positive luminal subtype (ER/PR) characterizes better prognosis in comparison with receptor-negative one. The patients with breast cancer characterizing with the negative status of hormonal receptors are under the big risk of recidivation of disease in the first 2 years after operation. The risk of developing recidivation of disease in the first 2 years after operation is considerably low in the patients with breast cancer characterizing with the positive status of estrogen receptors. Though the yearly risk of initiation of recidivation in patients of both groups is relatively low after 2-3 years, this risk never ceases to exist [12].

The results of our studies showed that at randomized selection (the criterias for selection were used: verified breast cancer and operative intervention for this case), there was positive expression to estrogen receptors (from 2+ to 3+ by 4 point scale count of immunohistochemical reaction) in 66,66±6,80% examination of tumor samples and the expression of receptors to estrogens were absent in 33,4±6,80% samples.

Thus, the most frequent morphological type of the tumor among the selected samples was infiltrating cancer, a quarter of the investigated cases were ductal cancer.

The investigations showed lower rate of common and recurrence-free surviving in “negative” form of breast cancer in comparison with “positive”. The monitoring on patients from this group revealed that the secondary alterations including metastasis into central nervous system arise at them in the first 3 years after operation [13, 14].

4. Conclusions

In spite of bad prognosis, “negative” breast cancer is susceptible to the standard chemotherapy schemes including anthracyclin- and taxan-containing schemes. However, some patients do not reply to standard therapy. Knowledge on certain molecular characteristics of “negative” breast cancer helps to understand better the pathophysiology of disease and to develop more effective methods of treatment including the new generation of medicines consisting compounds from the natural resources.

ACKNOWLEDGEMENTS

The part of this study was carried out by assisting Gildieva M.S., ScD, head of laboratory of tumor biology, Republican

Scientific Center of Oncology of Uzbekistan.

This scientific work was supported by the grant M/UZB-CHINA-28/2015 from Agency for Science and Technology of Uzbekistan.

REFERENCES

- [1] Alluri P.G., Larios J., Malik R., Rae J., Chinnaiyan A., 2016, Targeting Estrogen Receptor (ER) Mutations for Treatment of Endocrine Therapy Resistance in Breast Cancer. *Int. J. Radiat. Oncol. Biol. Phys.*, 96, p. 53-61.
- [2] Foulkes W.D., Knoppers B.M., Turnbull C., 2016, Population genetic testing for cancer susceptibility: founder mutations to genomes. *Nat. Rev. Clin. Oncol.*, 13(1), p. 41-54.
- [3] Matsuda N., Lim B., Wang X., Ueno N.T., 2017, Early clinical development of epidermal growth factor receptor targeted therapy in breast cancer. *Expert Opin Investig Drugs.*, 26(4), p. 463-479.
- [4] Badowska-Kozakiewicz A.M., Budzik M.P., 2017, Immunohistochemical characteristics of basal-like breast cancer. *Contemp Oncol (Pozn.)*, 20(6), p. 436-443.
- [5] Hon J.D., Singh B., Sahin A. et al., 2016, Breast cancer molecular subtypes: from TNBC to QNBC. *Am J Cancer Res.*, 6(9), p. 1864-1872.
- [6] Hou J.P., Emad A., Puleo G.J., Ma J., Milenkovic O., 2016, A new correlation clustering method for cancer mutation analysis. *Bioinformatics*, 32(24), p. 3717-3728.
- [7] Ahn S.G., Kim S.J., Kim C., Jeong J. 2016, Molecular Classification of Triple-Negative Breast Cancer. *J Breast Cancer*, 19(3), p. 223-230.
- [8] Xu J., Footman A., Qin Y. et al., 2016, BRCA1 Mutation Leads to Deregulated Ubc9 Levels which Triggers Proliferation and Migration of Patient-Derived High Grade Serous Ovarian Cancer and Triple Negative Breast Cancer Cells. *Int. J. Chronic. Dis. Ther.*, 2(3), p. 31-38.
- [9] Denkert C., Liedtke C., Tutt A., von Minckwitz G., 2016, Molecular alterations in triple-negative breast cancer-the road to new treatment strategies. *Lancet*, pii: S0140-6736(16)32454-0, doi: 10.1016/S0140-6736(16)32454-0.
- [10] Bhattacharya R., Banerjee K., Mukherjee N. et al., 2017, From molecular insight to therapeutic strategy: The holistic approach for treating triple negative breast cancer. *Pathol Res Pract*, 213(3), p. 177-182.

- [11] Borrie A.E., Kim R.B., 2016, Molecular basis of aromatase inhibitor associated arthralgia: known and potential candidate genes and associated biomarkers. *Expert Opin. Drug Metab. Toxicol.*, 20, p. 1-8.
- [12] Ha N.H., Long J., Cai Q., Shu X.O., Hunter K.W., 2016, The Circadian Rhythm Gene *Arntl2* Is a Metastasis Susceptibility Gene for Estrogen Receptor-Negative Breast Cancer. *PLoS Genet.*, 12(9). - e1006267
- [13] Badowska-Kozakiewicz A., Sobol M., Patera J., 2016, Expression of Hypoxia-Inducible Factor 1 α in Invasive Breast Cancer with Metastasis to Lymph Nodes: Correlation with Steroid Receptors, HER2 and EPO-R. *Adv. Clin. Exp. Med.*, 25, p. 741-750.
- [14] Anders C.K., Abramson V., Tan T., Dent R., 2016, The Evolution of Triple-Negative Breast Cancer: From Biology to Novel Therapeutics. *Am Soc Clin Oncol Educ Book*, 35, p. 34-42.