

Ways to Eliminate Postoperative Complications after Ventral Hernia Repair in Patients with Morbid Obesity

Davlatov Salim Sulaymonovich

Samarkand State Medical Institute, Uzbekistan

Abstract **Relevance of the research problem:** Despite the rapid development of minimally invasive endovideosurgical technologies in abdominal surgery the number of surgical procedures using conventional laparotomy remains high which complicates 4-18% incisional hernias (IH). The goal of the research was to improve the results of surgical treatment of patients with ventral hernias and morbid obesity. **Materials and methods:** The research included 228 patients with incisional, recurrent and primary ventral hernias who underwent hernia repair in the surgical departments of the Samarkand Medical Institute (SamMI) hospital in a period from 2007 to 2015. According to the method of hernia repair all the patients were divided into two groups: the control group 96 (42.1%) patients underwent primary repair with or without mesh and the study group 132 (57.9%) patients had primary mesh repair with dermolipectomy. **Conclusion:** The research showed patients who underwent primary mesh repair with dermolipectomy had 20,0% less wound complications and 28,8% less cardio-vascular system complications comparing to control group. Cases of recurrence or death were not observed in both groups. The proposed method to prevent wound complications after hernia mesh repair based on wide sewing and fixing the subcutaneous fat grafts to the mesh and the bottom of the wound using the vertical U-shaped seams significantly reduced the incidence of IH from 16.7% to 3.3%.

Keywords Ventral hernia, Morbid obesity, Hernia repair, Postoperative complications

1. Relevance of the Research Problem

Despite the rapid development of minimally invasive endovideosurgical technologies in abdominal surgery the number of surgical procedures using conventional laparotomy remains high, after which incisional hernias (IH) develop up to 18% of the cases. In the general statistical structure of ventral hernias IH makes up 20-26% [1]. Large incisional hernias (LIH) in the structure of the abdominal hernias have a special place and they account for 3 to 14%. About 60% of patients with IH aged from 21 to 60 years old, i.e., they are a significant part of the working population [2, 3]. Results of IH treatment are characterized by a fairly high number of recurrences (from 4.3 to 46%) while in LIH recurrences reach 60% of the cases. An important problem of the ventral hernia treatment is early postoperative complications, because they are the major cause of prolonged postoperative period, additional moral and physical suffering of the patient and possible mortality [4]. Previous researches show that wound complications are observed both in using different types of meshes (polypropylene, PTFE) and methods for various locations in

the tissues [5]. Therefore, the presence of many methods to prevent wound complications in the treatment of ventral hernias and significance of the issue dictate the need to develop techniques and tactics to reduce the frequency of wound complications in the patients after hernia repair.

2. Objective

The goal of the research was to improve the results of surgical treatment of patients with ventral hernias and morbid obesity.

3. Materials and Methods

The study was based on the analysis of the hernia repair results in 228 patients with incisional, recurrent and primary ventral hernias who underwent hernia repair in the surgical departments of the SamMI hospital in a period from 2007 to 2015.

According to the method of repair all the patients were divided into two groups: the control group (96 - 42.1%) had primary repair with or without mesh and the study group (132 - 57.9%) underwent primary mesh repair with dermolipectomy. From 228 patients male comprised 30.3% (69) and 69.7% (159) were females. The study group had slightly high comorbidities. Preoperative preparation of

* Corresponding author:

sammi-xirurgiya@yandex.ru (Davlatov Salim Sulaymonovich)

Published online at <http://journal.sapub.org/ajmms>

Copyright © 2017 Scientific & Academic Publishing. All Rights Reserved

patients before hospitalization included a complex of measures to reduce body weight in cases of morbid obesity, treatment of comorbidities, including treatment of concurrent abdominal cavity pathologies. Additionally, patients underwent training of the gastrointestinal tract and sanitation of the surgical field in the preoperative period. All the patients underwent procedures to prevent venous thromboembolism.

Patients with the width of the hernia W_3 and W_4 according to the Chervel & Rath classification [3] underwent preoperative preparation in order to adapt the cardiovascular and respiratory systems to increased intra-abdominal pressure: modified pneumobandage, Trendelenburg position by gradually raising the foot end of the bed to an angle of 45° , low-fiber diet. Our modified method of pneumobandage (IAP 2016 0046) allows to increase abdominal pressure gradually. At the same time the patient's condition was assessed as well as indexes of hemodynamic and respiration. The Trendelenburg position with hernia reposition into the abdominal cavity also promotes the development of adaptation mechanisms to abdominal hypertension. Prescription of the low-fiber diet increases the volume of the abdominal cavity and facilitates manipulation during the surgery. In addition a few days before surgery some patients received cleansing enemas and laxatives by individual indications.

All the patients underwent surgical operation. In patients with concomitant surgical diseases at the same time their correction was carried out. Simultaneous surgeries were performed in 10 patients in the both groups. The simultaneous surgical interventions were: cholecystectomy - 7, supravaginal amputation of the uterus with appendages - 1, viscerolysis in cases of small bowel obstruction - 2. The first stage of the hernia repair - on the skin of the anterior abdominal wall pattern of "anchor" was applied (incision by Fleisch), skirting the hernial bulge, old postoperative scar and skin - fat fold (Fig. 1).

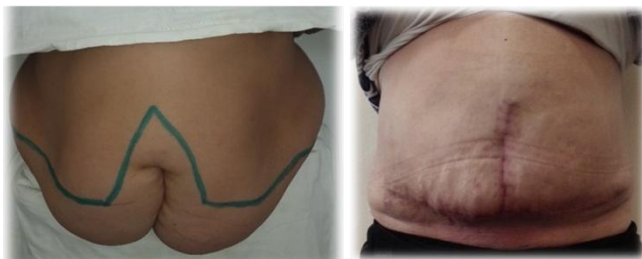


Figure 1. Patient view before - and after abdominoplasty (incision by Fleisch)

Further separation and excision of the hernia sac were performed according to standard conventional method. At IH during the surgery ligature microabscesses, granulomas and fistulas in the anterior abdominal wall tissues were often identified. Excision of these pathologies was performed within the healthy tissues with subsequent washing of the wound with antiseptics and changing of surgical tools and gloves. Separation of adhesions in the hernial sac and the

abdominal cavity were made by blunt and sharp ways with checking the hemostasis and integrity of tissues.

The second stage of hernia repair begins from the mobilization of the aponeurosis from subcutaneous fat not more than 5 cm from the edge of the hernial ring. This space is sufficient for the further fixation of the mesh and it prevents excessive detachment of the subcutaneous fat. In patients of the control group, hernia repair with or without mesh was performed depending on the site and width of the hernial ring. Mesh was fixed by «onlay» method (Fig. 2, 3).

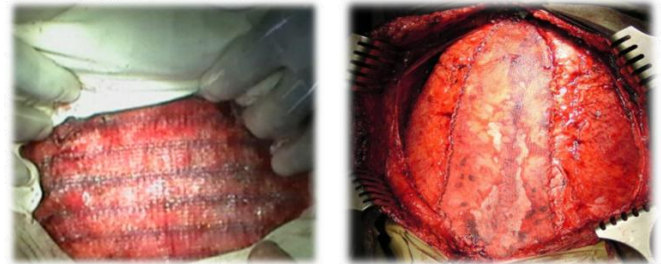

Figure 2, 3. Fixation of the mesh over the aponeurosis. The final appearance

When the enlargement of the abdominal cavity was necessary, to prevent the development of ACS, tension free hernia repair was performed, i.e. mesh was set up over the aponeurosis without suturing, as well as in a combined way - with the additional mobilization of the abdominal rectus muscles sheaths by Ramirez. (Fig. 4.).

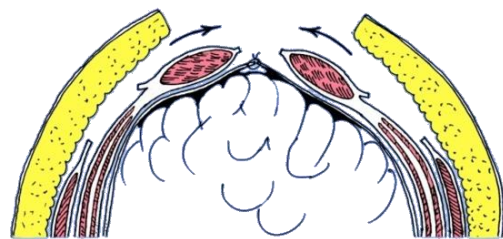


Figure 4. Reconstruction of the anterior abdominal wall with the rectus muscles mobilization by Ramirez

In the study group the skin incision was done over the hernia. Then the subcutaneous fat was widely separated until the fascia around the hernial sac. Hernial sac was removed further. Hernial ring suture and elimination of rectus muscles diastasis were performed. The mesh was used in all the patients in the study group. To prevent the "small stomach" syndrome and respiratory failure tension free hernia repair by the indications without suturing the fascia, or reconstruction of the abdominal wall by Ramirez were done. After hernia repair has been finished dermolipectomy was performed by the line previously applied on the anterior abdominal wall, which borders the hernial bulge, old postoperative scar and skin-fat fold. Weight of the excess skin and fat flap ranged from 4 to 12 kg. After that in all the patients of the control and study groups drainage tube was left over the aponeurosis, the free ends of which were set up below the horizontal section, fixed to the skin and drained by

Redon (Fig. 5).

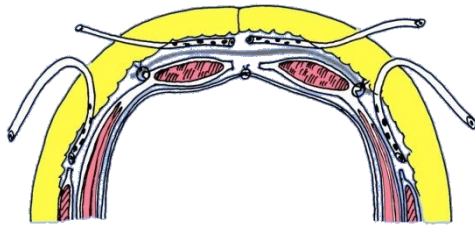


Figure 5. The mesh fixation and drainage

In the control group (n = 96) after hernia repair and fixation of the mesh in 81.4% of patients drainages were set up with further active aspiration, after which the wound was sutured by layers. In the study group (n = 122) it was important to fix the mesh to the aponeurotic structures tightly, since the presence of folds and areas of folded mesh form space over the aponeurosis where fluid can accumulate. In addition, in the study group, to prevent wound complications subcutaneous fat suture and fixation to the mesh and wound bottom were applied.

To eliminate the periprosthetic space the vertical U-shaped seams were done with wide sews of subcutaneous fat and tight attachments to the mesh and wound bottom. Subcutaneous fat was sewn over 4-5 cm from the both wound edges, the distance between the vertical U-shaped sutures was 2-3 cm.

4. Results of the Study

To evaluate the effectiveness of the treatment results in patients in the study group as the study criteria, the following comparison options were used:

- abdominal complications in the early postoperative period;
- extra-abdominal complications in the early postoperative period;
- wound complications in the early postoperative period;
- long-term results of the surgical treatment.

Monitoring of the intra-abdominal pressure was done in all patients during the management. We revealed regular increase of the abdominal pressure during the surgery, associated with reduction of hernia contents and hernia repair. Tension-free hernia repair and combined method with the mobilization of the rectus muscles sheaths by Ramirez was performed in 10 patients of the control group and in 58 patients of the study group which was useful to enlarge the abdominal cavity, and therefore to avoid increased intra-abdominal pressure.

The vast majority of the patients after surgery remained normal gastrointestinal function, only 3 patients from the control and 1 patient from the study group developed intestinal paresis after hernia repair of the giant ventral herni, which was managed by prescribing appropriate medications. Urinary retention was observed in 4 patients of the control

group and 2 patients of the study group. In the control group bronchopulmonary complications were observed in 6 patients, events of heart failure in 5 patients with low blood pressure, increased heart rate, shortness of breath. In the study group extraperitoneal complications were observed in 3 patients: bronchopulmonary complications in 2 patients, heart failure in 1 patient who had post-infarction cardiosclerosis. Wound postoperative complications were observed in 12 patients in the control group and 3 patients in the study group. In the long-term period after surgery from 96 patients of the control group 65 (67.7%) and from 132 patients of the study group 109 (82.6%) were observed in a period from 1 to 7 years. Recurrences were observed in 3 (4.6%) patients in the control group after the tension hernia repair. None of patients in the study group had experienced recurrences. In dynamic observation body weight has not changed significantly of the control group patients. But sustained significant changes were observed in the patients of the study group indicigt of abdominal obesity. These had a positive impact on the future prospects of life, because the type of abdominal fat distribution is mostly associated with high risk of cardiovascular diseases and type 2 diabetes mellitus. Monitoring of the blood glucose levels showed that the control group patients had no significant changes. Whereas patients of the study had significant decrease in blood glucose level after the treatment. In patients of the study group there were no increase of blood glucose level more than 6.1 mmol/L. Overall 138 (60.5%) patients had high blood pressure (BP) in pre-operative period. Monitoring of BP in the late postoperative period indicate patients of the control group maintained high blood pressure, with a tendency to get more severe. Conversely, patients of the study group had decreased blood pressure with a tendency to change to milder degrees of hypertension. Analysis of the research results, which evaluated the quality of patients' lives in the study group 3 months later after surgery showed improvement in all aspects of the investigation.

5. Conclusions

The particularity of clinical presentation in patients with ventral hernias and morbid obesity stage III-IV with comorbidities require special preoperative preparation to prevent early postoperative complications. The optimal method of hernia repair in patients with morbid obesity stage III - IV is combination of abdominoplasty with mobilization of rectus abdominal muscles sheaths by Ramirez. Reliability of hernial ring closure is provided by polypropylene mesh. Mobilization of rectus muscle ensures normal values of IAP. As a result of abdominoplasty it is possible to reduce the incidence of complications in the short term and late postoperative period. Comparing to control group in study group wound complications decreased from 29% to 9%, cardio-vascular system complications – from 96 (72.7%) to 58 (43.9%). Cases of recurrence and death were not observed. The proposed method to prevent wound complications after

hernia mesh repair based on wide sewing and fixing the subcutaneous fat grafts to the mesh and the bottom of the wound using the vertical U-shaped seams significantly reduced the incidence IH from 16.7% to 3.3%. Tension-free hernia repair combined with dermolipsectomy improves all aspects of the quality of life in the patients. The aesthetic component of the surgery contributes to the emergence of motivation for weight loss.

REFERENCES

- [1] Azamat S., Zafarjon K., Salim D. Criteria's of choice method in surgical treatment of patients ventral hernia with concomitant obesity //European science review. – 2016. – №. 3-4.
- [2] Blatnik J.A., Prabhu A.S. Management of Ventral Hernia in the Morbidly Obese Patient //Hernia Surgery. – Springer International Publishing, 2016. – C. 393-399.
- [3] Kukosh M.V., Vlasov A.V., Morozov G.I. Prevention of early postoperative complications of arthroplasty ventral hernias //Novosti xirurgii. – 2012. – T. 20. – №. 5. – C. 32-37.
- [4] Chevrel J.P., Rath A.M. Classification of incisional hernias of the abdominal wall. *Hernia* 2000; 4(2): 94, <http://dx.doi.org/10.1007/bf02353754>.
- [5] Patel P.V., Merchant A.M. Ventral hernia repair in the morbidly obese patient: A review of medical and surgical approaches in the literature //Bariatric Surgical Practice and Patient Care. – 2014. – T. 9. – №. 2. – C. 61-65.