

# Case Report: Testicular Seminoma in Sudanese Patient

Anilkumar Mitani<sup>1</sup>, Mohamed A. Hameed<sup>2</sup>, Gamal O. Elhassan<sup>3,4</sup>, Khalid O. Alfarouk<sup>5</sup>,  
Abdel Khalig Muddathir<sup>6</sup>, Adil H. H. Bashir<sup>6,\*</sup>

<sup>1</sup>University of Bahri, Bahri, Sudan

<sup>2</sup>Omdurman Islamic University, Omdurman, Sudan

<sup>3</sup>School of Pharmacy, Uneiazah University, AL-Qassim, KSA

<sup>4</sup>Faculty of Pharmacy, Omdurman Islamic University, Omdurman, Sudan

<sup>5</sup>Alfarouk Biomedical Research, LLC, Tampa, Florida, USA

<sup>6</sup>University of Khartoum, Khartoum, Sudan

**Abstract** A male, 22 years old young man presented with left testicular mass and pain along left leg and lower back for one year; the mass is totally excised and sends to histopathology to be confirmed as Seminoma.

**Keywords** Testicular Seminoma, Sudan

## 1. Case Report

A male patient, laborer, 22 years old, single, resident in Al-Gezira, South of Khartoum. The patient was complaining of painfully hard swelling at left testicle one year ago, no increase in testicle size at the first three months, then gradually increased to reach a grapefruit size in almost eight months. Patient's general condition was good within two years before a sense of hotness in the left testicle on and off. No loss of weight or appetite, as no fever or night sweating. The condition started with sudden onset and progressive course, where received treatment in the form of tablets and capsules with no response. Patient has been admitted to hospital for enteric fever at childhood.

**Family history:** Parents are first-degree relatives, as no similar condition in the family.

**On examination:** Patient has normal facial features and good general condition.

Lesions are **skin colored** and **Firm** on palpation.

**Palms & soles:** not detected.

**Nails:** No nail dystrophy.

**Hair:** No Abnormality Detected.

**Eye:** No abnormality is seen.

**Oral mucosa & Lips:** No abnormality is seen.

**Genital Examination:** Left testicle is large in size about 12X8 cm, freely mobile, slightly tender, smooth surface with palpable 2 nodules, testicle is hard in consistency, spermatic cord couldn't be palpated, and noregional inguinal lymph nodes are palpable, as Para aortic lymph nodes. Scrotal skin shows an ulcer 3X4 cm punched out, indurated, with necrotic

floor, penis and pubic hair look normal on examination. Right testicle shows no abnormality. No palpable regional or Para aortic lymph nodes.

## 2. Investigations Did

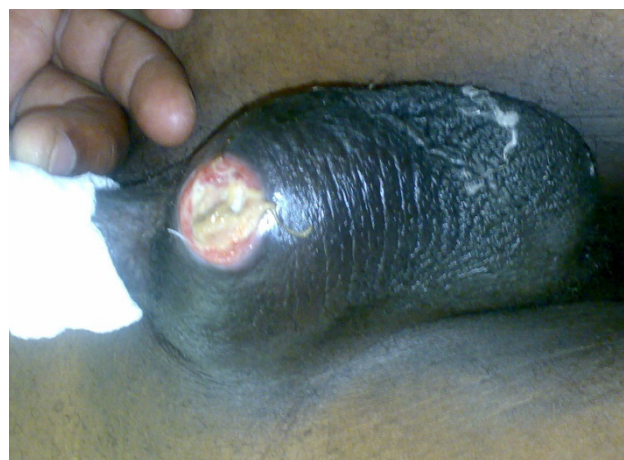Ultra sonography of both testicles:

Gross multiple ectopic left testicular mass with left spermatocele.

Right testicular size and pattern looks normal.

Histopathology: Gross: Hard growth, 13X8 in size, regular, smooth, with ill-defined spermatic cord structure.

## 3. Discussion



**Figure 1.** Scrotal swelling and necrotic ulcer

Testicular seminoma is a pathologic diagnosis in which only seminomatous elements are observed in histopathologic review after a radical orchiectomy and in which serum

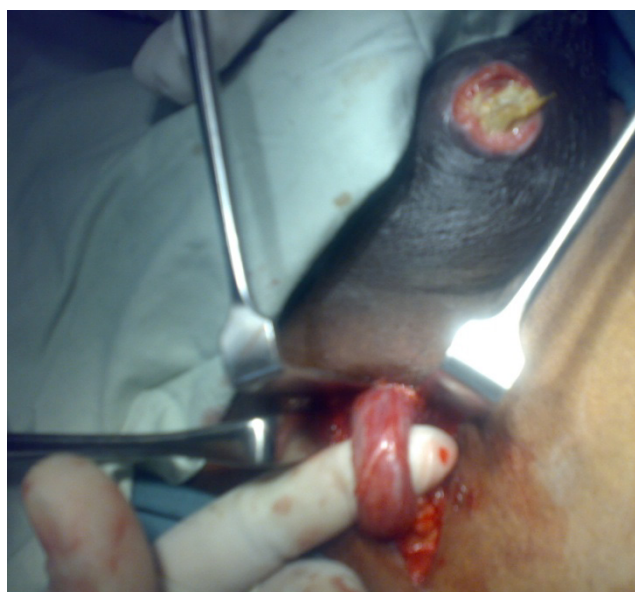\* Corresponding author:

derma55@yahoo.com (Adil H. H. Bashir)

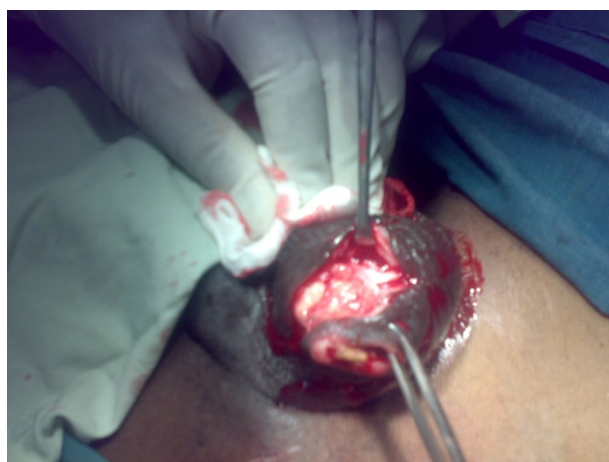Published online at <http://journal.sapub.org/ajdv>

Copyright © 2015 Scientific & Academic Publishing. All Rights Reserved

alpha-fetoprotein (AFP) is within the reference range (Figures 1-6). Seminomas account for one-third of testicular germ cell tumors (GCTs), which are the most common malignancy in men aged 15-35 years [1]. The risk of testis cancer is 10-40 times higher in patients with a history of cryptorchidism; 10% of patients with GCTs have a history of cryptorchidism. Treatment usually requires removal of one testis, but this does not affect fertility or another sexual functioning.



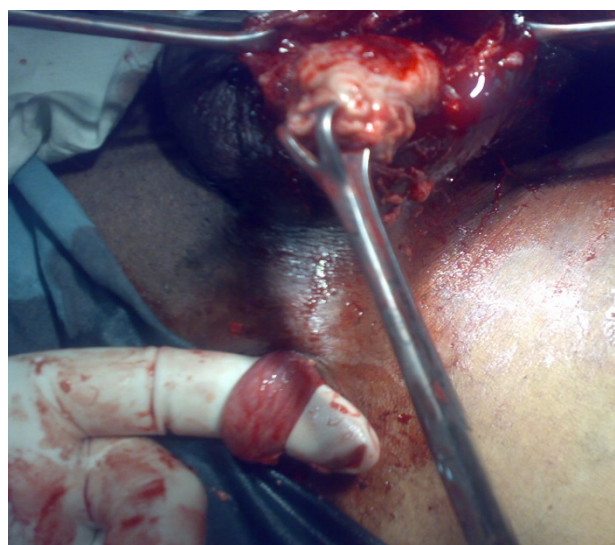
**Figure 2.** Spermatic cord of the swollen testes



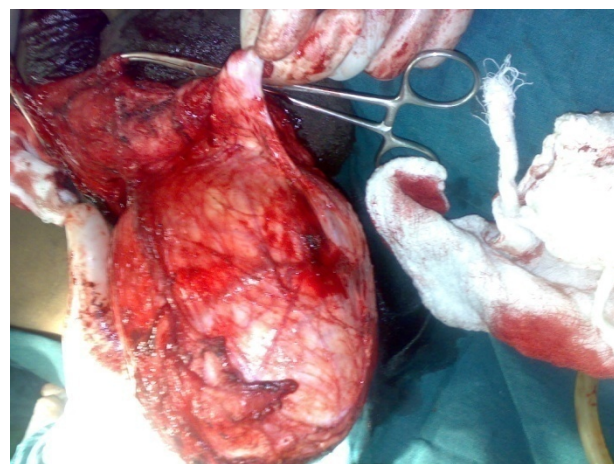
**Figure 3.** Excision of the scrotal ulcer prior to removal of the testicular tumor

The typical presentation in testicular seminoma is a male aged 15-35 years presents with a painless testicular lump that has been noticeable for several days to months, the patients commonly have abnormal findings on semen analysis at presentation, and they may be subfertile [2] and sometimes presented with hydrocele, and scrotal ultrasonography may identify a nonpalpable testis tumor. Some cases of seminoma can present as a primary tumor outside the testis, most commonly in the mediastinum [3]. The preferred treatment for most forms of stage 1 seminoma is active surveillance.

Stage 1 seminoma is characterized by the absence of clinical evidence of metastasis. Active surveillance consists of periodic history and physical examinations, tumor marker analysis, and radiographic imaging. Around 85-95% of these cases will require no further treatment. Modern radiotherapy techniques, as well as one or two cycles single-agent carboplatin, have been shown to reduce the risk of relapse, but carry the potential of causing delayed side-effects. Regardless of treatment strategy, stage 1 seminoma has nearly a 100% cure rate [4]. Stage 2 seminoma is indicated by the presence of retroperitoneal metastasis. Cases require radiotherapy or, in advanced cases, combination chemotherapy. Large residual masses found after chemotherapy may require surgical resection. Second-line treatment is the same as for nonseminomas [5].



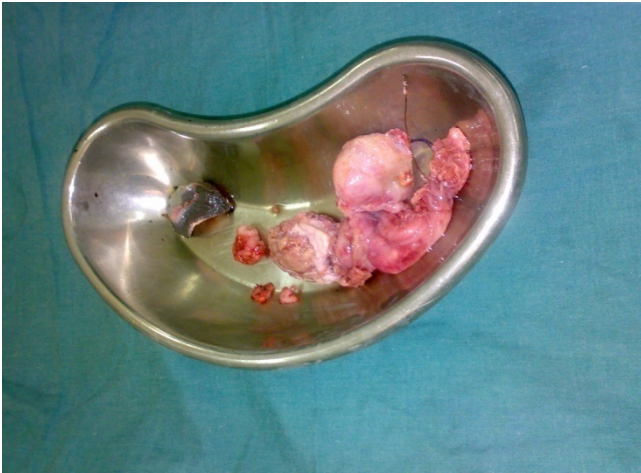**Figure 4a.** Removal of the testicular tumor



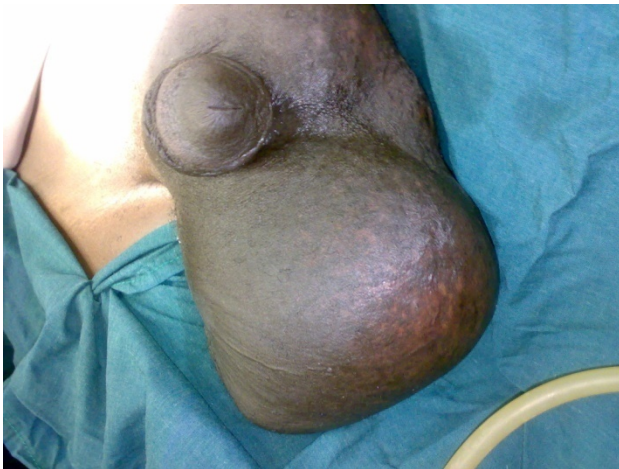**Figure 4b.** Removal of the testicular tumor

Stage 3 seminoma is characterized by the presence of metastasis outside the retroperitoneum—the lungs in "good risk" cases or elsewhere in "intermediate risk" cases. This is treated with combination chemotherapy. Second line treatment follows nonseminoma protocols [5].





**Figure 5.** the testicular tumor is totally removed



**Figure 6.** The case after the operation

## REFERENCES

- [1] Jemal A, Siegel R, Ward E, Hao Y, Xu J, Murray T, Thun MJ: Cancer statistics, 2008. *CA Cancer J Clin* , 58:71–96.
- [2] Panidis D, Rousso D, Stergiopoulos K, Papathanasiou K, Delkos D, Papaletsos M: The effect of testicular seminoma in semen quality. *Eur J Obstet Gynecol Reprod Biol* 1999, 83:219–22.
- [3] Weidner N: Germ-cell tumors of the mediastinum. *Semin Diagn Pathol* 1999, 16:42–50.
- [4] Nichols CR, Roth B, Albers P, Einhorn LH, Foster R, Daneshmand S, Jewett M, Warde P, Sweeney CJ, Beard C, Powles T, Tyldesley S, So A, Porter C, Olgac S, Fizazi K, Hayes-Lattin B, Grimsen P, Toner G, Cathomas R, Bokemeyer C, Kollmannsberger C: Active surveillance is the preferred approach to clinical stage I testicular cancer. *J Clin Oncol* 2013, 31:3490–3.
- [5] Updates to NCCN Guidelines for Testicular Cancer and NCCN Compendium Chapters for Testicular Cancer and Kidney Cancer [[http://www.nccn.org/network/business\\_insights/flash\\_updates/flash\\_update\\_information.asp?FlashID=20](http://www.nccn.org/network/business_insights/flash_updates/flash_update_information.asp?FlashID=20)].