

Case Report: Scabies Skin Infection in an Eleven Years Old Girl

Devinia Nevidya Rayappan

Faculty of Medicine, Universitas Udayana, Bali, Indonesia

Abstract Scabies is known to be a highly contagious skin infection caused by *Sarcoptes scabiei var. hominis* which burrow into the skin. Scabies is one of the three most common skin diseases that always affect children besides pyoderma and tinea. In addition, scabies are more often seen in crowded district with low standard of living and unhygienic condition. Scabies can spread through direct or indirect skin contact. We presented a 11 year old girl with chief complaint of intense body itchiness between the fingers, wrist, palm, armpit, back and chest. The general examination was within normal limits with optimal vital measures. On dermatological examination, found erythematous papules, round shaped with a well defined border, discrete presentation and distributed bilaterally. Microscopic examination was not done as 3 over 4 cardinal signs were found in this patient to establish the diagnosis. The patient was prescribed with Scabimite lotion to apply once a day and Interhistin tablets two times a day. For non- pharmacological treatment, patient was advised to take care of her personal and surrounding hygiene. Her family members were also advised to undergo the same medication as a preventive measure. The prognosis was good.

Keywords Scabies, Erythematous, Cardinal sign

1. Introduction

Scabies is a type of skin disease which are caused by an infestation and sensitization by *Sarcoptes scabiei var. hominis* and its product [1, 2]. There are many factors which are contributing to this type of skin disease such as poor hygiene, poverty, and sexual contact and wrong diagnosis. The main route of transmission of this disease is by direct skin to skin contact. Take handshakes and sleeping side by side for an example [2]. Scabies also can be transmitted by indirect contact such as sharing of personal belongings. Scabies is usually spread by female *Sarcoptes scabiei mites* who reproduces and form the larvae. The life circle of this mite from an egg evolving into adult mite takes approximately 8-12 days [2].

There are four cardinal signs which can found in scabies skin disease and can be used for diagnosis manifestation of scabies. The diagnosis can be made when two over four cardinal signs are found [3]. The cardinal signs are nocturnal pruritus, scabies attacks groups of people, appearance of visible tunnel in whitish to greyish colour and the gold standard diagnostic will be finding mites in the skin through microscopic examination [3, 4].

Besides, most physicians often overlooked this skin

disease to be any pruritic dermatoses. Therefore, a proper history taking and an effective clinical examination should be assessed to diagnose this clinical condition comprehensively to endure patients do not self medicate themselves that could lead to other serious medical complications in unattended or chronic use [8].

Moreover, patients should be emphasized that even with the right and proper treatment, scabies is a relapsing disorder. Even though scabies might not be a life treating disease, it's always a stigma in society as it is often associated with one's personal and surrounding hygiene practice [4]. A late diagnosis or missed diagnosis may eventually increase the severity of secondary infection which may lead other severe complications. This may also directly or indirectly affect their daily activities [2, 5]. In conclusion, patient should be educated comprehensively about the disease itself, plan of therapy and prognosis for a better outcome.

2. Case Report

A girl aged 11 years old from Mengwi came with her mother to Sanglah General Hospital Denpasar on 18 June 2013 at 9.45 am with the chief complaint of discomfort of full body itchiness since two weeks ago. According to her mother, this itchiness started from her fingers first which widespread in more numbers and different sizes to her wrist, armpits and back within the time frame of one week. She also complained of itchiness in her lower extremities, which mainly appeared in between her toes and knees. The girl

* Corresponding author:

pvincez_21@hotmail.com (Devinia Nevidya Rayappan)

Published online at <http://journal.sapub.org/ajdv>

Copyright © 2014 Scientific & Academic Publishing. All Rights Reserved

experienced such for the first time and had never consulted to a doctor before assuming it would disappear by itself.

Furthermore, she said that the itchiness worsens at night and her sleep was ruined by intense pruritus for the past two weeks. In these two weeks, the complaint did not reduce or subside. It intensified until her daily routine was affected. History of pyrexia was denied. Her mother applied a traditional cream to the affected area but the symptoms did not show any improvement.

According to the girl, currently both her brothers are experiencing the same complaint. Apparently, she has a history of sharing the same room and bed with both her brothers.

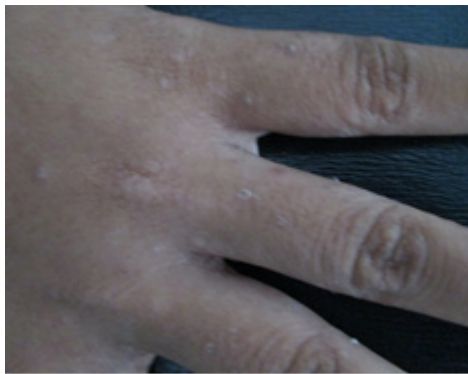


Figure 1. Papules located at patient's finger webs

On physical examination the girl appeared to be compositus with Glasgow Coma Scale of E4V5M6. Her vital signs appeared to be normal with blood pressure 110/70 mmHg, respiratory rate of 18 times per minute, pulse rate of 72 times per minute, and axillary temperature of 36.3 degree Celcius. The girl appeared well nourished with a body mass index of 20.0.

In further general examination, the girl appeared normocephaly with no anaemia or icterus sign of the eyes. Ear, nose and throat examinations were within normal limits, abnormal secretions, growth of hyperaemia were absent. There were no palpable lymph nodes at the neck region. Both the thoracic and abdominal examination was within normal limits. There were no signs of deformities, oedema or atrophy of the muscles of both upper and lower extremities. The extremities appear warm with normal limits of motor and sensory function.

According to the dermatological findings, the itchiness was limited bilaterally between the fingers, wrist, palm, armpit, back and chest. The efflorescence was multiple erythematous papules, round shaped with well defined borders, discrete presentation measuring from 0.1 to 0.2 cm in diameter, with no scales. The papules also appear in multiple spherical vesicles with a size range measuring from 0.3 to 0.5 cm in diameter with erosion that has already healed and crusted. There were also few serpiginous papules that appears whitish to greyish colour and has a threadlike elevated line on her right hand.

From history taking and physical findings three differential diagnosis were raised named scabies, pediculosis

corporis and prurigo. The diagnosis of scabies is however based primarily on clinical examination. From the physical examination, there were no fine scales found at the skin lesions or hyper pigmentation of the skin.

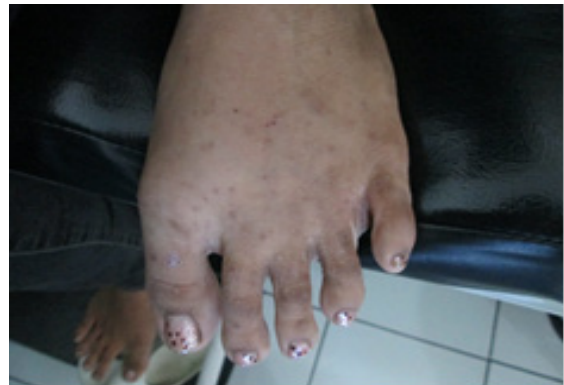

Figure 2. Papules and vesicles located at patient's foot

In conclusion, pediculosis corporis and prurigo can be excluded from the diagnosis. There were no indications of blood examinations as this patient denies any other complaints and she appears in a condition of good health and nutrition.

Based on the anamnesis and clinical examination, we assessed the patient with scabies. The management of the girl was listed as non-pharmacological and pharmacological therapy. Firstly, the girl was advised to take care of her personal and surrounding hygiene. Her family members were also advised to undergo the same medication as a preventive measure. In addition, the patient was educated by the dermatologist and given full information about the patient's disease and the mode of treatment planned out. For the pharmacological treatment, patient is given both topical and systemic medication. The topical medication was Scabimite cream 30 gram to be applied on her whole body. In addition to that, she was also given Interhistin tablet which she should consume half a tablet three times a day. The patient's prognosis was hoped to be excellent with a good patient compliance by routinely following the treatment.

3. Discussion

Scabies is a highly contagious skin infestation caused by the mite *Sarcoptes scabiei var hominis*, which is said to eventually burrow between two layers of the skin, known as the spinous and corneal layer, feed on intercellular fluid, they shelter well under the horny material [1, 3]. Scabies is a skin disease that equally infect all age group and races [1]. In that case, this patient's age and race doesn't play a significant role in getting infected by the mite. In general, scabies patient always come with the main complaint of intense body itchiness [1, 3]. Predilections for scabies are such as skin folds as the mite likes warm places like fingers, wrist, elbow, armpit, back, abdomen, genital parts, knee and toes [2].

Patient came with chief complaint of discomfort of full body itchiness since two weeks ago. According to her mother,

this itchiness started from her fingers first which widespread in more numbers and different sizes to her wrist, armpits and back within the time frame of one week. She also complained of itchiness in her lower extremities, which mainly appeared in between her toes and knees. Supporting this fact above, in our case, the location of itchiness that the patient complained correlates highly with the predilection for scabies.

Furthermore, the lesions of scabies are very minuscule so it's difficult to identify them unless sensitization occurs, a period of 2-6 weeks following the onset of the initial infestation. Symptoms appear in 1-4 days in persons who are reinvested [2, 3]. For this case, the patient's itchiness started two weeks ago, that means she would have been infected in about two to six weeks before her sensitization took place since this is the first time she is having this complaint. If only she would have been re-infested the symptom would have appeared earlier.

Hallmark in the skin disorders are the skin lesions also known as efflorescence. However, there are some skin diseases that may share some common efflorescence, hence mimicking each other giving a raise to various differential diagnoses. Therefore a comprehensive and systematic evaluation is the golden rule in assessing a patient right. Careful clinical evaluation is done on the patient in ruling out the differential diagnosis for clinical importance. For instance, the chief complaint of pruritus and predilections such as the fingers, wrist, elbow, armpit, back and toes as in the case above suggested several differential diagnosis such as scabies, pediculosis corporis and prurigo. Therefore, an adequate clinical knowledge and experience are essential in differentiating these skin diseases [1, 8].

Even though pruritus is present in both pediculosis corporis and prurigo, however pruritus in both these diseases will eventually cause intensified scratching and leaving skin to be scaly and hyperpigmented. From the physical examination, there were no fine scales found at the skin lesions or hyperpigmentation of the skin. Efflorescence of prurigo is multiple, colourless, dome shaped papules and easily palpable than seen. And pediculosis corporis only has efflorescence of scars due to scratching, because pruritus only then decreases with intense scratching. Another symptom that is more likely to occur in both these differential diagnosis is the enlargement of the regional lymph nodes, with or without secondary infection [1]. In contrast to this theory, the girl in this case has never experienced such symptoms as evident from the anamnesis and clinical physical examination.

There are four cardinal signs to diagnose scabies; the diagnosis can be made as long as the patient met two over four of the cardinal signs. This patient was diagnosed with scabies skin infection based on the anamnesis and dermatology examinations. Typical nocturnal exacerbation is one of the main symptoms [3, 4]. The patient admitted that she observed that the itchiness got worse at night compared to day time and her sleep was ruined by intense pruritus for the past two weeks. In these two weeks, the complaint did

not reduce even after applying the traditional cream that was given by her mother whereas it was getting worse until her daily routine were affected. Besides that, attacking a group of people is also one of the cardinal sign of scabies skin infection [4]. In this patient, not only she has the complaint of itchiness but her siblings also have same complain as hers.

Mode of transmission of scabies is either by direct skin contact or indirect from sharing personal items of infected person to a healthy person. Direct contact meant by skin to skin contact such as shaking hands, sexual contact and even hugging the infected person [4]. And indirect contacts are like sharing personal thing with the infected once. For instances, sharing cloths, towels and any stuff that have skin contact with the infected person can spread scabies [3, 4]. The transmission of scabies is possible if an infected person does not get a treatment immediately or up to 24 hours after one has been treated. Moreover, without contact to the skin, the mites would not be able to live more than three to four days [3, 4]. In this case, the mode of transmission of scabies remains unclear because she and her brothers were having the same complaint at the same time. Therefore, there were higher possibilities for them to get infected by scabies outside of the house, which could have been in school or the neighbourhood [4, 5]. After one of them got infected, they would have transmitted to the rest as they share personal belongings among their siblings and all three of them sleep in the same room, sharing one bed. Moreover, the third cardinal sign is there will be one serpiginous, whitish to greyish, threadlike elevated line on the skin surface which is known as the tunnel that was burrowed by the mite beneath skin and this can be found in physical dermatology examinations [4]. As the patient was thoroughly examined, the threadlike elevated line was found about two centimetres in length on her right hand. In this patient, since she has three over four of the cardinal signs she was diagnosed with scabies skin infection without doubtful. The fourth cardinal sign is said to be the gold standard laboratory examination to diagnose scabies skin infection. [4].

Scabies could also be confirmed by identifying the mite or mite eggs [3, 4]. This can be done by using the tip of a needle by removing the mite carefully from the end of its burrow or by examining under a microscope for mites, eggs, or mite faecal matter from a skin scraping obtained [3, 4]. However, this method may cause pain, physical or psychological discomfort and even results in bleeding hence its rarely performed if the diagnosis can be made by rest three clear cardinal sign [3, 4]. In this case, attempt to prove fourth cardinal sign wasn't performed because the three cardinal signs earlier were clear and sufficient to diagnose scabies in this patient.

The treatment for scabies comprises of two group of medication, which are topical and systemic medication [4, 5]. Scabimite cream contains permethrin 5% and its recommended as the first choice of topical treatment for scabies because it has less toxic compared to Gameksan but the effect of the medication is same [4, 5]. The method to

apply this cream is thoroughly massage the Scabimite cream into the skin from the head to soles of the feet, paying particular attention to the area between the fingers and toes, wrists, axillae, external genitalia and buttocks [6]. Then remove the cream after 8 to 10 hours [5, 6]. And it is not necessary to apply a thick visible layer of cream into the skin. Permethrin works in a way by destroying polarisation of nerve cell walls of the parasite by tying it with sodium. This will prolong repolarisation of cell wall and lead to paralyse of parasite. Permethrin gets metabolised quickly on skin and the non-reactive product of metabolism will be secreted out through urine [5, 6]. In addition, it is contraindicated on babies below two months old and also on a person with known hypersensitivity on any of their components [6]. Besides that, gamma benzene hexa chloride 1% lotion is also one of the medications used for scabies. This medication is known to be effective to all stages of scabies, one time application is sufficient in 95% and rarely creates irritation on skin but is contraindicated on children below 6 years old and pregnant mothers because its hazardous to our central nervous system [5, 6]. Benzyl Benzoate is also one of the treatments for scabies. It's effective in all stages of scabies but it's hard to obtain this lotion and at times it increases the intensities of pruritus.

Another medication for scabies is sulphur cream, this cream is not effective in egg stage of the mite. Therefore, it has to be used more than three days and it also leaves a very bad odour on clothes [5, 6]. In this case, the patient was prescribed with Scabimite lotion because it has the highest effectiveness. Besides that, it is safe to use and also it has the least side effects compare to the other medication. The patient was told to apply the lotion on her whole body and leave it on for about 8 to 10 hours before washing it off. Preferably, the lotion is applied at night before going to bed and should be washed off once she gets up in the morning, so in this way it will be convenient and left for long hours. The patient was also prescribed Interhistin $\frac{1}{2}$ tablet, 3 times a day for her intense itchiness. By giving antihistamine to the patient, it reduces itchiness and stops patient from scratching the lesion and causing secondary infection.

However, it's not sufficient to treat the infected person alone whereas the treatment must often involve the entire household and community to prevent reinfection [3, 5]. Besides that, the mite also must be totally eradicated from the infected person and importantly from their environment as well to ensure they free from scabies for definite [3, 5]. For this patient, she was told to bring along her brothers to get treated because if they were not treated she might get re-infected. Besides that, she was prohibited to go school or share her personal belonging with others so she doesn't transmit the disease to others. On top of that, her mother was advised to clean the whole house before starting on the treatment. For instance, bedding and clothing worn should be laundered and left under the sun for a few hours in order to eradicate the mite. Her mother was also told to keep an eye of her daughter's personal and environmental hygiene.

Secondary infection is a common complication of scabies

besides crusted scabies on immune compromised person [7], but for this patient there is no sign of secondary infection or other complication yet as she had a prompt treatment.

Scabies is type of skin disease that can be completely cured if the medication is taken as prescribed and if one takes care of personal and environmental hygiene [7]. The prognosis of the patient is expected to be excellent provided with a good patient's compliance [8].

4. Conclusions

A case study of a 11 years old girl with scabies marked by multiple erythematous papules with well defined borders was reported. The assessment was made by anamnesis and physical examination based on the four cardinal signs. The patient was prescribed with Permethrin 5% lotion to apply her whole body and also Interhistin tablet for her itchiness.

In addition, the patient was also advised to take care of her personal hygiene and asked to bring both her brothers for treatment as well, to break the chain of transmission from one to another. The prognosis of the patient is expected to be excellent with a good patient compliance.

ACKNOWLEDGEMENTS

First of all, I would like to show my gratitude to the Almighty Lord because with his blessings I have managed to complete my case report entitled " Scabies Skin Infection In An Eleven Years Old Girl".

With pleasure, I, **Devinia Nevidya Rayappan**, would like to convey my heartiest thank you to **Dr. Luh Made Mas Rusyati, SpKK**, the supervisor for my paper work whose encouragement, guidance, and support from the beginning to the final level has enabled me to develop an understanding of the topic and hence successfully completing my case report.

REFERENCES

- [1] Djuanda Adhi, 2002. *Ilmu Penyakit Kulit Dan Kelamin Ed. 3*. Retrieved January 10, 2014 from Fakultas Kedokteran Universitas Indonesia. Jakarta.
- [2] Bag./SMF Ilmu Kesehatan Kulit dan Kelamin. 2007. *Atlas Penyakit Kulit Dan Kelamin*. Retrieved January 10, 2014 from FK. Unair/RSU Dr. Soetomo. Surabaya.
- [3] Brouhard Rod, 2008. *Scabies: Symptoms and Treatment of Scabies*. Retrieved January 9, 2014 from http://firstaid.about.com/od/rash/qt/08_skabies.htm.
- [4] Springhouse., 2003. *Handbook of Diseases*. Retrieved January 10, 2014 from <http://www.wrongdiagnosis.com/s/scabies/book-diseases-12a.htm>.
- [5] Hunter J., Savin J., Dahl M., Merk, H.F., 2002. *Clinical Dermatology Third Edition* Retrieved January 10, 2014 from Blackwell Science.
- [6] Department of Medical Entomology. *Scabies*. Retrieved

January 12, 2014 from <http://www.medent.usyd.edu.au/fact/skabies.html>.

- [7] Mayo Clinic Staff. *Complications*. Retrieved January 12, 2014 from <http://www.mayoclinic.com/health/scabies/DS00451/dissection=complication>.

- [8] Halder RM, Taliaferro SJ. *Scabies*. In: Wolff K, Goldsmith LA, Kats SI, dkk, editors. *Fitzpatrick's. Dermatology in General Medicine*. 7th edition. Retrieved December 9, 2014 from New York: Mc Graw Hill Companies; 2008.